

troubleshooting poor image quality in sestamibi scintigraphy

Author: BenchChem Technical Support Team. **Date:** December 2025

Compound of Interest

Compound Name: *TECHNETIUM SESTAMIBI*

Cat. No.: *B1142544*

[Get Quote](#)

Technical Support Center: Sestamibi Scintigraphy

This technical support center provides troubleshooting guidance and answers to frequently asked questions for researchers, scientists, and drug development professionals working with Sestamibi scintigraphy. Our goal is to help you overcome common challenges and ensure the acquisition of high-quality, reliable data.

Frequently Asked Questions (FAQs)

Q1: What is the most common cause of artifacts in Sestamibi scintigraphy?

The most common sources of artifacts in Sestamibi scintigraphy are patient motion and soft tissue attenuation.^{[1][2][3]} Patient motion during image acquisition can lead to blurring and misregistration of the heart, potentially creating artificial defects.^{[1][3][4]} Soft tissue attenuation, caused by the absorption of photons by overlying tissues like the breast or diaphragm, can mimic perfusion defects in the anterior and inferior walls of the left ventricle, respectively.^{[3][5]}

Q2: How can I minimize extracardiac radiotracer uptake?

Extracardiac uptake, particularly in the liver and gastrointestinal tract, can interfere with the visualization of the inferior myocardial wall.^{[1][3]} To minimize this, consider the following:

- **Timing:** Allow sufficient time between radiotracer injection and imaging to permit clearance from the hepatobiliary system. For rest studies, a delay of 45-60 minutes is recommended.[3][6]
- **Fatty Meal:** In some protocols, administering a fatty meal after a rest injection can promote gallbladder contraction and clearance of the tracer from the liver.
- **Pharmacologic Stress Agents:** The choice of stress agent can influence the degree of extracardiac uptake.
- **Prone Imaging:** Acquiring images with the patient in the prone position can help to separate the heart from the liver and gut activity.[1][3]

Q3: What is "cardiac creep," and how can I avoid it?

"Cardiac creep" refers to the upward movement of the heart in the chest following strenuous exercise. If imaging is initiated too soon after stress, this motion can cause an artifactual defect, typically in the inferior wall. To avoid this, it is recommended to wait at least 15-30 minutes after the completion of exercise before starting image acquisition.[3] This allows the heart to return to its baseline position.

Q4: Can a patient's medical condition, other than coronary artery disease, affect the scan results?

Yes, certain conditions can cause perfusion defects that are not related to coronary artery disease. A common example is a left bundle branch block (LBBB), which can cause a reversible or fixed defect in the interventricular septum.[1][3][7] This is thought to be due to the abnormal pattern of ventricular contraction affecting myocardial blood flow. It is crucial to have the patient's clinical history, including an electrocardiogram (ECG), to aid in the correct interpretation of the images.

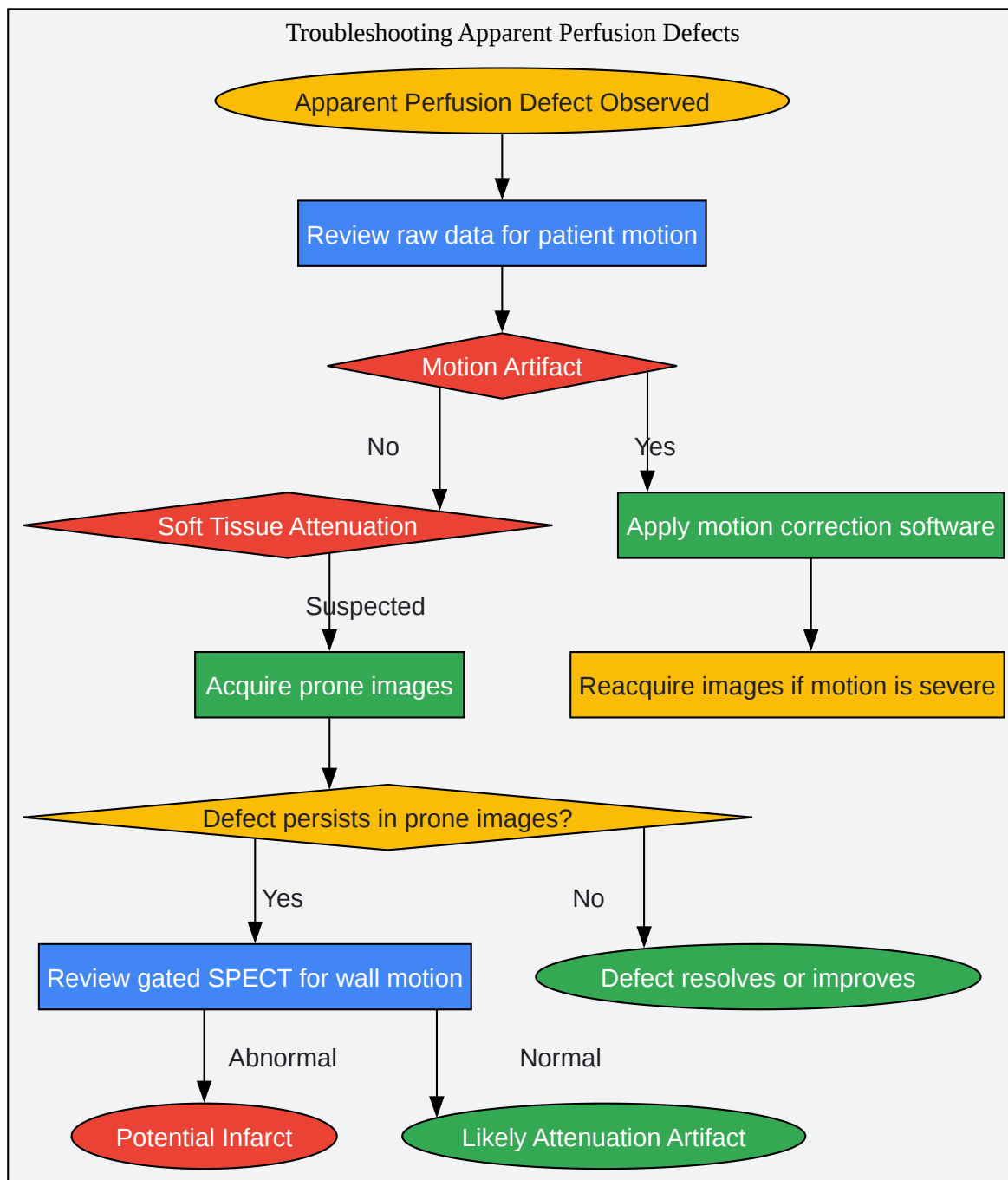
Troubleshooting Guides

This section provides a systematic approach to identifying and resolving common issues encountered during Sestamibi scintigraphy.

Issue 1: Apparent Perfusion Defect in the Anterior or Inferior Wall

An apparent reduction in radiotracer uptake in the anterior or inferior wall of the myocardium is a frequent finding. Use the following guide to determine the likely cause and appropriate corrective actions.

Troubleshooting Workflow: Apparent Perfusion Defects



[Click to download full resolution via product page](#)

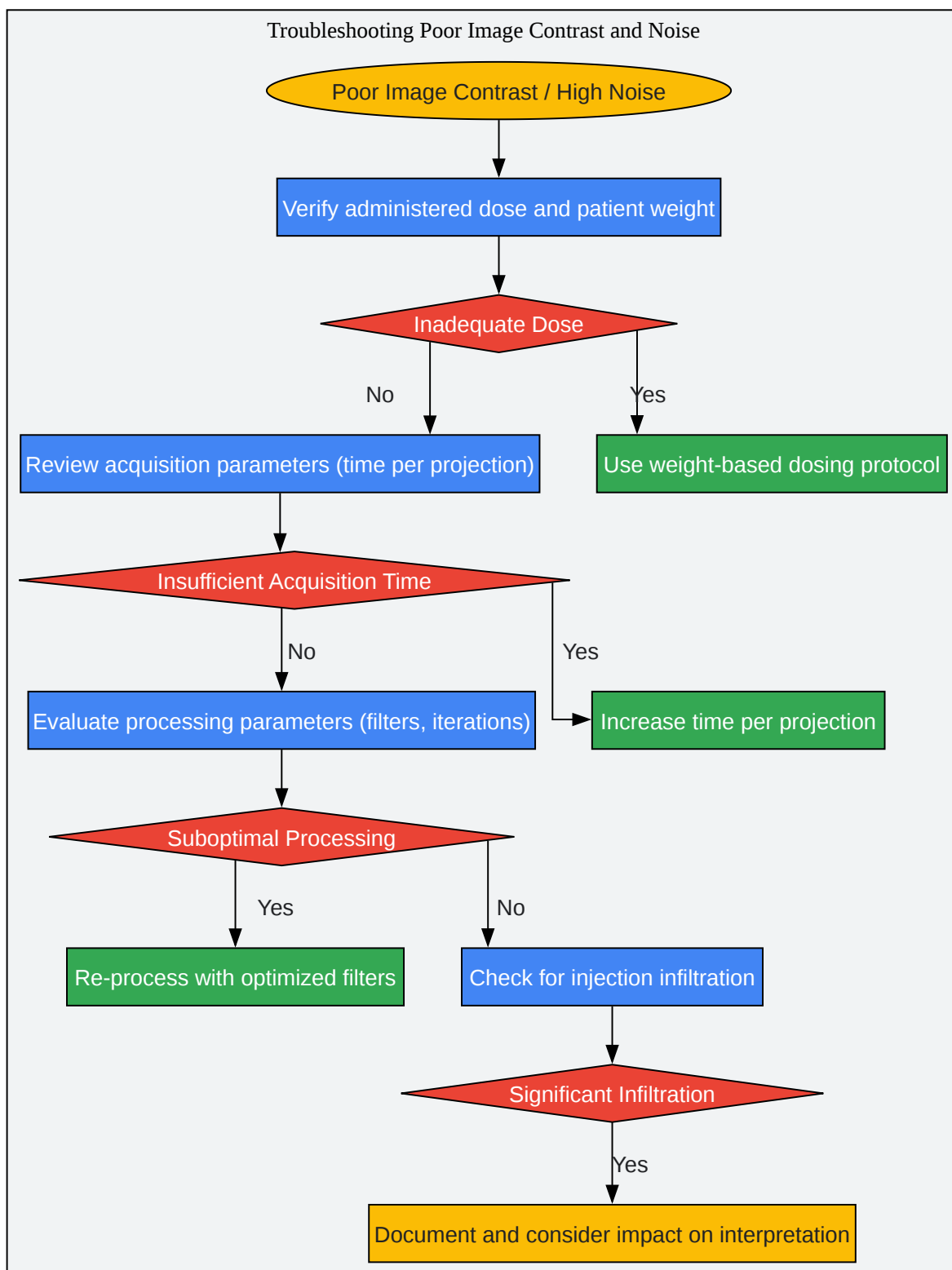
Caption: Troubleshooting workflow for apparent perfusion defects.

Potential Cause	How to Identify	Corrective Action
Patient Motion	Review raw cinematic data for heart displacement between frames.[1][3]	Apply motion correction software during processing. If motion is severe, re-acquisition may be necessary.
Breast Attenuation	Typically causes a fixed or reversible defect in the anterior wall in female patients.	Acquire images with the patient in the prone position.[1] Use attenuation correction if available.
Diaphragmatic Attenuation	Often presents as a fixed defect in the inferior wall, more common in male patients.[3]	Acquire images with the patient in the prone position.[3] [5] Use attenuation correction.
Myocardial Infarction	A fixed perfusion defect associated with abnormal wall motion (akinesis or dyskinesis) on gated SPECT.[1]	Correlate with clinical history and ECG findings. No corrective action for the image itself.

Issue 2: Poor Image Contrast and High Noise

Low contrast and high noise levels can obscure small perfusion defects and reduce the diagnostic quality of the study.

Troubleshooting Workflow: Poor Image Contrast and Noise



[Click to download full resolution via product page](#)

Caption: Troubleshooting workflow for poor image contrast and noise.

Potential Cause	How to Identify	Corrective Action
Inadequate Radiotracer Dose	Low total counts in the acquired images. Large body habitus can contribute to this. [3]	Implement a weight-based dosing regimen to ensure sufficient counts.[3]
Infiltrated Injection	Visualization of radiotracer at the injection site or in axillary lymph nodes.[3]	Document the infiltration. If significant, the study may need to be repeated.
Incorrect Acquisition Parameters	Short acquisition time per projection.	Increase the acquisition time per frame to improve photon statistics.
Suboptimal Processing	Inappropriate filter selection (e.g., a filter that excessively smooths the data).	Re-process the raw data using different filters. Iterative reconstruction methods can often improve image quality over filtered back-projection.

Experimental Protocols

Adherence to standardized protocols is critical for obtaining high-quality and reproducible results.

Protocol 1: One-Day Rest/Stress Sestamibi Scintigraphy

This protocol is commonly used for its convenience.

- Patient Preparation:
 - Patients should fast for at least 4 hours prior to the study.
 - Caffeinated beverages and medications should be withheld for 12-24 hours.
 - Certain cardiac medications (e.g., beta-blockers, calcium channel blockers) may be withheld as per institutional guidelines.[8]

- Rest Imaging:
 - Administer a low dose of 99mTc-Sestamibi (e.g., 400 MBq) intravenously.[8]
 - Wait 45-60 minutes to allow for radiotracer distribution and clearance from the liver.[6][8]
 - Acquire SPECT images.
- Stress Imaging:
 - Perform stress testing (either exercise or pharmacologic).
 - At peak stress, administer a high dose of 99mTc-Sestamibi (e.g., 1110 MBq) intravenously.[8]
 - If using exercise stress, continue for another 60-90 seconds post-injection.[8]
 - Wait 15-60 minutes post-injection (depending on the type of stress) before acquiring the second set of SPECT images.[6][8]

Quantitative Data Summary: Impact of Motion on Defect Creation

Patient motion is a significant source of artifacts. The extent of motion directly correlates with the likelihood and severity of the resulting artifact.

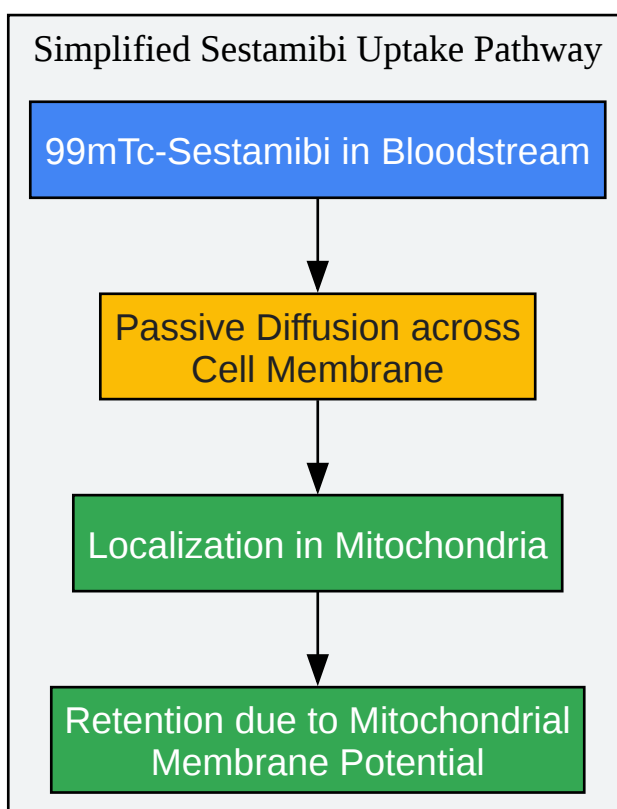
Extent of Motion (pixels)	Likelihood of Detectable Defect	Clinical Significance
0.5 (approx. 3.25 mm)	Undetectable	None
1.0 (approx. 6.5 mm)	Possible	Rarely clinically significant
≥ 2.0 (approx. 13 mm)	Always	Can mimic a true perfusion defect

Data adapted from studies evaluating Thallium-201 scans, with principles applicable to Sestamibi.[3]

Signaling Pathways and Workflows

Understanding the underlying mechanisms and logical flow of troubleshooting is essential.

Simplified Sestamibi Uptake and Retention Pathway



[Click to download full resolution via product page](#)

Caption: Simplified pathway of Sestamibi uptake and retention in myocardial cells.[1]

Need Custom Synthesis?

BenchChem offers custom synthesis for rare earth carbides and specific isotopic labeling.

Email: info@benchchem.com or [Request Quote Online](#).

References

- 1. med.emory.edu [med.emory.edu]

- 2. MPI-Artifacts | PDF [slideshare.net]
- 3. tech.snmjournals.org [tech.snmjournals.org]
- 4. researchgate.net [researchgate.net]
- 5. Optimal timing of SPECT/CT to demonstrate parathyroid adenomas in 99mTc-sestamibi scintigraphy | Hunter | Nuclear Medicine Review [journals.viamedica.pl]
- 6. jnm.snmjournals.org [jnm.snmjournals.org]
- 7. revistamedicinamilitara.ro [revistamedicinamilitara.ro]
- 8. radiopaedia.org [radiopaedia.org]
- To cite this document: BenchChem. [troubleshooting poor image quality in sestamibi scintigraphy]. BenchChem, [2025]. [Online PDF]. Available at: [https://www.benchchem.com/product/b1142544#troubleshooting-poor-image-quality-in-sestamibi-scintigraphy]

Disclaimer & Data Validity:

The information provided in this document is for Research Use Only (RUO) and is strictly not intended for diagnostic or therapeutic procedures. While BenchChem strives to provide accurate protocols, we make no warranties, express or implied, regarding the fitness of this product for every specific experimental setup.

Technical Support: The protocols provided are for reference purposes. Unsure if this reagent suits your experiment? [[Contact our Ph.D. Support Team for a compatibility check](#)]

Need Industrial/Bulk Grade? [Request Custom Synthesis Quote](#)

BenchChem

Our mission is to be the trusted global source of essential and advanced chemicals, empowering scientists and researchers to drive progress in science and industry.

Contact

Address: 3281 E Guasti Rd

Ontario, CA 91761, United States

Phone: (601) 213-4426

Email: info@benchchem.com