

# troubleshooting common artifacts in Ga-68 gozetotide PET imaging

**Author:** BenchChem Technical Support Team. **Date:** December 2025

## Compound of Interest

Compound Name: Gallium Ga-68 gozetotide

Cat. No.: B10822203

[Get Quote](#)

## Technical Support Center: Ga-68 Gozetotide PET Imaging

This technical support center provides troubleshooting guides and frequently asked questions (FAQs) to help researchers, scientists, and drug development professionals address common artifacts and issues encountered during Gallium-68 (Ga-68) gozetotide (PSMA-11) PET imaging.

## Frequently Asked Questions (FAQs) & Troubleshooting Guides

### Category 1: Technical & Reconstruction Artifacts

**Question:** Why do I see a photopenic area or "halo" around the kidneys and bladder in my Ga-68 gozetotide PET images?

**Answer:** This is known as a "halo" or "scatter" artifact.<sup>[1]</sup> It is a common occurrence in Ga-68 PSMA PET imaging due to the high concentration of the radiotracer in the urinary system (kidneys and bladder), which is the primary route of excretion.<sup>[2][3][4][5]</sup> This high activity leads to an overestimation and inaccurate correction for scatter by standard reconstruction algorithms, creating a photopenic or "washed-out" region around these organs.<sup>[1][6][7]</sup> This artifact can potentially mask or obscure nearby lesions, such as pelvic or retroperitoneal lymph nodes.<sup>[1][3]</sup>

### Troubleshooting Steps:

- **Furosemide Administration:** Administering a diuretic like furosemide (e.g., 20 mg IV) at the time of or shortly after the radiotracer injection can help increase urinary excretion and reduce the concentration of Ga-68 gozetotide in the urinary system, thereby mitigating the artifact.[\[1\]](#)[\[8\]](#)[\[9\]](#)
- **Delayed Imaging:** Performing a delayed scan may help as it allows for further clearance of the tracer from the urinary system.[\[4\]](#)
- **Advanced Scatter Correction Algorithms:** Using improved or specialized scatter correction algorithms, particularly time-of-flight (TOF) reconstruction, can significantly reduce the severity of the halo artifact.[\[1\]](#)[\[6\]](#)[\[7\]](#) Studies have shown that improved TOF scatter correction results in the lowest scatter severity.[\[10\]](#)[\[11\]](#)
- **Image Review:** Always review non-attenuation corrected (NAC) images alongside the attenuation-corrected (AC) images. Artifacts introduced by the CT-based attenuation and scatter correction will not be present on the NAC images.[\[12\]](#)

**Question:** What causes streak artifacts in the reconstructed PET images, and how can they be minimized?

**Answer:** Streak artifacts, which appear as bright or dark lines, can arise from several sources in PET/CT imaging.

- **Metallic Implants:** High-density materials like metallic implants (e.g., dental fillings, prosthetic hips) cause significant attenuation of X-rays during the CT scan. This leads to streaking on the CT image, and when this CT is used for PET attenuation correction, it introduces errors and artifacts onto the final PET image.[\[12\]](#)[\[13\]](#)
- **Patient Motion:** Movement during either the CT or PET acquisition can cause misalignment between the two scans, resulting in misregistration artifacts that can manifest as streaks.[\[14\]](#)[\[15\]](#)
- **Reconstruction Parameters:** The choice of image reconstruction technique can influence the presence of artifacts. While iterative reconstruction is standard, in some compromised scanner situations, filtered back-projection (FBP) with sinogram correction has been shown

to minimize streak artifacts.[16] Changes in CT reconstruction parameters can also be a cause.[17]

#### Troubleshooting Steps:

- **Metal Artifact Reduction (MAR):** Utilize MAR software for the CT reconstruction, which can help reduce artifacts from metallic implants before the CT is used for PET attenuation correction.[13]
- **Patient Positioning and Instruction:** Ensure the patient is comfortable and well-instructed to remain still during the scan to prevent motion.[14][15] Positioning the patient's arms above their head can also help avoid artifacts in the torso.[14]
- **Review Non-Corrected Images:** Compare the corrected PET images with non-corrected images to identify if the artifact is a result of the correction process.[12]

**Question:** What is a truncation artifact and how does it affect quantification?

**Answer:** A truncation artifact occurs when parts of the patient's body, typically the arms or in larger patients, are outside the CT scanner's field of view (FOV) but inside the PET scanner's FOV.[14][18] Because the CT data is used to create the attenuation map for the PET data, the areas outside the CT FOV will lack attenuation correction.[13][14] This leads to an underestimation of radiotracer uptake in the truncated regions and a bright rim of apparent high activity at the edge of the FOV, biasing quantification.[12][14]

#### Troubleshooting Steps:

- **Proper Patient Positioning:** Position the patient so that their entire body cross-section is within the CT FOV. For imaging of the torso, this often means placing the patient's arms above their head.[14]
- **Use of Extended FOV Reconstruction:** Some modern scanners have software that can estimate the attenuation map for areas outside the CT FOV, helping to correct for truncation artifacts.[19]

## Category 2: Patient & Radiotracer-Related Issues

Question: I am seeing focal uptake near the injection site that is not related to the primary disease. What could be the cause?

Answer: This is likely due to extravasation of the radiotracer at the injection site. If the Ga-68 gozetotide is not injected properly into the vein, some of the dose can infiltrate the surrounding subcutaneous tissue. This can lead to intense focal uptake at the injection site and potential uptake in the draining lymphatic system, which could be misinterpreted as a metastatic lymph node.[\[20\]](#)

Troubleshooting Steps:

- Careful IV Administration: Ensure proper intravenous administration, followed by a saline flush to ensure the full dose reaches circulation.[\[21\]](#)
- Record Injection Site: Always document the injection site. If unexpected uptake is seen in a draining lymph node basin (e.g., axillary lymph node), correlate it with the injection location.[\[20\]](#)
- Repeat Imaging: In ambiguous cases where a finding could be due to extravasation, repeating the scan with the injection in the contralateral arm can confirm or rule out the finding.[\[20\]](#)

Question: The biodistribution of the radiotracer appears unusual, with high uptake in the liver and spleen. What happened?

Answer: The normal biodistribution of Ga-68 gozetotide involves intense uptake in the kidneys, urinary bladder, lacrimal glands, and salivary glands, with lower, uniform activity in the liver and spleen.[\[2\]](#) If you observe unexpectedly high uptake in the liver and spleen, and perhaps the pituitary or thyroid glands, it is possible that the wrong radiotracer was administered, such as a Ga-68 labeled somatostatin analog (e.g., DOTATATE), which has a different biodistribution pattern.[\[3\]](#)[\[22\]](#)[\[23\]](#)

Troubleshooting Steps:

- Verify Radiopharmaceutical: Immediately verify the radiopharmaceutical that was prepared and administered. Cross-contamination or mislabeling in the radiopharmacy can occur.[\[3\]](#)

- Review Biodistribution Patterns: Be familiar with the normal biodistribution patterns of all Ga-68 tracers used in your facility to quickly identify deviations. Ga-68 DOTATATE, for example, shows the most avid uptake in the spleen, adrenal glands, kidneys, and pituitary gland.[\[22\]](#)  
[\[23\]](#)

## Quantitative Data Summary

The following table summarizes findings on the impact of furosemide and different scatter correction algorithms on the severity of scatter artifacts in Ga-68 PSMA PET imaging.

Imaging & Correction Method	Percentage of Patients with Severe Scatter Artifacts	Key Finding
Non-Time-of-Flight (non-TOF) without Furosemide	42.1%	Highest rate of severe artifacts observed. <a href="#">[11]</a> <a href="#">[24]</a>
Non-Time-of-Flight (non-TOF) with Furosemide	Reduced vs. without Furosemide	Furosemide reduces mean scatter severity. <a href="#">[11]</a>
Standard Time-of-Flight (TOF) with Furosemide	Reduced vs. without Furosemide	Furosemide reduces mean scatter severity. <a href="#">[11]</a>
Improved Time-of-Flight (TOF)	6.5%	Resulted in the lowest scatter severity, regardless of furosemide administration. <a href="#">[10]</a> <a href="#">[11]</a>

## Experimental Protocols

### Standard Protocol for Ga-68 Gozetotide PET/CT Imaging

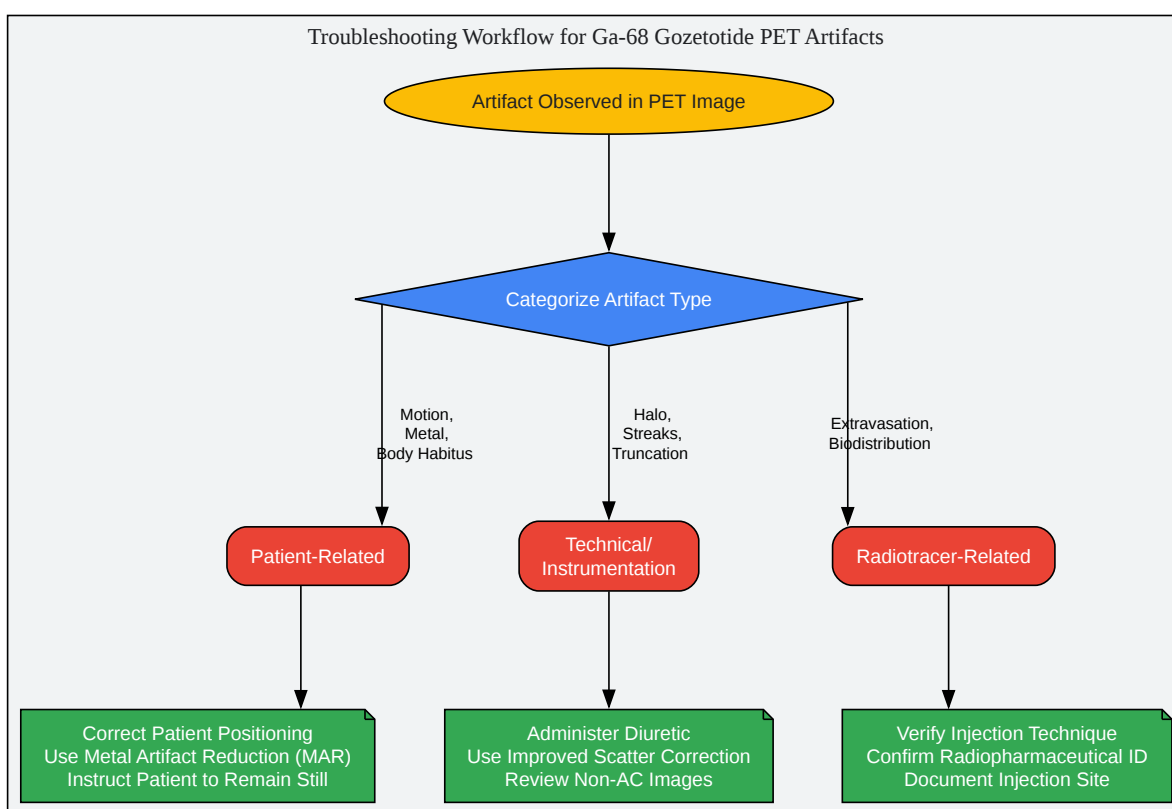
This protocol is a synthesis of common practices and guidelines.[\[8\]](#)[\[9\]](#)

- Patient Preparation:
  - Hydration: Instruct patients to be well-hydrated by drinking sufficient water before and after the scan to reduce radiation exposure and promote urinary clearance.[\[9\]](#)[\[21\]](#)

- Fasting: Fasting is generally not required.[4]
- Voiding: Patients should void immediately before the start of image acquisition to minimize activity in the bladder.[4][9]
- Radiopharmaceutical Administration:
  - Dose: The recommended dose for adults is 111 MBq to 259 MBq (3 mCi to 7 mCi).[9]
  - Administration: Administer as an intravenous bolus injection using aseptic technique. Follow with a saline flush to ensure the full dose is delivered.[9][21]
  - Diuretic (Optional): To reduce urinary artifacts, a diuretic (e.g., 20 mg furosemide IV) may be administered at the time of injection, unless contraindicated.[8][9]
- Image Acquisition:
  - Uptake Time: Begin scanning 50 to 100 minutes after the intravenous injection.[9]
  - Patient Positioning: Position the patient supine with arms raised above the head to avoid truncation artifacts and beam hardening in the torso.[9][14]
  - Scanning Range: The scan should typically cover from the mid-thigh to the base of the skull.[9]

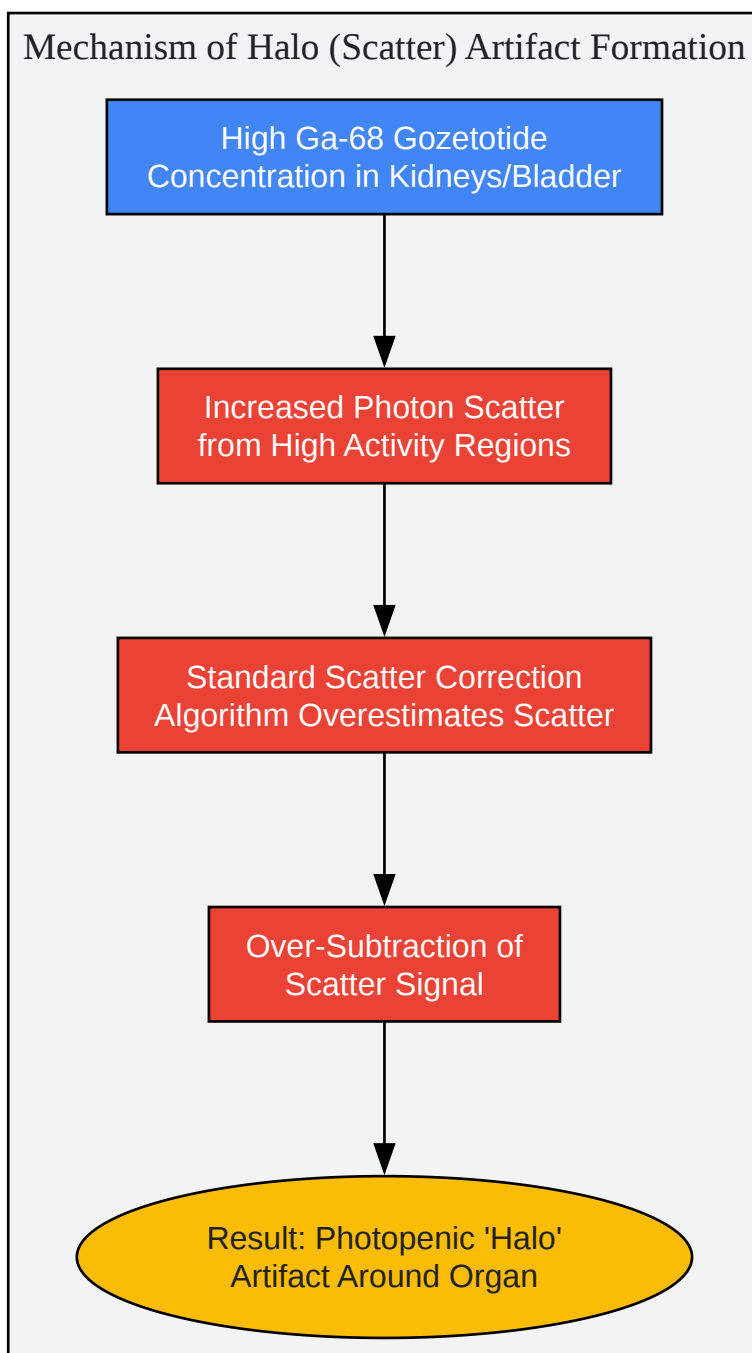
## Visual Troubleshooting Guides

Below are diagrams to visualize common artifact pathways and troubleshooting logic.



[Click to download full resolution via product page](#)

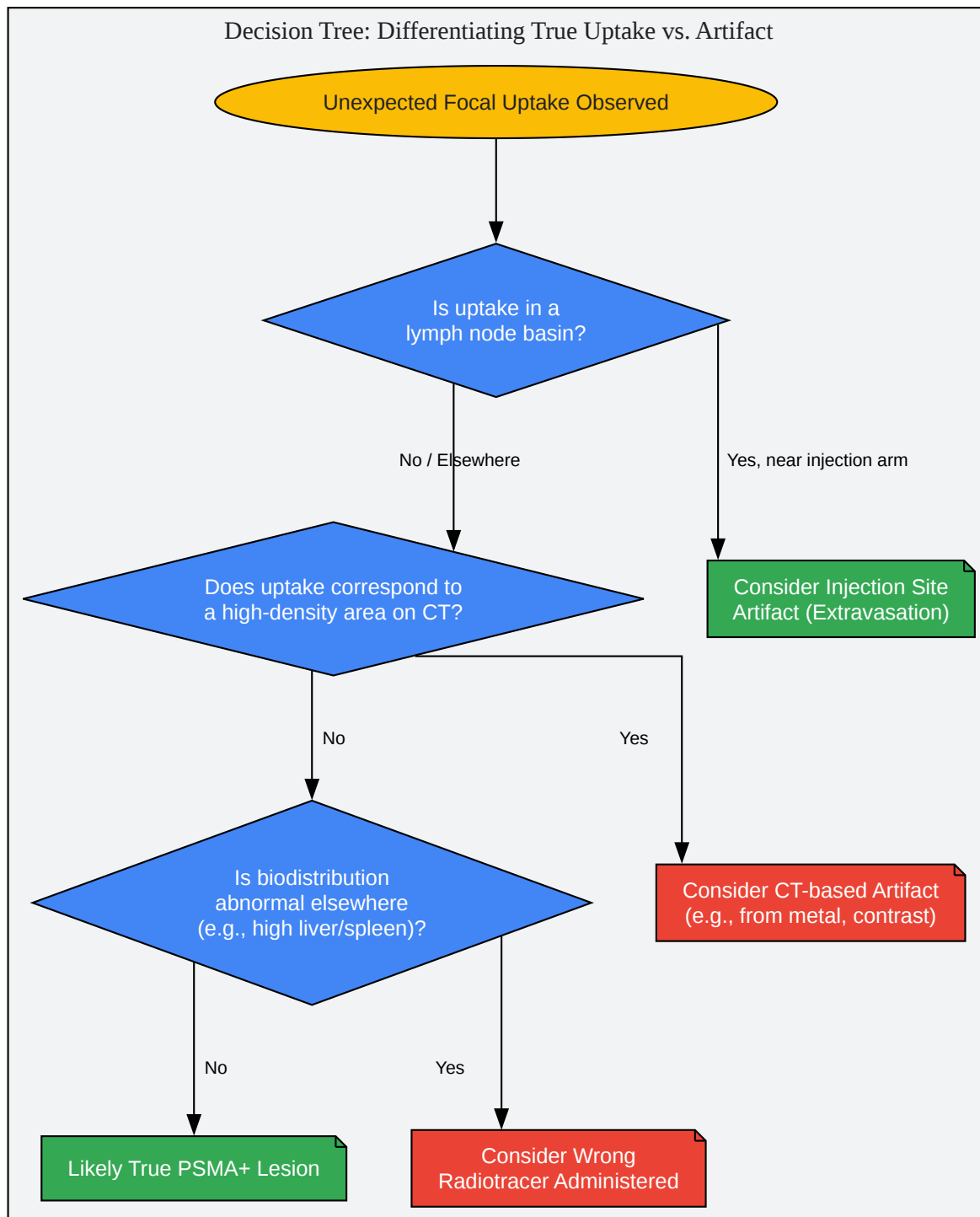
Caption: General troubleshooting workflow for common artifacts.



[Click to download full resolution via product page](#)

Caption: Flowchart explaining the cause of halo artifacts.





[Click to download full resolution via product page](#)

Caption: Decision logic for interpreting unexpected focal uptake.

**Need Custom Synthesis?**

BenchChem offers custom synthesis for rare earth carbides and specific isotopic labeling.

Email: [info@benchchem.com](mailto:info@benchchem.com) or [Request Quote Online](#).

## References

- 1. Scatter Artifact with Ga-68-PSMA-11 PET: Severity Reduced With Furosemide Diuresis and Improved Scatter Correction - PMC [pmc.ncbi.nlm.nih.gov]
- 2. Frontiers | Normal Variants, Pitfalls, and Artifacts in Ga-68 Prostate Specific Membrane Antigen (PSMA) PET/CT Imaging [frontiersin.org]
- 3. Normal Variants, Pitfalls, and Artifacts in Ga-68 Prostate Specific Membrane Antigen (PSMA) PET/CT Imaging - PMC [pmc.ncbi.nlm.nih.gov]
- 4. Gallium-68 Prostate-Specific Membrane Antigen Positron Emission Tomography: A Practical Guide for Radiologists and Clinicians - PMC [pmc.ncbi.nlm.nih.gov]
- 5. researchgate.net [researchgate.net]
- 6. jnm.snmjournals.org [jnm.snmjournals.org]
- 7. Investigation of the halo-artifact in 68Ga-PSMA-11-PET/MRI | PLOS One [journals.plos.org]
- 8. PSMA PET/CT: joint EANM procedure guideline/SNMMI procedure standard for prostate cancer imaging 2.0 - PMC [pmc.ncbi.nlm.nih.gov]
- 9. accessdata.fda.gov [accessdata.fda.gov]
- 10. Scatter Artifact with Ga-68-PSMA-11 PET: Severity Reduced With Furosemide Diuresis and Improved Scatter Correction | Semantic Scholar [semanticscholar.org]
- 11. Scatter Artifact with Ga-68-PSMA-11 PET: Severity Reduced With Furosemide Diuresis and Improved Scatter Correction [escholarship.org]
- 12. Artefacts of PET/CT images - PMC [pmc.ncbi.nlm.nih.gov]
- 13. Pitfalls on PET/CT due to artifacts and instrumentation - PMC [pmc.ncbi.nlm.nih.gov]
- 14. cme.lww.com [cme.lww.com]
- 15. Recognizing and preventing artifacts with SPECT and PET imaging | Radiology Key [radiologykey.com]
- 16. thieme-connect.com [thieme-connect.com]

- 17. jscholaronline.org [jscholaronline.org]
- 18. FDG PET/CT: Artifacts and Pitfalls [icrjournal.ir]
- 19. researchgate.net [researchgate.net]
- 20. m.youtube.com [m.youtube.com]
- 21. newyorkoncology.com [newyorkoncology.com]
- 22. Frontiers | Normal Variants, Pitfalls and Artifacts in Ga-68 DOTATATE PET/CT Imaging [frontiersin.org]
- 23. Normal Variants, Pitfalls and Artifacts in Ga-68 DOTATATE PET/CT Imaging - PMC [pmc.ncbi.nlm.nih.gov]
- 24. researchgate.net [researchgate.net]
- To cite this document: BenchChem. [troubleshooting common artifacts in Ga-68 gozetotide PET imaging]. BenchChem, [2025]. [Online PDF]. Available at: [https://www.benchchem.com/product/b10822203#troubleshooting-common-artifacts-in-ga-68-gozetotide-pet-imaging]

---

### Disclaimer & Data Validity:

The information provided in this document is for Research Use Only (RUO) and is strictly not intended for diagnostic or therapeutic procedures. While BenchChem strives to provide accurate protocols, we make no warranties, express or implied, regarding the fitness of this product for every specific experimental setup.

**Technical Support:** The protocols provided are for reference purposes. Unsure if this reagent suits your experiment? [[Contact our Ph.D. Support Team for a compatibility check](#)]

**Need Industrial/Bulk Grade?** [Request Custom Synthesis Quote](#)

## BenchChem

Our mission is to be the trusted global source of essential and advanced chemicals, empowering scientists and researchers to drive progress in science and industry.

### Contact

Address: 3281 E Guasti Rd  
Ontario, CA 91761, United States  
Phone: (601) 213-4426  
Email: [info@benchchem.com](mailto:info@benchchem.com)

