

troubleshooting artifacts in DOTA-NAPamide PET/CT images

Author: BenchChem Technical Support Team. **Date:** December 2025

Compound of Interest

Compound Name: DOTA-NAPamide

Cat. No.: B15604551

[Get Quote](#)

DOTA-NAPamide PET/CT Imaging: Technical Support Center

This technical support center provides troubleshooting guidance and frequently asked questions (FAQs) for researchers, scientists, and drug development professionals utilizing **DOTA-NAPamide** PET/CT imaging. The information is designed to help identify and mitigate common artifacts and pitfalls encountered during experimental procedures.

Frequently Asked Questions (FAQs)

Q1: What are the most common types of artifacts observed in **DOTA-NAPamide** PET/CT images?

A1: Artifacts in PET/CT imaging are primarily categorized as those arising from the patient, the scanner instrumentation, or the reconstruction process. Common artifacts include those caused by patient motion (respiratory and voluntary), metallic implants, CT contrast agents, and truncation of the CT field of view.^{[1][2]} Misalignment between the PET and CT data is a frequent issue that can lead to inaccurate attenuation correction and localization of tracer uptake.^{[3][4]}

Q2: How can I differentiate between true **DOTA-NAPamide** uptake and artifacts?

A2: Differentiating true tracer uptake from artifacts requires careful examination of both the attenuation-corrected and non-attenuation-corrected PET images, alongside the corresponding CT scan.[1] Artifacts often present with characteristic patterns, such as intense, well-defined "hot spots" near metallic implants or streak-like artifacts. Reviewing the CT images can help identify underlying anatomical causes for apparent uptake, such as dense materials or patient motion.

Q3: What is the impact of respiratory motion on **DOTA-NAPamide** PET/CT images?

A3: Respiratory motion is a significant source of artifacts, particularly for structures near the diaphragm like the liver and lung bases.[3][5] This motion can cause a mismatch between the PET and CT data, leading to mislocalization of lesions and inaccurate quantification of tracer uptake (SUV values).[3][5] The CT scan is typically a quick breath-hold acquisition, while the PET scan is acquired over a longer period of tidal breathing, leading to this potential for misregistration.[5]

Q4: Can metallic implants, such as dental fillings or surgical clips, affect my **DOTA-NAPamide** PET/CT scan?

A4: Yes, metallic implants are a common cause of significant artifacts in PET/CT imaging.[1] The high density of the metal causes severe streak artifacts on the CT image. When this erroneous CT data is used for attenuation correction, it can lead to an overcorrection of the PET data, creating false-positive "hot spots" of tracer uptake.[1]

Troubleshooting Guides

This section provides a structured approach to identifying and addressing specific artifacts.

Issue 1: Intense, Focal "Hot Spot" Artifacts

Symptoms:

- An area of very high tracer uptake that does not correspond to a known or suspected lesion.
- The "hot spot" may appear in a location inconsistent with the expected biodistribution of **DOTA-NAPamide**.

Possible Causes & Solutions:

Cause	Identification	Recommended Action
Metallic Implants	Review CT images for the presence of high-density materials (e.g., dental implants, surgical clips, prostheses) corresponding to the PET hot spot.[1]	1. Review the non-attenuation-corrected (NAC) PET images to see if the "hot spot" persists. If it disappears or is significantly reduced, it is likely an artifact. 2. Utilize metal artifact reduction software (MARS) during CT reconstruction if available. 3. Correlate with other imaging modalities (e.g., MRI) if necessary.
CT Contrast Media	Check the patient's history and the imaging protocol to determine if intravenous or oral contrast was used.[6] High concentrations of contrast can be misinterpreted on the attenuation map.[4]	1. If possible, perform a non-contrast CT for attenuation correction prior to the diagnostic contrast-enhanced CT.[6] 2. Careful review of the contrast-enhanced CT can help differentiate true uptake from contrast-related artifacts.
Radiotracer Extravasation	Examine the injection site for a "hot spot" that may be due to the tracer not being fully administered intravenously.[2]	1. Careful intravenous injection technique is crucial. 2. If extravasation occurs, it should be noted in the records, as it can affect the quantification of uptake in other regions.[2]

Issue 2: Misalignment and Blurring of Lesions

Symptoms:

- Poorly defined lesion margins.

- Apparent displacement of a lesion between the PET and CT images.
- Curvilinear "cold" artifacts near the diaphragm.[4]

Possible Causes & Solutions:

Cause	Identification	Recommended Action
Respiratory Motion	Observe blurring or "doubling" of lesions in the lower chest and upper abdomen.[3] The position of the diaphragm may differ significantly between the PET and CT images.[6]	1. Respiratory gating during acquisition can help to minimize motion artifacts. 2. If gating is not available, instructing the patient to breathe shallowly during the scan may help. 3. Reviewing the cine-loop of the PET data can help visualize the extent of motion.
Patient Movement	Misregistration of anatomical structures, particularly in the head and neck or extremities. [5] This is more common in longer scans.	1. Ensure the patient is comfortable and well-immobilized before starting the scan. 2. Use of headrests, straps, and cushions can help minimize voluntary motion. 3. If significant motion is detected, the scan may need to be repeated.
Image Truncation	The patient's body extends beyond the CT field of view (FOV), leading to incomplete data for attenuation correction. [1][2] This is more common in larger patients.	1. Proper patient positioning is key. For body scans, having the patient raise their arms above their head can help reduce truncation.[1] 2. Some modern scanners have a larger CT FOV to mitigate this issue.[2] 3. Extended FOV reconstruction algorithms can also be used to correct for truncation artifacts.[2]

Quantitative Impact of Artifacts on SUV

The following table summarizes the potential quantitative effects of common artifacts on Standardized Uptake Value (SUV) measurements.

Artifact Type	Effect on SUV	Approximate Magnitude of Change
Metallic Artifacts	Can cause both false increases and decreases in SUV.[7]	In bright streak regions, SUV can increase by over 90%, while in dark streak regions, it can decrease by about 20%.[7]
Respiratory Motion	Generally leads to an underestimation of SUVmax due to blurring of the lesion.	Can lead to a 20-30% underestimation of SUVmax, depending on the extent of motion.
Contrast Media	High concentrations can lead to an overestimation of SUV.	Can overestimate tracer activity by as much as 20% in some cases.[6]

Experimental Protocols

Standardized PET/CT Quality Control Protocol

A rigorous quality control (QC) program is essential for ensuring the accuracy and reliability of PET/CT imaging data.

1. Daily Quality Control:

- Blank Scan: Performed to check the function of the scintillation detectors.
- System Initialization & Calibration: Includes checks of the coincidence timing and photo-multiplier gain calibration.

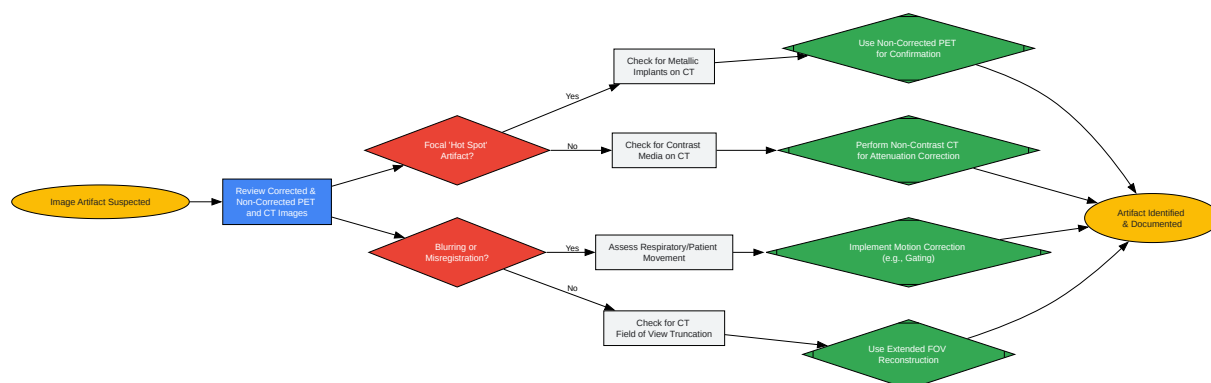
2. Weekly Quality Control:

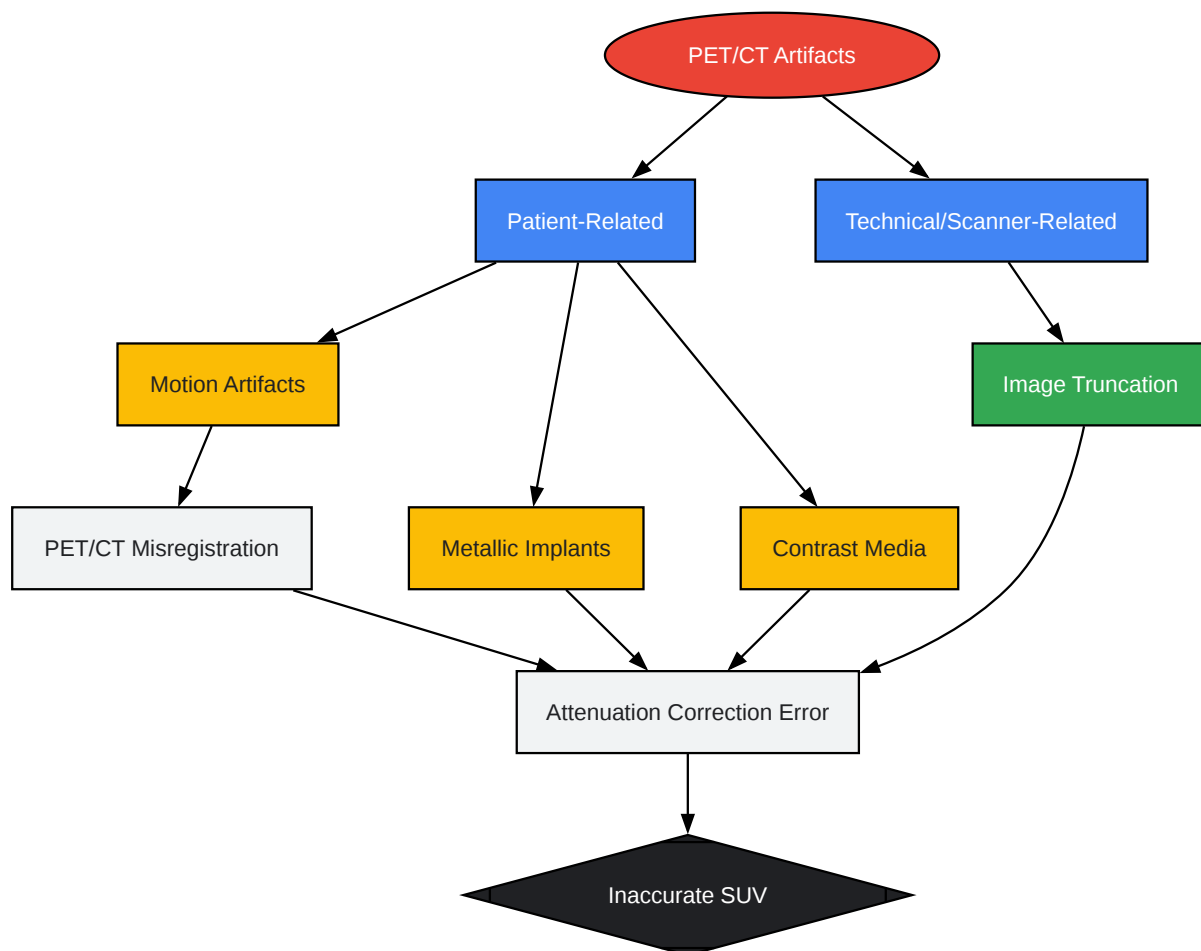
- Extended Blank Scan: A longer duration scan to ensure detector stability.
- Normalization Scan: Corrects for variations in sensitivity between different lines of response in the PET detector ring.

3. Quarterly/Annual Quality Control:

- Well Counter Calibration: Ensures the accuracy of quantitative values (e.g., SUVs) by comparing scanner measurements to a calibrated dose of radiotracer in a phantom.
- Phantom Scans: Imaging of standardized phantoms (e.g., Jaszczak phantom) to assess image quality parameters such as spatial resolution, contrast, and uniformity.

Key Visualizations





[Click to download full resolution via product page](#)

Need Custom Synthesis?

BenchChem offers custom synthesis for rare earth carbides and specific isotopic labeling.

Email: info@benchchem.com or [Request Quote Online](#).

References

- 1. Artefacts of PET/CT images - PMC [pmc.ncbi.nlm.nih.gov]
- 2. tech.snmjournals.org [tech.snmjournals.org]

- 3. Motion Artifacts and Correction Techniques in PET/CT | Radiology Key [radiologykey.com]
- 4. Pitfalls on PET/CT due to artifacts and instrumentation - PMC [pmc.ncbi.nlm.nih.gov]
- 5. Normal Variants, Pitfalls and Artifacts in Ga-68 DOTATATE PET/CT Imaging - PMC [pmc.ncbi.nlm.nih.gov]
- 6. PET/CT Artifacts - PMC [pmc.ncbi.nlm.nih.gov]
- 7. researchgate.net [researchgate.net]
- To cite this document: BenchChem. [troubleshooting artifacts in DOTA-NAPamide PET/CT images]. BenchChem, [2025]. [Online PDF]. Available at: [https://www.benchchem.com/product/b15604551#troubleshooting-artifacts-in-dota-
napamide-pet-ct-images]

Disclaimer & Data Validity:

The information provided in this document is for Research Use Only (RUO) and is strictly not intended for diagnostic or therapeutic procedures. While BenchChem strives to provide accurate protocols, we make no warranties, express or implied, regarding the fitness of this product for every specific experimental setup.

Technical Support: The protocols provided are for reference purposes. Unsure if this reagent suits your experiment? [[Contact our Ph.D. Support Team for a compatibility check](#)]

Need Industrial/Bulk Grade? [Request Custom Synthesis Quote](#)

BenchChem

Our mission is to be the trusted global source of essential and advanced chemicals, empowering scientists and researchers to drive progress in science and industry.

Contact

Address: 3281 E Guasti Rd
Ontario, CA 91761, United States
Phone: (601) 213-4426
Email: info@benchchem.com