

strategies to reduce false positives in paramagnetic rim lesion detection

Author: BenchChem Technical Support Team. **Date:** December 2025

Compound of Interest

Compound Name: WYneN

Cat. No.: B15548174

[Get Quote](#)

Technical Support Center: Paramagnetic Rim Lesion (PRL) Analysis

Welcome to the technical support center for paramagnetic rim lesion (PRL) detection. This resource provides researchers, scientists, and drug development professionals with detailed troubleshooting guides and frequently asked questions (FAQs) to enhance the accuracy and reliability of PRL identification in experimental and clinical settings.

Frequently Asked Questions (FAQs)

Q1: What is a paramagnetic rim lesion (PRL) and why is it significant?

A1: A paramagnetic rim lesion (PRL), also known as an iron rim lesion, is a specific type of white matter lesion visible on magnetic resonance imaging (MRI). These lesions are characterized by a rim of iron-laden, activated microglia and macrophages at their edge, which reflects chronic, smoldering inflammation.^{[1][2][3]} This iron content makes the rim appear hypointense (dark) on susceptibility-based MRI sequences.^[1] PRLs are considered a highly specific imaging biomarker for multiple sclerosis (MS) and are associated with a more aggressive disease course and increased disability.^[1] Their accurate detection is crucial for diagnosis, prognosis, and as a potential endpoint in clinical trials.

Q2: What are the most common sources of false positives when identifying PRLs?

A2: False positives in PRL detection can arise from several sources that mimic the characteristic hypointense rim. It is critical to differentiate true PRLs from these mimics to ensure diagnostic and prognostic accuracy. The primary sources include:

- **Venous Structures:** Small veins at the edge of or within a lesion can appear as a hypointense signal on susceptibility-weighted images, mimicking a paramagnetic rim. Careful co-registration with FLAIR images and multi-planar review are essential to trace the linear structure of veins.
- **Susceptibility Artifacts:** Artifacts can occur at tissue interfaces with different magnetic susceptibilities, such as bone-air-parenchyma interfaces or near the sinuses. These can create rim-like hypointensities that are not related to iron deposition.
- **Phase Imaging Limitations:** Standard phase imaging is prone to non-local field effects, where susceptibility sources outside the region of interest can create artifactual rim-like appearances, leading to false-positive detections.
- **Lesion Confluence:** When multiple lesions merge, the border between them can sometimes create a complex signal pattern that may be misinterpreted as a rim.
- **Gadolinium Enhancement:** Assessments for PRLs, which signify chronic inflammation, should not be performed on currently contrast-enhancing lesions, as these represent acute inflammation and the underlying signal characteristics can be ambiguous.

Q3: My analysis is flagging veins as PRLs. How can I prevent this?

A3: Differentiating veins from true paramagnetic rims is a common challenge. Here are several strategies to mitigate this issue:

- **Multi-Planar Analysis:** Review the lesion in all three orthogonal planes (axial, sagittal, and coronal). Veins will typically appear as linear or tubular structures in at least one plane,

whereas a true PRL rim will conform to the ovoid shape of the lesion. The rim should be discernible on at least two consecutive slices or in two orthogonal planes.

- **Co-registration with FLAIR/T2w Images:** Precisely co-register your susceptibility-weighted images (e.g., SWI, phase) with high-resolution anatomical images like 3D T2-FLAIR. A true PRL must be co-localized with a T2/FLAIR hyperintense white matter lesion. This allows for accurate delineation of the lesion border.
- **Central Vein Sign (CVS) Awareness:** Be aware of the central vein sign, where a vein runs through the center of a lesion, which is also a marker for MS. Do not confuse perivenular signal changes with a peripheral rim.
- **Utilize Quantitative Susceptibility Mapping (QSM):** QSM is an advanced post-processing technique that resolves many of the ambiguities of phase imaging. It provides a more accurate representation of local tissue susceptibility, significantly reducing false positives caused by non-local field effects and better delineating true iron deposition.

Troubleshooting Guides

Guide 1: Optimizing MRI Acquisition for PRL Detection

Suboptimal MRI acquisition is a primary reason for poor PRL visibility and low detection accuracy. This guide provides recommendations for optimizing your protocol.

Issue: Difficulty visualizing or confidently identifying PRLs on 1.5T or 3T scanners.

Solution: Implement a dedicated, high-resolution susceptibility-based imaging sequence. While 7T MRI offers the best visualization, PRLs can be reliably detected on 3T and even 1.5T scanners with an optimized protocol.

Recommended Experimental Protocol (3T MRI):

This protocol is based on parameters cited in successful PRL detection studies.

| Parameter | Recommended Value | Rationale |
|-------------------|---|---|
| Sequence | 3D Gradient Echo (GRE) / EPI | Provides high-resolution magnitude and phase data essential for susceptibility imaging. |
| Field Strength | 3T or higher | Enhances susceptibility effects, making iron rims more conspicuous. |
| Resolution | Sub-millimetric isotropic (e.g., 0.65 x 0.65 x 0.65 mm ³) | High resolution is critical to resolve the fine structure of the rim. |
| Echo Time (TE) | Longer TE (e.g., 20-23 ms) | Increases sensitivity to susceptibility effects. A longer TE can improve rim visibility on SWI. |
| Flip Angle (FA) | Higher FA (e.g., 15-20°) | Can improve the contrast of the rim structure on SWI magnitude images. |
| Co-Acquired Scans | 3D T2-FLAIR (e.g., 1 mm ³ isotropic) | Essential for anatomical co-localization and defining the white matter lesion boundary. |

Note: Phase images are often more sensitive than SWI magnitude images for detecting the hypointense rim.

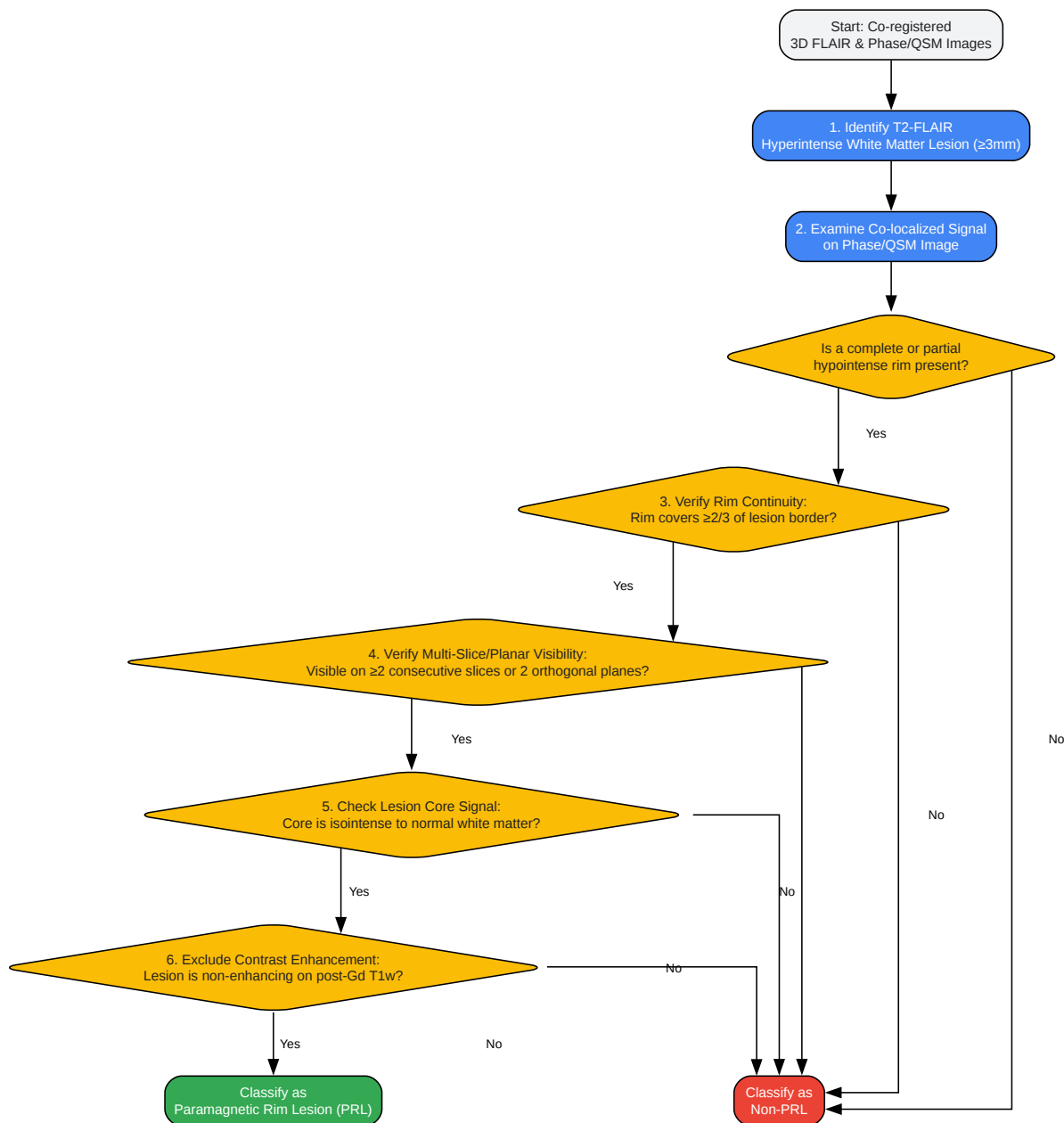
Guide 2: Standardizing Manual PRL Annotation to Reduce Variability

Manual identification of PRLs is prone to high inter- and intra-rater variability. A standardized workflow is essential for reproducible results.

Issue: Inconsistent PRL counts between different researchers or analysis sessions.

Solution: Adhere to established consensus criteria for PRL identification. The workflow below incorporates guidelines from the North American Imaging in Multiple Sclerosis (NAIMS) Cooperative.

Diagram: Standardized PRL Identification Workflow



[Click to download full resolution via product page](#)

Caption: A standardized workflow for PRL classification.

Consensus Criteria Checklist:

Use this checklist, based on NAIMS guidelines, for each potential lesion.

| Criterion | Yes/No | Notes |
|---|---|-------|
| 1. Co-localized with a T2-FLAIR hyperintense lesion? | | |
| 2. Hypointense rim present on phase/QSM? | | |
| 3. Rim is continuous over at least 2/3 of the lesion border? | Rim may be open towards the cortex or ventricles. | |
| 4. Rim is visible on ≥ 2 consecutive slices or 2 orthogonal planes? | Confirms the 3D nature of the rim. | |
| 5. Lesion core is isointense relative to surrounding normal-appearing white matter? | Differentiates from lesions with diffuse hypointensity. | |
| 6. Lesion does not enhance with gadolinium contrast? | Excludes acute inflammatory lesions. | |
| Final Classification (All "Yes" = PRL) | | |

Guide 3: Leveraging Automated Detection Tools

Manual PRL detection is time-consuming and subject to bias. Automated tools can improve efficiency and consistency, but their outputs require careful review.

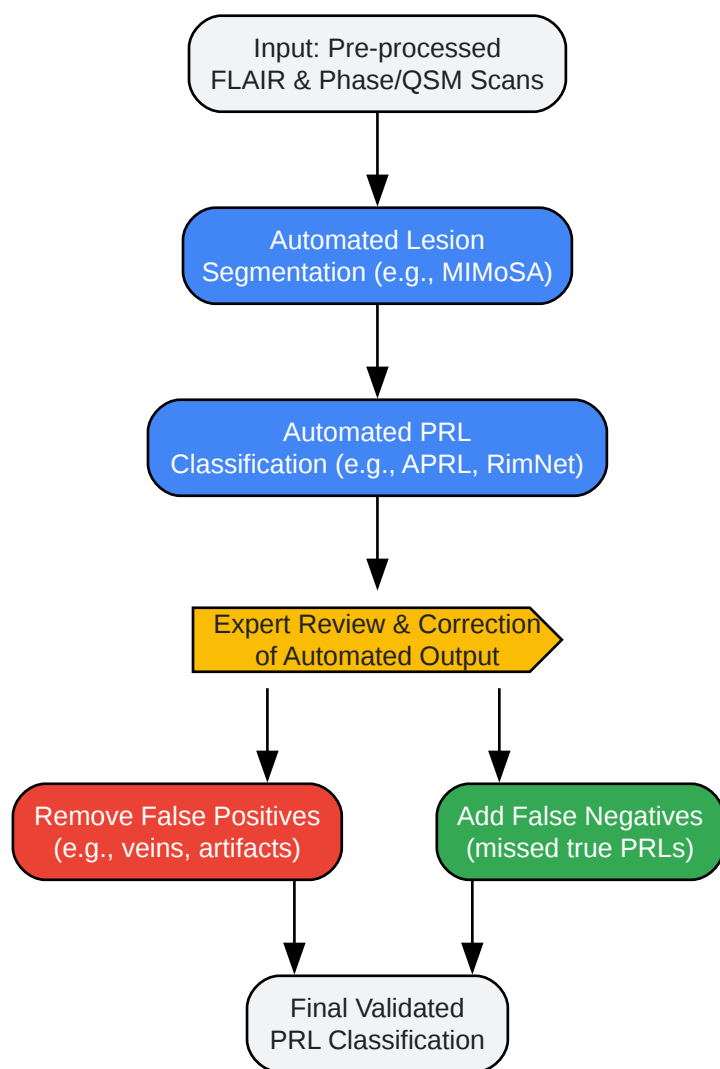
Issue: Understanding the performance and limitations of automated PRL detection algorithms.

Solution: Use automated algorithms like APRL (Automated Paramagnetic Rim Lesion) or deep learning models like RimNet as a first-pass analysis, followed by expert review. These tools can rapidly screen large datasets but are not infallible.

Performance of Automated Tools (Quantitative Summary):

| Tool/Study | Method | Performance Metric (AUC) | Key Finding |
|--------------------------|----------------------------|---|---|
| APRL (Multicenter) | Radiomics/Machine Learning | 0.73 | Differentiated PRLs from non-PRLs in a multicenter dataset. |
| Barquero et al. (RimNet) | 3D CNN (Deep Learning) | Not reported as AUC, but performance close to experts | Multimodal input (Phase + FLAIR) improves classification. |
| Gab-Allah et al. | Radiomics/Random Forest | 0.80 | Automated method highly correlated with expert manual counts. |

Diagram: Human-in-the-Loop Automated Workflow



[Click to download full resolution via product page](#)

Caption: Workflow integrating automated detection with expert review.

Best Practices for Using Automated Tools:

- **Standardize Inputs:** Ensure your input MRI data (resolution, sequence parameters) is as close as possible to the data the tool was trained on.
- **Review All Positive Findings:** Manually inspect every lesion flagged as a PRL by the algorithm, using the standardized criteria from Guide 2. Automated tools can produce false positives.

- **Spot-Check Negative Findings:** Review a subset of lesions classified as non-PRL, especially those with equivocal features, to identify potential false negatives.
- **Understand the Algorithm:** Be aware of the algorithm's specific methodology (e.g., radiomics vs. deep learning) and its known limitations, such as performance on confluent lesions or lesions in specific anatomical locations.

Need Custom Synthesis?

BenchChem offers custom synthesis for rare earth carbides and specific isotopic labeling.

Email: info@benchchem.com or [Request Quote Online](#).

References

- 1. radiopaedia.org [radiopaedia.org]
- 2. Central Vein Sign and Paramagnetic Rim Lesions: Susceptibility Changes in Brain Tissues and Their Implications for the Study of Multiple Sclerosis Pathology - PMC [pmc.ncbi.nlm.nih.gov]
- 3. Paramagnetic rim lesions and the central vein sign: characterizing multiple sclerosis imaging markers - PMC [pmc.ncbi.nlm.nih.gov]
- To cite this document: BenchChem. [strategies to reduce false positives in paramagnetic rim lesion detection]. BenchChem, [2025]. [Online PDF]. Available at: [https://www.benchchem.com/product/b15548174#strategies-to-reduce-false-positives-in-paramagnetic-rim-lesion-detection]

Disclaimer & Data Validity:

The information provided in this document is for Research Use Only (RUO) and is strictly not intended for diagnostic or therapeutic procedures. While BenchChem strives to provide accurate protocols, we make no warranties, express or implied, regarding the fitness of this product for every specific experimental setup.

Technical Support: The protocols provided are for reference purposes. Unsure if this reagent suits your experiment? [[Contact our Ph.D. Support Team for a compatibility check](#)]

Need Industrial/Bulk Grade? [Request Custom Synthesis Quote](#)

BenchChem

Our mission is to be the trusted global source of essential and advanced chemicals, empowering scientists and researchers to drive progress in science and industry.

Contact

Address: 3281 E Guasti Rd
Ontario, CA 91761, United States
Phone: (601) 213-4426
Email: info@benchchem.com