

minimizing inflammation after intravitreal injection of GA001

Author: BenchChem Technical Support Team. **Date:** December 2025

Compound of Interest

Compound Name: GA001

Cat. No.: B15580885

[Get Quote](#)

Technical Support Center: GA001 Intravitreal Injection

This technical support center provides researchers, scientists, and drug development professionals with troubleshooting guides and frequently asked questions (FAQs) to minimize and manage inflammation following intravitreal injection of the investigational drug **GA001**.

Troubleshooting Guide: Post-Intravitreal Injection Inflammation

This guide addresses specific issues that may arise during your experiments involving **GA001**.

Observation/Issue	Potential Cause	Recommended Action
Mild to Moderate Anterior Chamber Inflammation (Cells and Flare) within 1-3 days post-injection	Sterile inflammatory response to GA001 formulation, injection procedure, or silicone oil droplets from syringes.	<p>- Monitor: Closely observe the subject for worsening symptoms. - Topical Corticosteroids: Consider administration of topical corticosteroids (e.g., prednisolone acetate 1%) 4 times a day. - Slit-lamp Examination: Perform daily slit-lamp examinations to quantify inflammation. - Documentation: Record all clinical signs and interventions meticulously.</p>
Severe Panuveitis with Hypopyon and Significant Vision Loss within 1-3 days post-injection	Infectious Endophthalmitis (until proven otherwise). This is a medical emergency.	<p>- Immediate Action: Perform an anterior chamber and vitreous tap for microbiological analysis (gram stain, bacterial and fungal cultures). - Broad-Spectrum Antibiotics: Administer intravitreal broad-spectrum antibiotics (e.g., vancomycin and ceftazidime) immediately after the tap.^[1] - Systemic evaluation: Consider systemic antibiotics in severe cases. - DO NOT ADMINISTER CORTICOSTEROIDS ALONE: Corticosteroids can worsen an active infection if not accompanied by appropriate antimicrobial therapy.</p>

Delayed Onset of Inflammation (Weeks to Months Post-Injection)	Possible immune reaction to GA001 or its aggregates, potentially a delayed hypersensitivity reaction.	<p>- Thorough Examination: Conduct a comprehensive ophthalmic examination, including dilated fundus exam and optical coherence tomography (OCT).</p> <p>- Rule out Infection: While less likely, a low-grade chronic infection should be considered. A diagnostic vitreous tap may be warranted.</p> <p>- Corticosteroid Therapy: Treatment with topical, periocular, or systemic corticosteroids may be necessary.^[2]</p> <p>- Discontinuation: Consider discontinuing further GA001 administration in the affected subject until the etiology is clear.</p>
Presence of Vitreous Opacities or "Snowballs"	Inflammatory cellular aggregates, potentially related to a sterile inflammatory response.	<p>- Imaging: Use OCT and fundus photography to document the extent and location of opacities.</p> <p>- Management: This is often managed with corticosteroids, with the route of administration depending on the severity.</p>
Increased Intraocular Pressure (IOP) Post-Injection	Can be a transient effect of the injected volume or secondary to inflammation (inflammatory glaucoma).	<p>- IOP Monitoring: Check IOP 30-60 minutes post-injection and at follow-up visits.</p> <p>- Medical Management: If elevated, consider topical anti-glaucoma medications.^{[3][4]}</p> <p>- Anterior Chamber Paracentesis: In cases of a</p>

significant IOP spike
immediately post-injection, an
anterior chamber paracentesis
may be performed with
caution.[5]

Frequently Asked Questions (FAQs)

Q1: What are the expected rates of inflammation with **GA001**?

A1: As **GA001** is an investigational drug, precise rates of inflammation are still under evaluation. However, based on data from other intravitreally administered biologics, a low incidence of sterile inflammation is anticipated. For comparison, rates of sterile uveitis/endophthalmitis with other anti-VEGF agents range from 0.05% to 4.4%.[6][7]
Subclinical anterior chamber inflammation can be more common.[6][7]

Q2: How can we differentiate between sterile inflammation and infectious endophthalmitis?

A2: Differentiating between these two conditions is critical. The following table summarizes key distinguishing features. While there can be overlap, severe pain and a rapid onset of significant vision loss are more indicative of infection.[7][8]

Feature	Sterile Inflammation	Infectious Endophthalmitis
Onset	Typically 1-3 days post-injection[9]	Usually 2-5 days post-injection, can be earlier with virulent organisms
Pain	Absent to mild/moderate[9]	Moderate to severe[8]
Vision Loss	Mild to moderate, often recovers[7]	Often severe and profound[8]
Hypopyon	Can occur, but less common	Frequently present[8]
Vitreous	Mild to moderate vitritis	Dense vitritis, often obscuring the fundus view

Q3: What steps can be taken in our experimental protocol to minimize the risk of inflammation?

A3: Minimizing inflammation is multifactorial and involves careful handling of the drug and a meticulous injection technique.[7]

- **Aseptic Technique:** Strict adherence to aseptic technique is paramount. This includes the use of povidone-iodine as a pre-injection antiseptic.[5]
- **Drug Handling:** Avoid vigorous shaking or agitation of the **GA001** solution to prevent protein aggregation, which can be immunogenic.[6] Do not freeze-thaw the drug unless specified in the protocol.
- **Syringe Selection:** Consider using silicone oil-free syringes, as silicone oil microdroplets can induce an inflammatory response.[6]
- **Injection Volume:** Ensure the injected volume is precise to avoid sudden, significant increases in intraocular pressure.
- **Patient Factors:** In clinical studies, a history of uveitis or prior inflammatory responses to intravitreal injections should be noted.[5]

Q4: If sterile inflammation is suspected, what is the recommended treatment?

A4: For mild to moderate sterile inflammation, topical corticosteroids are typically the first line of treatment.[2] For more severe, persistent, or posterior inflammation, periocular or systemic corticosteroids may be required.[2] The majority of patients with sterile inflammation recover their baseline vision within weeks.[7]

Quantitative Data on Post-Intravitreal Injection Inflammation

The following table summarizes reported rates of inflammation for various anti-VEGF agents to provide a comparative context for your experiments with **GA001**.

Agent	Type of Inflammation	Reported Incidence Rate	Citation(s)
All Anti-VEGFs	Subclinical Anterior Chamber Inflammation	Up to 19%	[6]
Ranibizumab	Sterile Uveitis/Endophthalmitis	0.02%	[10]
Aflibercept	Sterile Uveitis/Endophthalmitis	0.16%	[10]
Bevacizumab	Sterile Uveitis/Endophthalmitis	0.10%	[10]
Brolucizumab	Inflammatory Retinal Vasculitis	3.3%	[6]
Brolucizumab	Intraocular Inflammation	4.4%	[10]

Experimental Protocols

Protocol 1: Quantification of Anterior Chamber Inflammation

Objective: To quantify anterior chamber inflammation using a standardized grading system.

Methodology:

- Administer a topical anesthetic and mydriatic agent to the subject's eye.
- At a slit-lamp biomicroscope, use a standardized 1x1 mm beam of light directed obliquely into the anterior chamber.
- Focus between the cornea and the lens.

- Grade the number of cells observed in the light beam according to the Standardization of Uveitis Nomenclature (SUN) working group criteria:
 - 0: <1 cell
 - 0.5+: 1-5 cells
 - 1+: 6-15 cells
 - 2+: 16-25 cells
 - 3+: 26-50 cells
 - 4+: >50 cells
- Grade the flare (protein haze) by comparing the clarity of the aqueous humor to the clarity within the lens:
 - 0: None
 - 1+: Faint haze
 - 2+: Moderate haze (iris and lens details clear)
 - 3+: Marked haze (iris and lens details hazy)
 - 4+: Intense haze (fibrin or plastic aqueous)
- Record the grades at baseline and at specified follow-up time points (e.g., Day 1, Day 3, Day 7 post-injection).

Protocol 2: Vitreous Haze Assessment

Objective: To assess the degree of vitreous inflammation.

Methodology:

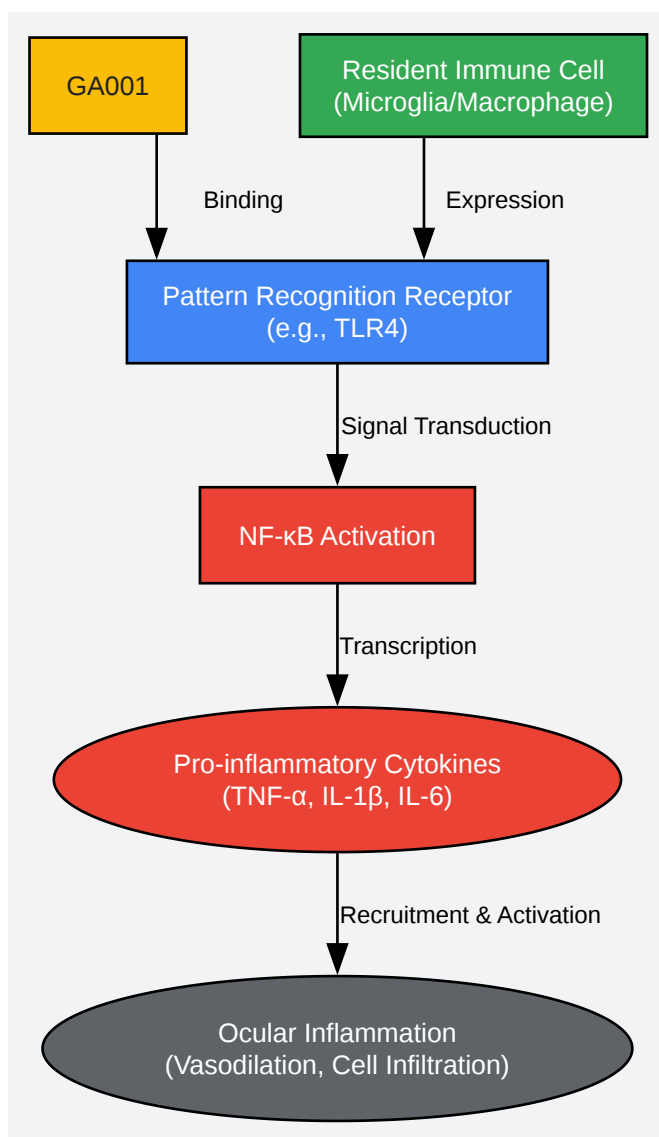
- Perform indirect ophthalmoscopy with a 20D or 28D lens after pupillary dilation.

- Grade the vitreous haze based on the clarity of the retinal details according to the National Eye Institute/SUN working group scale:
 - 0: No inflammation
 - 1+: Trace haze, clear optic disc and vessels
 - 2+: Mild haze, optic disc and vessels still clear
 - 3+: Moderate haze, optic disc and vessels hazy
 - 4+: Marked haze, optic disc obscured
- Document findings with fundus photography for a more objective comparison over time.

Visualizations

Hypothetical Inflammatory Signaling Pathway Triggered by **GA001**

This diagram illustrates a hypothetical signaling cascade that could be initiated by the intravitreal injection of **GA001**, leading to an inflammatory response. This could occur if **GA001** or impurities in its formulation are recognized by resident immune cells in the eye, such as microglia or macrophages.



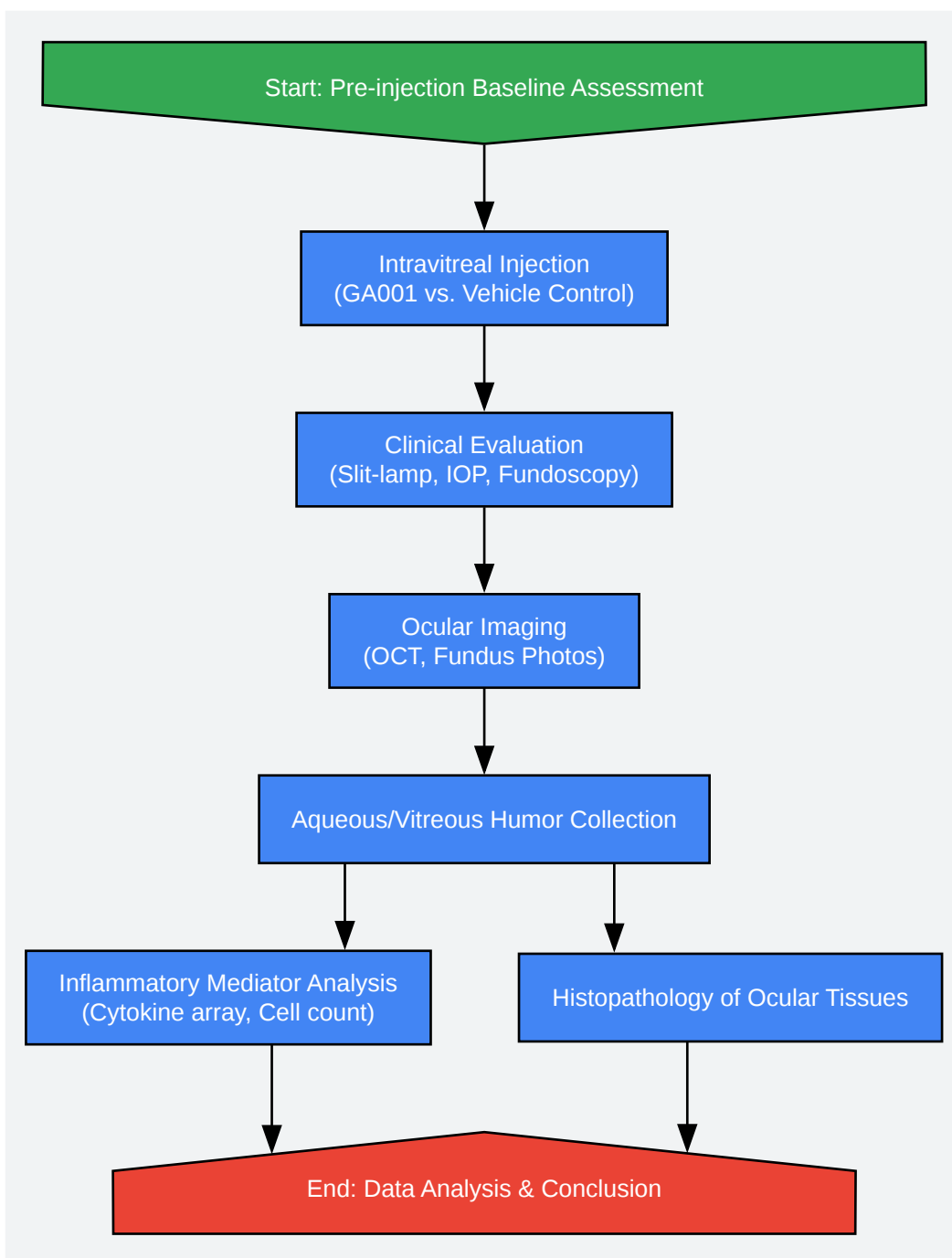
Hypothetical GA001 Inflammatory Cascade

[Click to download full resolution via product page](#)

Caption: Hypothetical inflammatory pathway initiated by **GA001**.

Experimental Workflow for Investigating Post-Injection Inflammation

This workflow outlines the key steps for a preclinical study designed to assess the inflammatory potential of **GA001**.



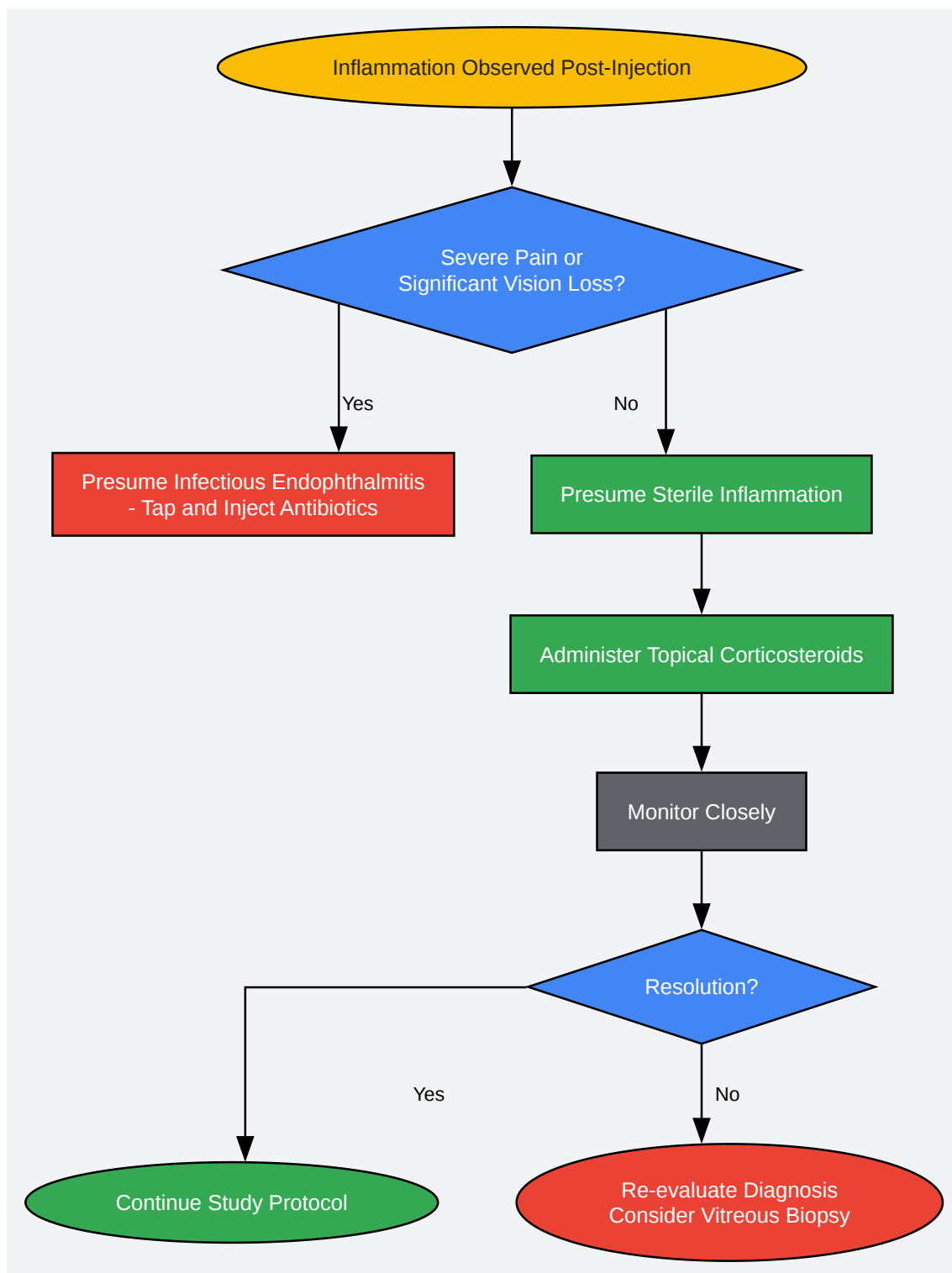
Preclinical Workflow for GA001 Inflammation Study

[Click to download full resolution via product page](#)

Caption: Workflow for assessing **GA001**-induced inflammation.

Troubleshooting Logic Tree for Post-Injection Inflammation

This diagram provides a logical decision-making process for an investigator faced with inflammation after a **GA001** injection.



Decision Tree for Post-GA001 Inflammation

[Click to download full resolution via product page](#)

Caption: Troubleshooting logic for post-injection inflammation.

Need Custom Synthesis?

BenchChem offers custom synthesis for rare earth carbides and specific isotopic labeling.

Email: info@benchchem.com or [Request Quote Online](#).

References

- 1. researchgate.net [researchgate.net]
- 2. Ocular Inflammation After Intravitreal Injections | Retinal Physician [retinalphysician.com]
- 3. jchs-medicine.uitm.edu.my [jchs-medicine.uitm.edu.my]
- 4. A pharmacologist looks at medical treatment in glaucoma--in retrospect and in prospect - PubMed [pubmed.ncbi.nlm.nih.gov]
- 5. Intravitreal Injection Therapy: Current Techniques and Supplemental Services - PMC [pmc.ncbi.nlm.nih.gov]
- 6. Mechanisms of sterile inflammation after intravitreal injection of antiangiogenic drugs: a narrative review - PubMed [pubmed.ncbi.nlm.nih.gov]
- 7. Mechanisms of sterile inflammation after intravitreal injection of antiangiogenic drugs: a narrative review - PMC [pmc.ncbi.nlm.nih.gov]
- 8. reviewofophthalmology.com [reviewofophthalmology.com]
- 9. mdpi.com [mdpi.com]
- 10. Complications of Intravitreal Injections | Retinal Physician [retinalphysician.com]
- To cite this document: BenchChem. [minimizing inflammation after intravitreal injection of GA001]. BenchChem, [2025]. [Online PDF]. Available at: [https://www.benchchem.com/product/b15580885#minimizing-inflammation-after-intravitreal-injection-of-ga001]

Disclaimer & Data Validity:

The information provided in this document is for Research Use Only (RUO) and is strictly not intended for diagnostic or therapeutic procedures. While BenchChem strives to provide accurate protocols, we make no warranties, express or implied, regarding the fitness of this product for every specific experimental setup.

Technical Support: The protocols provided are for reference purposes. Unsure if this reagent suits your experiment? [[Contact our Ph.D. Support Team for a compatibility check](#)]

Need Industrial/Bulk Grade? [Request Custom Synthesis Quote](#)

BenchChem

Our mission is to be the trusted global source of essential and advanced chemicals, empowering scientists and researchers to drive progress in science and industry.

Contact

Address: 3281 E Guasti Rd
Ontario, CA 91761, United States
Phone: (601) 213-4426
Email: info@benchchem.com