

managing high background signal in abdominal organs during Ga-68 gozetotide PET

Author: BenchChem Technical Support Team. **Date:** December 2025

Compound of Interest

Compound Name: Gallium Ga-68 gozetotide

Cat. No.: B10822203

[Get Quote](#)

Technical Support Center: Ga-68 Gozetotide PET Imaging

Welcome to the technical support center for Ga-68 gozetotide PET imaging. This resource is designed for researchers, scientists, and drug development professionals to provide troubleshooting guidance and frequently asked questions (FAQs) regarding high background signals in abdominal organs.

Frequently Asked Questions (FAQs)

Q1: What is Ga-68 gozetotide and why is high background in abdominal organs a concern?

A1: Gallium-68 (Ga-68) gozetotide, also known as Ga-68 PSMA-11, is a radiopharmaceutical agent used for Positron Emission Tomography (PET) imaging.^[1] It targets the Prostate-Specific Membrane Antigen (PSMA), a protein that is highly expressed on the surface of prostate cancer cells.^[1] High background signal in abdominal organs such as the liver, spleen, kidneys, and bowel can obscure or mimic cancerous lesions, potentially leading to misinterpretation of the scan results.^{[2][3]} Differentiating true pathological uptake from physiological background is crucial for accurate diagnosis and staging.

Q2: Which abdominal organs normally show physiological uptake of Ga-68 gozetotide?

A2: Physiological uptake of Ga-68 gozetotide is expected in several organs. The most intense activity is typically seen in the kidneys and urinary bladder due to the primary excretion route of the tracer.[2] Moderate uptake is commonly observed in the liver and spleen.[2] The small bowel, particularly the duodenum and jejunum, can also show notable physiological uptake.[2]

Q3: What are the primary causes of high background signal in the liver and spleen?

A3: The liver and spleen exhibit moderate physiological uptake of Ga-68 gozetotide. This is partly due to the biological function and blood flow characteristics of these organs. While the exact mechanisms are complex, factors such as the clearance pathways of the radiotracer and the presence of PSMA expression in these tissues contribute to the background signal. It's important to note that this uptake should generally be uniform.[4] Focal areas of intense uptake may be suspicious, though benign lesions like hemangiomas can also show variable uptake.[4]

Q4: Why is there often high signal in the intestines?

A4: The small intestine, especially the proximal parts like the duodenum, shows physiological PSMA expression which is thought to be involved in folate absorption.[4] This leads to physiological uptake of Ga-68 gozetotide. Bowel activity can be variable and sometimes intense, which may interfere with the assessment of nearby lymph nodes.

Troubleshooting High Background Signal

Q5: I am observing excessively high and diffuse liver uptake. What could be the cause and how can I troubleshoot this?

A5: Unusually high or heterogeneous liver uptake can be problematic. Here are some potential causes and troubleshooting steps:

- **Radiopharmaceutical Quality:** Ensure the radiopharmaceutical preparation has high radiochemical purity. Impurities or colloidal Ga-68 species can lead to altered biodistribution, including increased liver uptake.
- **Patient-Specific Factors:** Certain underlying liver conditions or medications could potentially alter the biodistribution. Review the patient's clinical history for any relevant factors.

- **Image Interpretation:** For selecting patients for Lutetium-177 vipivotide tetraxetan therapy, lesions are considered positive if their uptake is greater than the normal liver uptake.[\[5\]](#) Therefore, establishing a baseline for normal liver uptake is critical. While specific interventions to reduce liver uptake are not standard, ensuring proper radiopharmaceutical quality is the primary controllable factor.

Q6: The signal in the kidneys and urinary tract is obscuring the pelvic region. What can be done to mitigate this?

A6: High urinary activity is a common challenge due to the renal excretion of Ga-68 gozetotide. The following strategies can be employed:

- **Hydration:** Instruct patients to be well-hydrated by drinking a sufficient amount of water before the scan and to continue hydrating and voiding frequently after the tracer injection.[\[1\]](#)
[\[5\]](#)
- **Diuretics:** Administering a diuretic, such as furosemide (20 mg), at the time of the radiotracer injection can promote faster clearance of the tracer from the urinary system, reducing artifacts.[\[1\]](#)[\[6\]](#)[\[7\]](#)[\[8\]](#)
- **Voiding Before Scan:** It is crucial for the patient to void immediately before the image acquisition begins.[\[1\]](#)[\[9\]](#)
- **Imaging Protocol:** Start the PET scan from the mid-thighs and proceed upwards towards the skull. This approach images the pelvic region first, minimizing the impact of the bladder refilling during the scan.[\[1\]](#)

Q7: How can I reduce intense bowel activity that may be masking abdominal lymph nodes?

A7: High intestinal uptake can be challenging to manage. While there are no universally adopted, definitive methods, the following can be considered:

- **Delayed Imaging:** Performing additional imaging of the abdominal area at a later time point (e.g., 2-3 hours post-injection) may help.[\[10\]](#)[\[11\]](#) Over time, the tracer may clear from the bowel, improving the target-to-background ratio for pathological lesions. However, the short half-life of Ga-68 needs to be considered.

- **Bowel Preparation:** The use of oral laxatives or enemas has been discussed, but their usefulness in this context is considered controversial and not a standard part of the protocol. [\[5\]](#)
- **Fasting:** The impact of fasting is still under investigation. Some studies suggest that fasting does not significantly affect tumor uptake but may alter biodistribution in some abdominal organs.[\[12\]](#) For now, specific dietary restrictions are not a standard recommendation.[\[13\]](#)

Data and Protocols

Quantitative Data: Physiological Uptake in Abdominal Organs

The following table summarizes typical Standardized Uptake Values (SUV) for Ga-68 gozetotide in normal abdominal organs, which can serve as a reference for identifying unusually high background.

Organ	Mean SUVmax (\pm SD)	Mean SUVmean (\pm SD)	Reference
Liver	12.42 \pm 3.52	-	[1]
Spleen	12.70 \pm 6.75	-	[1]
Kidneys	58.26 \pm 17.17	-	[1]
Intestines	17.02 \pm 6.20	-	[1]

Note: SUV values can vary depending on the scanner, reconstruction parameters, and patient-specific factors.

Experimental Protocols

Protocol 1: Patient Preparation for Standard Ga-68 Gozetotide PET/CT

- **Patient Counseling:** Inform the patient about the procedure, including the need for intravenous injection and the duration of the scan.

- Hydration: Instruct the patient to drink at least 500 mL to 1 liter of water prior to the administration of Ga-68 gozetotide to ensure adequate hydration.[1][5]
- Fasting: No specific fasting requirements are generally needed.[13]
- Radiotracer Administration: Administer 111 MBq to 259 MBq (3 mCi to 7 mCi) of Ga-68 gozetotide as an intravenous bolus injection.[1]
- Post-Injection Hydration and Voiding: Encourage the patient to continue drinking water and to void frequently during the uptake period (first hour after injection) to reduce radiation exposure.[1]
- Uptake Time: The recommended uptake period is 50 to 100 minutes.[1]
- Final Voiding: The patient must empty their bladder immediately before being positioned on the scanner.[1][9]

Protocol 2: Mitigation of Urinary Tract Activity with a Diuretic

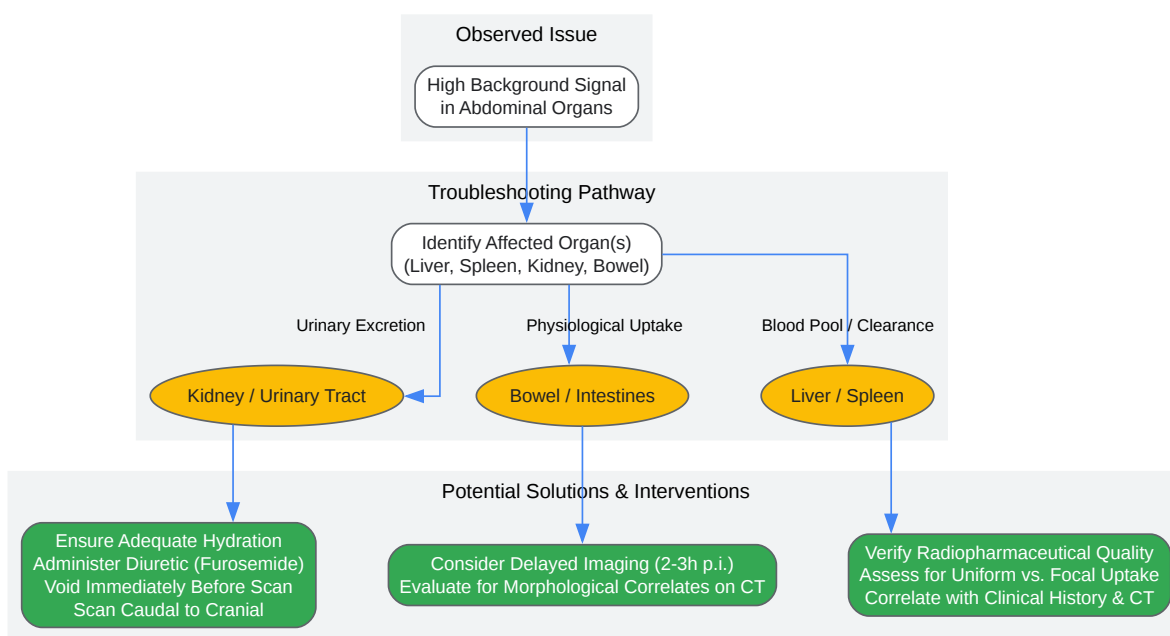
- Follow Standard Preparation: Adhere to all steps in the standard patient preparation protocol.
- Diuretic Administration: At the time of the Ga-68 gozetotide injection, administer 20 mg of furosemide intravenously, unless contraindicated.[6][8]
- Intravenous Hydration: To complement the diuretic, an intravenous infusion of 500 mL of 0.9% sodium chloride can be administered.[6]
- Imaging: Proceed with the standard uptake time and imaging protocol. This intervention has been shown to significantly reduce urinary activity and improve diagnostic confidence in the pelvic region.[7][8]

Protocol 3: Delayed Imaging for Clarification of Equivocal Findings

- Initial Scan: Perform the standard Ga-68 gozetotide PET/CT scan at 50-100 minutes post-injection.
- Identify Need for Delayed Imaging: If there are equivocal findings in the abdomen or pelvis due to high background from the bowel or urinary tract, consider delayed imaging.

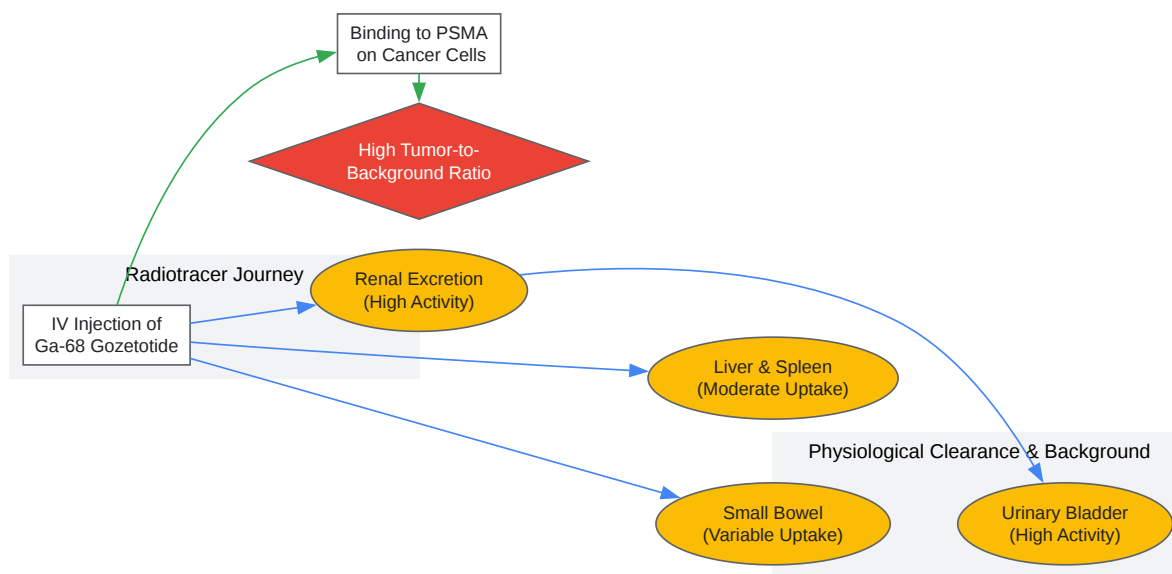
- Delayed Acquisition: Acquire additional PET/CT images of the specific region of interest at 120-180 minutes post-injection.[4][11]
- Image Analysis: Compare the uptake characteristics of the equivocal finding between the standard and delayed images. Persistent or increasing focal uptake is more suspicious for malignancy, whereas decreasing or clearing activity may indicate physiological processes. [11]

Visualizations



[Click to download full resolution via product page](#)

Caption: Troubleshooting workflow for high abdominal background signal.



[Click to download full resolution via product page](#)

Caption: Biodistribution pathway of Ga-68 gozetotide.

Need Custom Synthesis?

BenchChem offers custom synthesis for rare earth carbides and specific isotopic labeling.

Email: info@benchchem.com or [Request Quote Online](#).

References

- 1. accessdata.fda.gov [accessdata.fda.gov]
- 2. Cancers and Benign Processes on 68 Ga PSMA PET-CT Imaging Other than Prostate Cancer - PMC [[pmc.ncbi.nlm.nih.gov](https://pubmed.ncbi.nlm.nih.gov/)]
- 3. researchgate.net [researchgate.net]
- 4. Evaluation of [68 Ga]Ga-PSMA-I&T PET/CT with additional late scans of the pelvis in prostate-specific antigen recurrence using the PROMISE criteria - PMC [[pmc.ncbi.nlm.nih.gov](https://pubmed.ncbi.nlm.nih.gov/)]
- 5. illuccixhcp.com [illuccixhcp.com]

- 6. Comparison of Early Imaging and Imaging 60 min Post-Injection after Forced Diuresis with Furosemide in the Assessment of Local Recurrence in Prostate Cancer Patients with Biochemical Recurrence Referred for 68Ga-PSMA-11 PET/CT [mdpi.com]
- 7. Frusemide aids diagnostic interpretation of 68 Ga-PSMA positron emission tomography/CT in men with prostate cancer - PubMed [pubmed.ncbi.nlm.nih.gov]
- 8. Early Injection of Furosemide Increases Detection Rate of Local Recurrence in Prostate Cancer Patients with Biochemical Recurrence Referred for 68Ga-PSMA-11 PET/CT - PMC [pmc.ncbi.nlm.nih.gov]
- 9. apps.ausrad.com [apps.ausrad.com]
- 10. The image quality and feasibility of solitary delayed [68 Ga]Ga-PSMA-11 PET/CT using long field-of-view scanning in patients with prostate cancer - PMC [pmc.ncbi.nlm.nih.gov]
- 11. mdpi.com [mdpi.com]
- 12. newyorkoncology.com [newyorkoncology.com]
- 13. healthonline.washington.edu [healthonline.washington.edu]
- To cite this document: BenchChem. [managing high background signal in abdominal organs during Ga-68 gozetotide PET]. BenchChem, [2025]. [Online PDF]. Available at: [https://www.benchchem.com/product/b10822203#managing-high-background-signal-in-abdominal-organs-during-ga-68-gozetotide-pet]

Disclaimer & Data Validity:

The information provided in this document is for Research Use Only (RUO) and is strictly not intended for diagnostic or therapeutic procedures. While BenchChem strives to provide accurate protocols, we make no warranties, express or implied, regarding the fitness of this product for every specific experimental setup.

Technical Support: The protocols provided are for reference purposes. Unsure if this reagent suits your experiment? [[Contact our Ph.D. Support Team for a compatibility check](#)]

Need Industrial/Bulk Grade? [Request Custom Synthesis Quote](#)

BenchChem

Our mission is to be the trusted global source of essential and advanced chemicals, empowering scientists and researchers to drive progress in science and industry.

Contact

Address: 3281 E Guasti Rd

Ontario, CA 91761, United States

Phone: (601) 213-4426

Email: info@benchchem.com