

managing artifacts from adjacent organ activity in cardiac PET

Author: BenchChem Technical Support Team. **Date:** December 2025

Compound of Interest

Compound Name: Ammonia N-13

Cat. No.: B8666329

[Get Quote](#)

Technical Support Center: Managing Artifacts in Cardiac PET

This technical support center provides troubleshooting guides and frequently asked questions (FAQs) to help researchers, scientists, and drug development professionals manage artifacts arising from adjacent organ activity in cardiac Positron Emission Tomography (PET).

Troubleshooting Guides

Issue 1: Artificially Altered Tracer Uptake in the Inferior Myocardial Wall

Q: My cardiac PET images show an artificially increased or decreased tracer uptake in the inferior wall of the left ventricle. What could be the cause and how can I troubleshoot this?

A: This is a common artifact often caused by spillover from high tracer activity in the liver or gastrointestinal (GI) tract. Here's how you can address this issue:

Possible Causes and Solutions:

Cause	Solution
Liver Spillover: High tracer uptake in the liver, adjacent to the inferior myocardial wall, can lead to an overestimation of tracer concentration in that region due to the partial volume effect and photon scatter.[1]	1. Post-processing Correction: Implement spillover correction algorithms during image reconstruction. Factor analysis-based methods have been shown to be effective. 2. Patient Positioning: If possible, adjust patient positioning to maximize the distance between the heart and the liver.
Gastrointestinal (GI) Tract Activity: Uptake of the radiotracer (commonly 18F-FDG) in the stomach or intestines can interfere with the assessment of the adjacent myocardial wall.	1. Patient Preparation: For 18F-FDG studies, ensure the patient has followed a strict low-carbohydrate, high-fat diet to suppress physiological glucose uptake in the myocardium and surrounding tissues.[2][3][4][5] 2. Delayed Imaging: In some cases, delaying the scan can allow for clearance of the tracer from the GI tract.
Misregistration between PET and CT scans: In PET/CT, a mismatch in the alignment of the PET emission data and the CT-based attenuation map, often due to respiratory motion, can lead to incorrect attenuation correction and artificially altered uptake values in the inferior wall.[6][7][8][9][10]	1. Respiratory Gating: Use respiratory gating techniques to acquire PET and CT data at the same phase of the respiratory cycle. 2. Image Co-registration: Manually or automatically co-register the PET and CT images before reconstruction.[7]

Issue 2: Blurring and Motion Artifacts in Cardiac PET Images

Q: My cardiac PET images appear blurry, and I suspect motion artifacts. What are the common sources of motion and what are the correction strategies?

A: Motion is a significant source of image degradation in cardiac PET. It can be caused by cardiac and respiratory cycles, as well as patient movement.

Sources of Motion and Correction Strategies:

Motion Source	Correction Strategy
Cardiac Motion: The continuous contraction and relaxation of the heart muscle causes blurring of the PET images.	1. Electrocardiogram (ECG) Gating: Synchronize PET data acquisition with the patient's ECG signal to reconstruct images at specific phases of the cardiac cycle (e.g., end-diastole).[11]
Respiratory Motion: Breathing motion causes the heart to move within the chest, leading to image blurring and misregistration with the attenuation correction map.[12][13][14]	1. Respiratory Gating: Use a respiratory tracking device to acquire PET data only during a specific phase of the breathing cycle (e.g., end-expiration). 2. Motion-Corrected Image Reconstruction: Incorporate motion models derived from other imaging modalities like MRI or from the PET data itself into the reconstruction algorithm.[15]
Patient Body Motion: Voluntary or involuntary patient movement during the scan can lead to significant image artifacts.	1. Patient Comfort and Instruction: Ensure the patient is comfortable and well-instructed to remain still during the acquisition. 2. Motion Detection and Correction: Some systems have software that can detect and correct for patient motion during post-processing.[15]

Frequently Asked Questions (FAQs)

Q1: What is the impact of adjacent organ activity on the quantitative accuracy of myocardial blood flow (MBF) measurements?

A1: Spillover from adjacent organs with high tracer uptake, particularly the liver, can lead to an overestimation of tracer concentration in the myocardium, which in turn can affect the accuracy of MBF quantification. Correction for this spillover is crucial for obtaining reliable MBF values. [16][17][18] Studies have shown that without correction, the washout constant (k_2) in kinetic modeling can be overestimated by over 200% in regions affected by liver spillover.

Q2: How prevalent are misregistration artifacts in cardiac PET/CT studies?

A2: Misregistration between PET and CT scans is a common issue. Studies have reported that artifactual defects due to misregistration can occur in a significant percentage of patients, with some studies indicating a prevalence of up to 40%.[\[6\]](#)[\[9\]](#)[\[10\]](#) The frequency and severity of these artifacts are influenced by factors such as patient breathing patterns and the specific imaging protocol used.[\[6\]](#)

Q3: What are the best practices for patient preparation to minimize artifacts from adjacent organ activity in ¹⁸F-FDG cardiac PET?

A3: To minimize physiological ¹⁸F-FDG uptake in the myocardium and surrounding tissues, including the liver and GI tract, a strict dietary preparation is recommended. This typically involves a high-fat, low-carbohydrate diet for at least 24 to 72 hours prior to the scan, followed by a fasting period.[\[19\]](#)[\[2\]](#)[\[3\]](#)[\[4\]](#)[\[5\]](#) This dietary manipulation shifts myocardial metabolism from glucose to free fatty acids, thereby reducing background ¹⁸F-FDG uptake.

Quantitative Data Summary

The following tables summarize quantitative data on the impact of artifacts and the effectiveness of correction methods.

Table 1: Impact of PET/CT Misregistration on Myocardial Perfusion Imaging

Study	Number of Patients	Prevalence of Misregistration Artifacts	Key Finding
Gould et al. (2007)	259	40%	Misregistration of >6 mm resulted in significant artifactual perfusion defects. [6] [9]
Martínez-Möller et al. (2007)	28	21.4% (defects >10% of LV)	Manual realignment of PET and CT data led to the disappearance of large apparent perfusion defects. [10]

Table 2: Efficacy of Dietary Intervention for Myocardial 18F-FDG Uptake Suppression

Study	Dietary Protocol	Fasting Group (Avg. SUVmax)	Diet Group (Avg. SUVmax)	p-value
Fan et al. (2009)	High-fat, very-low-carbohydrate, protein-permitted (VHFLCPP) meal 3-6 hours before injection.	8.8 ± 5.7	3.9 ± 3.6	< 0.00001
Cheng et al. (2013)	72-hour high-fat, high-protein, very-low-carbohydrate (HFHPVLC) diet.	(24-hour diet group had a higher indeterminate rate)	Significantly lower indeterminate rate for cardiac sarcoidosis diagnosis.	< 0.001

Table 3: Quantitative Impact of Motion Correction on Cardiac PET Imaging

Study	Correction Method	Parameter	Improvement with Correction
Nekolla et al. (2020)	MR-based cardiac and respiratory motion correction	Myocardial Contrast-to-Noise Ratio (CNR)	Up to 20.1% increase in the septal wall. [14]
Nekolla et al. (2020)	MR-based cardiac and respiratory motion correction	Apparent Myocardial Wall Thickness	Up to 18.9% decrease in the inferior wall. [14]
Rubeaux et al. (2021)	MR-guided motion-corrected reconstruction	Myocardium-to-blood pool contrast	143% average increase.

Experimental Protocols

Protocol 1: High-Fat, Low-Carbohydrate Diet for Myocardial ^{18}F -FDG Uptake Suppression

Objective: To suppress physiological glucose uptake in the myocardium to enhance the detection of pathological ^{18}F -FDG uptake.

Methodology:

- Dietary Restriction (48-72 hours prior to imaging):
 - Instruct the patient to adhere to a high-fat, very-low-carbohydrate diet.
 - Allowed foods: Meats, poultry, fish, eggs, cheese, butter, oils, and non-starchy vegetables.
 - Prohibited foods: Sugars, bread, pasta, rice, grains, fruits, and starchy vegetables.[\[4\]](#)
- Fasting (12-18 hours prior to imaging):
 - The patient should fast for at least 12 hours before the ^{18}F -FDG injection. Water is permitted.
- Pre-injection Meal (optional, 3-6 hours prior to imaging):
 - Some protocols include a high-fat meal 3-6 hours before the tracer injection to further promote fatty acid metabolism.[\[19\]](#)
- Verification:
 - Confirm patient adherence to the diet and fasting instructions before proceeding with the scan.

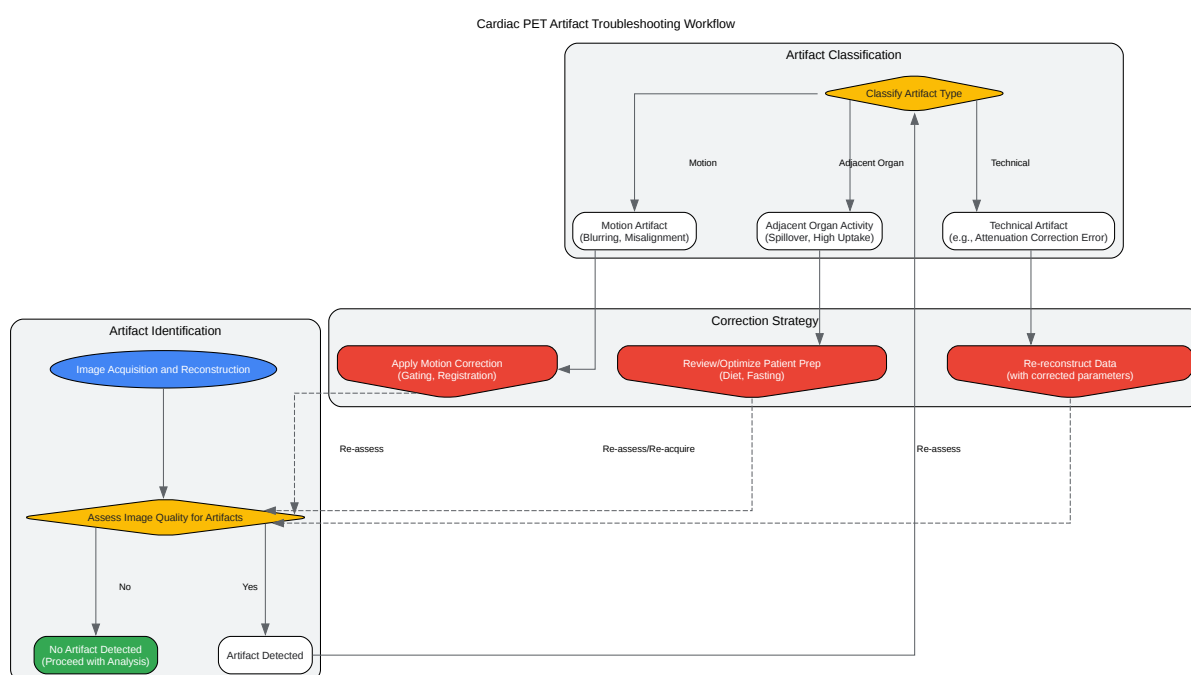
Protocol 2: Respiratory Gating for Cardiac PET/CT

Objective: To minimize artifacts caused by respiratory motion by acquiring PET and CT data at a consistent phase of the respiratory cycle.

Methodology:

- Patient Setup:
 - Place a respiratory monitoring device (e.g., a pressure-sensitive belt or an infrared camera tracking a reflective marker) on the patient.
- Respiratory Signal Acquisition:
 - Record the patient's respiratory waveform for several cycles to determine a stable pattern.
- Gating Window Selection:
 - Define a "gating window" at a specific phase of the respiratory cycle, typically at end-expiration, where motion is minimal.
- Gated CT Acquisition:
 - Acquire the CT scan for attenuation correction only when the respiratory signal is within the defined gating window.
- Gated PET Acquisition:
 - Acquire the PET emission data in list mode, which records the arrival time of each event along with the corresponding respiratory signal.
- Data Rebinning and Reconstruction:
 - During post-processing, select and rebin the list-mode data that falls within the chosen gating window.
 - Reconstruct the gated PET data using the gated CT for attenuation correction.

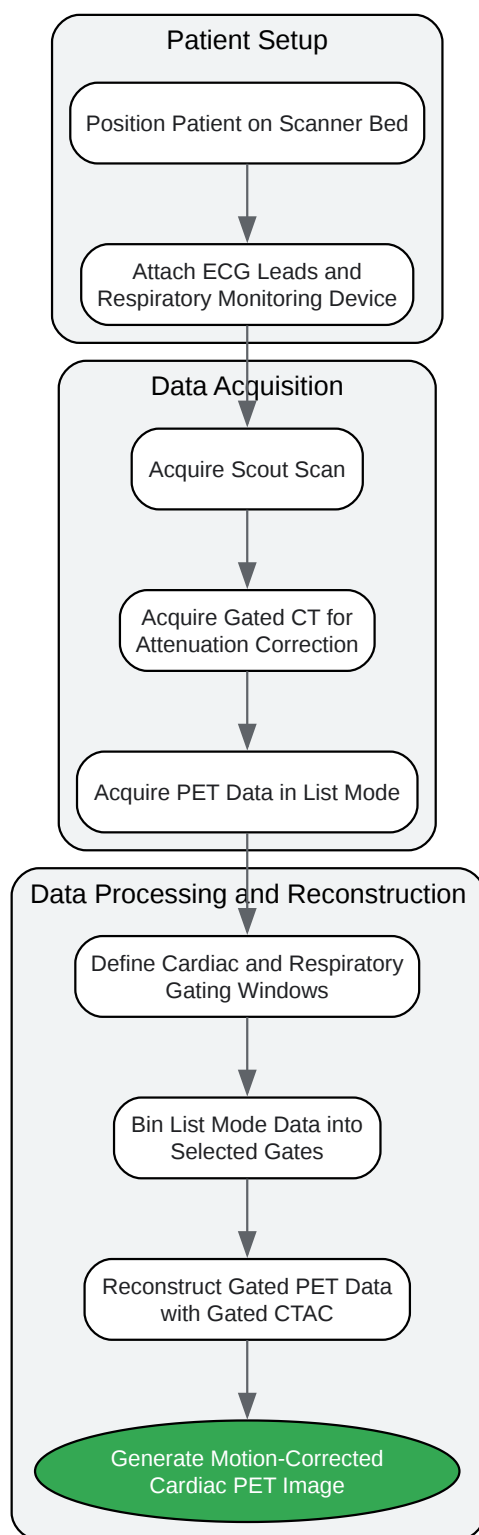
Visualizations



[Click to download full resolution via product page](#)

Caption: Workflow for identifying, classifying, and correcting common artifacts in cardiac PET imaging.

Gated Cardiac PET Acquisition Workflow



[Click to download full resolution via product page](#)

Need Custom Synthesis?

BenchChem offers custom synthesis for rare earth carbides and specific isotopic labeling.

Email: info@benchchem.com or [Request Quote Online](#).

References

- 1. researchgate.net [researchgate.net]
- 2. Suppression of Myocardial 18F-FDG Uptake Through Prolonged High-Fat, High-Protein, and Very-Low-Carbohydrate Diet Before FDG-PET/CT for Evaluation of Patients With Suspected Cardiac Sarcoidosis - PubMed [pubmed.ncbi.nlm.nih.gov]
- 3. Patient preparation for cardiac fluorine-18 fluorodeoxyglucose positron emission tomography imaging of inflammation - PMC [pmc.ncbi.nlm.nih.gov]
- 4. Dietary Preparation for FDG PET Imaging to Assess Myocardial Inflammation | McGovern Medical School [med.uth.edu]
- 5. Utility of high fat and low carbohydrate diet in suppressing myocardial FDG uptake - PubMed [pubmed.ncbi.nlm.nih.gov]
- 6. Frequent Diagnostic Errors in Cardiac PET/CT Due to Misregistration of CT Attenuation and Emission PET Images: A Definitive Analysis of Causes, Consequences, and Corrections | Journal of Nuclear Medicine [jnm.snmjournals.org]
- 7. asnc.org [asnc.org]
- 8. Cardiac PET and PET/CT: Artifacts and Tracers | Thoracic Key [thoracickey.com]
- 9. researchgate.net [researchgate.net]
- 10. Artifacts from misaligned CT in cardiac perfusion PET/CT studies: frequency, effects, and potential solutions - PubMed [pubmed.ncbi.nlm.nih.gov]
- 11. Gating approaches in cardiac PET imaging - PMC [pmc.ncbi.nlm.nih.gov]
- 12. discovery.ucl.ac.uk [discovery.ucl.ac.uk]
- 13. researchgate.net [researchgate.net]
- 14. MR-based cardiac and respiratory motion correction of PET: Application to static and dynamic cardiac 18F-FDG imaging - PMC [pmc.ncbi.nlm.nih.gov]

- 15. Extended MRI-based PET motion correction for cardiac PET/MRI - PMC [pmc.ncbi.nlm.nih.gov]
- 16. Improved spillover correction model to quantify myocardial blood flow by 11C-acetate PET: comparison with 15O-H₂O PET - PubMed [pubmed.ncbi.nlm.nih.gov]
- 17. researchgate.net [researchgate.net]
- 18. Improved spillover correction model to quantify myocardial blood flow by 11C-acetate PET: comparison with 15O-H₂O PET | springermedicine.com [springermedicine.com]
- 19. Suppression of myocardial 18F-FDG uptake by preparing patients with a high-fat, low-carbohydrate diet - PubMed [pubmed.ncbi.nlm.nih.gov]
- To cite this document: BenchChem. [managing artifacts from adjacent organ activity in cardiac PET]. BenchChem, [2025]. [Online PDF]. Available at: [https://www.benchchem.com/product/b8666329#managing-artifacts-from-adjacent-organ-activity-in-cardiac-pet]

Disclaimer & Data Validity:

The information provided in this document is for Research Use Only (RUO) and is strictly not intended for diagnostic or therapeutic procedures. While BenchChem strives to provide accurate protocols, we make no warranties, express or implied, regarding the fitness of this product for every specific experimental setup.

Technical Support: The protocols provided are for reference purposes. Unsure if this reagent suits your experiment? [[Contact our Ph.D. Support Team for a compatibility check](#)]

Need Industrial/Bulk Grade? [Request Custom Synthesis Quote](#)

BenchChem

Our mission is to be the trusted global source of essential and advanced chemicals, empowering scientists and researchers to drive progress in science and industry.

Contact

Address: 3281 E Guasti Rd
Ontario, CA 91761, United States
Phone: (601) 213-4426
Email: info@benchchem.com