

impact of CT-based attenuation correction on Rb-82 quantification

Author: BenchChem Technical Support Team. **Date:** December 2025

Compound of Interest

Compound Name: *Rubidium-82*

Cat. No.: *B1236357*

[Get Quote](#)

Technical Support Center: Rb-82 PET/CT Quantification

This technical support center provides troubleshooting guidance and answers to frequently asked questions regarding the impact of CT-based attenuation correction (AC) on **Rubidium-82** (Rb-82) PET quantification. It is intended for researchers, scientists, and drug development professionals.

Frequently Asked Questions (FAQs)

Q1: What is the purpose of CT-based attenuation correction in Rb-82 PET imaging?

A1: CT-based attenuation correction is a crucial step in PET imaging that corrects for the absorption and scattering of annihilation photons within the patient's body.^{[1][2][3]} This correction is essential for accurate quantification of Rb-82 tracer uptake, which is used to measure myocardial blood flow (MBF) and diagnose coronary artery disease.^{[4][5]} Without proper attenuation correction, the resulting PET images would show artificially reduced tracer concentration in deeper tissues, leading to inaccurate quantitative analysis.^[6]

Q2: What are the most common artifacts related to CT-based attenuation correction in Rb-82 PET studies?

A2: The most frequently encountered artifacts include:

- **Misalignment Artifacts:** These occur due to differences in patient position, including respiratory and cardiac motion, between the CT and PET scans.^{[6][7]} This is a significant issue because the CT scan is a quick snapshot, while the PET scan is an average over several minutes.^{[6][8]}
- **Truncation Artifacts:** These happen when the patient's body extends beyond the CT field of view (FOV), leading to an incomplete attenuation map.^[9] Consequently, the PET signal in the truncated regions is underestimated.^[9]
- **Metal Artifacts:** Metallic implants (e.g., pacemakers, surgical clips) can cause severe streaking artifacts on the CT image, which then propagate into the attenuation-corrected PET image, leading to inaccurate quantification of tracer uptake in the surrounding tissues.^[10]
- **Contrast Media Artifacts:** The presence of oral or intravenous contrast agents during the CT scan can lead to an overestimation of tissue attenuation, resulting in artificially increased tracer uptake values in the PET image.

Q3: How does misalignment between PET and CT scans affect Rb-82 quantification?

A3: Misalignment between the PET and CT data is a primary source of error in quantitative Rb-82 PET studies.^[11] If the CT-derived attenuation map is not correctly aligned with the PET emission data, it can lead to either an underestimation or overestimation of tracer activity. For instance, if lung tissue (low attenuation) on the CT image overlays the myocardial wall on the PET image, it will result in an underestimation of Rb-82 uptake, potentially creating an artificial perfusion defect.^[6] Conversely, if dense tissue from the CT scan overlaps with a region of lower density on the PET scan, it can lead to an overcorrection and artificially high uptake values. Studies have shown that even small misalignments can lead to significant quantitative errors.^[1]

Q4: Can patient motion during the scan impact the accuracy of CT-based attenuation correction?

A4: Yes, patient motion is a significant challenge. Motion during the PET acquisition can cause blurring of the emission data. More critically, if the patient moves between the CT and PET scans, or even during the PET scan itself, it will cause a mismatch between the anatomy in the emission and transmission (CT) data.^[12] This misalignment directly leads to incorrect

attenuation correction and can introduce substantial errors, as high as 200%, in myocardial blood flow measurements.[12]

Troubleshooting Guides

Issue 1: Suspected Misalignment Artifacts in Reconstructed Images

Symptoms:

- Appearance of perfusion defects in areas not corresponding to a specific vascular territory.
- Unusually high or low tracer uptake at the interface of different tissues (e.g., myocardium and lung).
- Visual mismatch between the CT and PET fused images.

Troubleshooting Steps:

- Visual Inspection: Carefully review the fused PET/CT images to identify any obvious misalignment between the anatomical structures in the CT and the tracer distribution in the PET.
- Software-based Realignment: Utilize available software tools to perform a manual or automated rigid registration of the CT attenuation map to the PET emission data.[13] Studies have shown that automated alignment can improve diagnostic accuracy compared to no alignment or manual alignment.[13]
- Re-reconstruction: After realignment, reconstruct the PET data using the corrected attenuation map.
- Quality Control: Implement a routine quality control procedure to check for PET/CT alignment before clinical interpretation.

Issue 2: Perfusion Defects in the Inferior or Anterior Wall

Symptoms:

- A perfusion defect is observed in the inferior or anterior wall of the myocardium.
- The defect may appear more pronounced in the stress images.

Potential Cause: Myocardial Creep

Pharmacological stress agents like regadenoson can cause a downward displacement of the heart, known as "myocardial creep".^[7] If a single CT scan acquired at rest is used for attenuation correction of both rest and stress PET images, this can lead to a significant misalignment during the stress phase, potentially creating an artificial perfusion defect.

Troubleshooting and Prevention:

- **Acquire Separate CT Scans:** Whenever possible, acquire separate low-dose CT scans for attenuation correction immediately before both the rest and stress PET acquisitions.^[14]
- **Frame-wise Attenuation Correction:** For dynamic imaging, some research has explored frame-wise co-registration of the PET data with the CT. However, one study concluded that for myocardial creep during regadenoson-induced stress, frame-wise alignment did not result in significantly different myocardial blood flow measurements, suggesting it may not always be necessary.^[7]
- **Image Registration:** If separate CTs are not feasible, careful registration of the stress PET data to the rest CT is critical.

Quantitative Data Summary

The following tables summarize the impact of CT-based attenuation correction on Rb-82 PET quantification based on published data.

Table 1: Impact of Misalignment on Myocardial Segmental Counts

Myocardial Segment	Average Difference (CT vs. TCT) with >5mm Misalignment (Before Correction)	Average Difference (CT vs. TCT) with >5mm Misalignment (After Correction)
Segment 7 (Anteroseptal)	49% (CT < TCT)	65% (CT < TCT)
Global Average (Largest Change in 1 Patient)	18% (CT < TCT)	24% (CT < TCT)
TCT: Transmission Computed Tomography. Data synthesized from a study comparing CT-based and transmission-based attenuation correction.[1]		

Table 2: Diagnostic Accuracy of Rb-82 PET/CT with Different Alignment Strategies

Alignment Strategy	Area Under the ROC Curve
No Alignment Correction	0.81 ± 0.03
Manual Correction	0.83 ± 0.03
Automated Correction	0.85 ± 0.03
Targeted Automated Correction	0.87 ± 0.03
ROC: Receiver Operating Characteristic. Data from a study evaluating the impact of automated registration on detecting coronary artery disease.[13]	

Experimental Protocols

Protocol 1: Standard Rest/Stress Rb-82 PET/CT Myocardial Perfusion Imaging

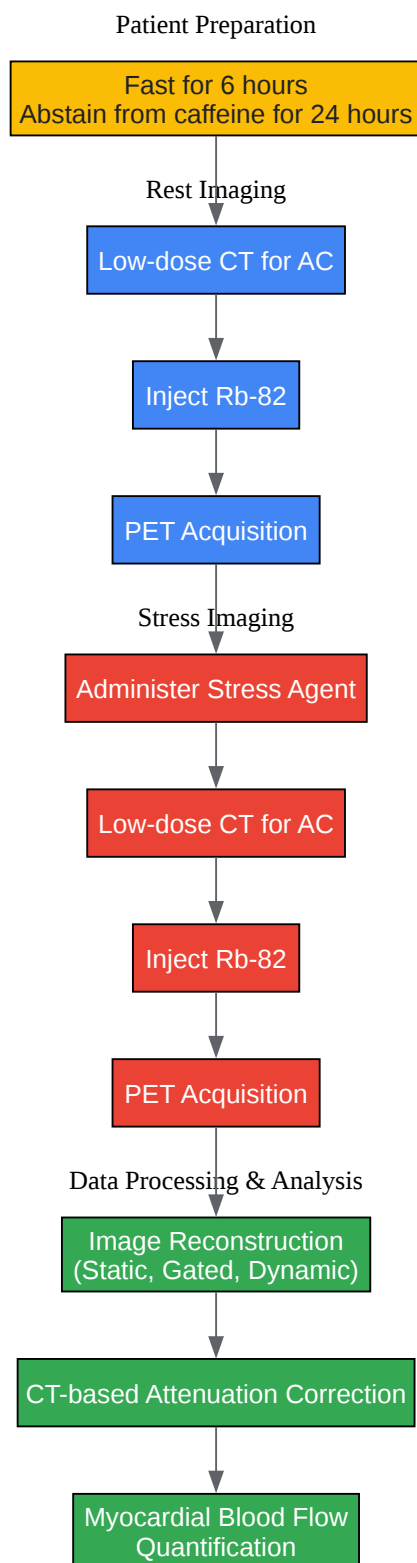
- Patient Preparation: Patients should fast for at least 6 hours and abstain from caffeine for 24 hours prior to the scan.[15]

- Rest Imaging:
 - A low-dose CT scan is acquired for attenuation correction (e.g., 120 kVp, 10-35 mA).[4]
[14]
 - Inject 925 to 1850 MBq (25 to 50 mCi) of Rb-82.[4]
 - Simultaneously, begin a 6-minute list-mode PET acquisition.[4]
- Stress Imaging:
 - Administer a pharmacological stress agent (e.g., adenosine or regadenoson).[16]
 - Acquire a second low-dose CT scan for stress attenuation correction.[4]
 - Inject a second dose of Rb-82 (e.g., 1110-1295 MBq).[1]
 - Begin a second PET acquisition.
- Image Reconstruction:
 - Reconstruct the list-mode data into static, gated, and dynamic images.[16]
 - Apply attenuation correction using the corresponding CT data.[16]
 - Additional corrections for scatter, randoms, and dead time should be applied.

Protocol 2: Quality Control for PET/CT Scanner

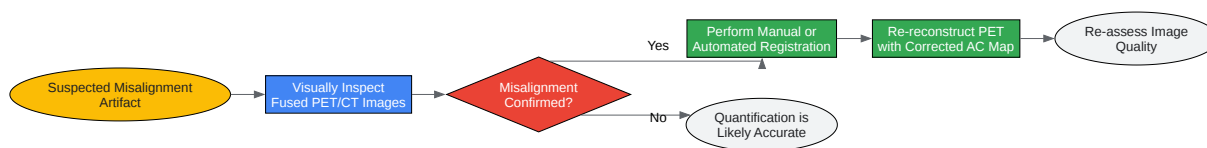
- Daily Quality Control: Perform daily QC checks as recommended by the scanner manufacturer. This typically includes a blank scan and a scan with a uniform phantom (e.g., a ^{68}Ge source) to check for detector performance and stability.[2][17]
- CT Quality Control: Perform regular CT quality control, including checks for noise, uniformity, and linearity using a CT phantom.[17]
- PET/CT Co-registration Accuracy: Periodically verify the spatial alignment between the PET and CT systems using a phantom with markers visible in both modalities.

Visualizations



[Click to download full resolution via product page](#)

Caption: Workflow for Rb-82 PET/CT Myocardial Perfusion Imaging.



[Click to download full resolution via product page](#)

Need Custom Synthesis?

BenchChem offers custom synthesis for rare earth carbides and specific isotopic labeling.

Email: info@benchchem.com or [Request Quote Online](#).

References

- 1. jnm.snmjournals.org [jnm.snmjournals.org]
- 2. efomp.org [efomp.org]
- 3. Story of Rubidium-82 and Advantages for Myocardial Perfusion PET Imaging - PMC [pmc.ncbi.nlm.nih.gov]
- 4. Automated Quantitative ^{82}Rb 3D PET/CT Myocardial Perfusion Imaging: Normal Limits and Correlation with Invasive Coronary Angiography - PMC [pmc.ncbi.nlm.nih.gov]
- 5. Quantitative myocardial blood flow with Rubidium-82 PET: a clinical perspective - PMC [pmc.ncbi.nlm.nih.gov]
- 6. Cardiac PET and PET/CT: Artifacts and Tracers | Thoracic Key [thoracickey.com]
- 7. No need for frame-wise attenuation correction in dynamic Rubidium-82 PET for myocardial blood flow quantification - PubMed [pubmed.ncbi.nlm.nih.gov]
- 8. jnm.snmjournals.org [jnm.snmjournals.org]
- 9. repositorio.ipl.pt [repositorio.ipl.pt]

- 10. Pitfalls on PET/CT due to artifacts and instrumentation - PMC [pmc.ncbi.nlm.nih.gov]
- 11. jnm.snmjournals.org [jnm.snmjournals.org]
- 12. jnm.snmjournals.org [jnm.snmjournals.org]
- 13. Automatic registration of misaligned CT attenuation correction maps in Rb-82 PET/CT improves detection of angiographically significant coronary artery disease - PubMed [pubmed.ncbi.nlm.nih.gov]
- 14. tech.snmjournals.org [tech.snmjournals.org]
- 15. jnm.snmjournals.org [jnm.snmjournals.org]
- 16. tijdschriftvoornucleairegeneeskunde.nl [tijdschriftvoornucleairegeneeskunde.nl]
- 17. na.eventscloud.com [na.eventscloud.com]
- To cite this document: BenchChem. [impact of CT-based attenuation correction on Rb-82 quantification]. BenchChem, [2025]. [Online PDF]. Available at: [https://www.benchchem.com/product/b1236357#impact-of-ct-based-attenuation-correction-on-rb-82-quantification]

Disclaimer & Data Validity:

The information provided in this document is for Research Use Only (RUO) and is strictly not intended for diagnostic or therapeutic procedures. While BenchChem strives to provide accurate protocols, we make no warranties, express or implied, regarding the fitness of this product for every specific experimental setup.

Technical Support: The protocols provided are for reference purposes. Unsure if this reagent suits your experiment? [[Contact our Ph.D. Support Team for a compatibility check](#)]

Need Industrial/Bulk Grade? [Request Custom Synthesis Quote](#)

BenchChem

Our mission is to be the trusted global source of essential and advanced chemicals, empowering scientists and researchers to drive progress in science and industry.

Contact

Address: 3281 E Guasti Rd
Ontario, CA 91761, United States
Phone: (601) 213-4426
Email: info@benchchem.com

