

how to confirm successful induction of tumors with DMH

Author: BenchChem Technical Support Team. **Date:** December 2025

Compound of Interest

Compound Name: 1,2-Dimethylhydrazine
dihydrochloride

Cat. No.: B128209

[Get Quote](#)

Technical Support Center: DMH-Induced Tumor Models

This technical support center provides troubleshooting guides and frequently asked questions (FAQs) to assist researchers in successfully inducing and confirming tumors using 1,2-dimethylhydrazine (DMH).

Troubleshooting Guide

This guide addresses common issues encountered during DMH-induced tumorigenesis experiments.

Issue	Potential Cause(s)	Recommended Action(s)
Low or no tumor incidence	<ul style="list-style-type: none">- Incorrect DMH dosage: Dosages that are too low may not be sufficient to induce tumors.- Inappropriate animal strain: Susceptibility to DMH-induced carcinogenesis is strain-dependent.- Insufficient duration of experiment: The latency period for tumor development can be long.- Improper DMH preparation or storage: DMH is unstable and can degrade if not handled correctly.	<ul style="list-style-type: none">- Verify DMH dosage: The effective dosage can range from 2 to 200 mg/kg body weight, with 15-20 mg/kg being common for weekly injections.[1][2] - Select an appropriate animal strain: Certain mouse strains, like ICR/Ha, are highly susceptible, while others, like C57BL/6Ha, are resistant.[3] Sprague-Dawley and Wistar rats are also commonly used.[4][5] - Ensure adequate experimental duration: Preneoplastic lesions like aberrant crypt foci (ACF) can appear as early as 8-12 weeks, but tumor formation can take up to 40 weeks or longer.[6] - Follow proper DMH handling: Dissolve DMH in a suitable vehicle like 1 mM EDTA (pH 6.5-7.0) immediately before use.[7][8]
High animal mortality	<ul style="list-style-type: none">- DMH toxicity: DMH can cause severe toxic reactions in organs like the liver.[9] - Incorrect injection technique: Improper subcutaneous or intraperitoneal injection can lead to complications.	<ul style="list-style-type: none">- Optimize DMH dose: If high mortality is observed, consider reducing the DMH concentration or the frequency of administration.- Refine injection technique: Ensure injections are administered correctly to minimize tissue damage and stress to the animals.

Difficulty in identifying tumors	<ul style="list-style-type: none">- Small tumor size: Early-stage tumors may not be grossly visible.- Location of tumors: Tumors are most frequently found in the distal colon but can also occur in the small intestine.^{[1][7]}	<ul style="list-style-type: none">- Perform thorough macroscopic examination: Carefully inspect the entire colon and small intestine for any visible abnormalities, such as dome-shaped lesions.^[10]- Utilize staining techniques for ACF: Methylene blue staining of the colonic mucosa can help visualize preneoplastic aberrant crypt foci (ACF).^[11]- Conduct histopathological analysis: Microscopic examination of tissue sections is the definitive method for confirming the presence of dysplastic and neoplastic changes.^{[4][12]}
Inconsistent tumor characteristics	<ul style="list-style-type: none">- Biological variability: Individual animal responses to carcinogens can vary.- Differences in experimental conditions: Variations in diet, housing, or other environmental factors can influence tumorigenesis.	<ul style="list-style-type: none">- Increase sample size: Using a larger number of animals can help account for biological variability.- Standardize experimental conditions: Maintain consistent diet, housing, and handling procedures for all animals in the study.

Frequently Asked Questions (FAQs)

1. What are the first signs of successful tumor induction after DMH administration?

The earliest microscopic signs are the formation of aberrant crypt foci (ACF), which are considered preneoplastic lesions.^{[5][13]} Macroscopically, you may observe abdominal distension and the presence of small, dome-shaped lesions in the colon upon necropsy.^{[5][10]}

2. How can I definitively confirm the presence of tumors?

Histopathological examination is the gold standard for confirming tumorigenesis.^[4] This involves collecting colon tissue, processing it for histology, and staining with hematoxylin and eosin (H&E). A trained pathologist can then identify features of dysplasia, adenoma, and adenocarcinoma.^{[4][7][12]}

3. What are the typical histological features of DMH-induced colon tumors?

DMH-induced tumors often progress through stages, starting with epithelial dysplasia, characterized by abnormal cell growth and loss of normal tissue architecture.^{[5][6]} This can develop into adenomas (benign tumors) and then adenocarcinomas (malignant tumors).^[1] Histological features of adenocarcinoma include disorganized crypt structure, infiltration of cancer cells into the muscle wall, and in some cases, mucin production (mucinous adenocarcinoma).^{[4][7]}

4. Are there any molecular markers to confirm successful tumor induction?

Yes, several molecular markers can be used for confirmation:

- Ki-67: Increased expression of this proliferation marker is commonly observed in DMH-induced dysplastic tissues and tumors.^[5]
- β -catenin: Nuclear accumulation of β -catenin, a key component of the Wnt signaling pathway, is a frequent event in DMH-induced colon tumors.^{[10][14]}
- Apoptotic markers: Changes in the expression of apoptosis-related proteins, such as caspases, can also be indicative of tumorigenesis.^[1]
- Inflammatory markers: Increased expression of inflammatory markers like COX-2 can be seen in the colonic mucosa during DMH-induced carcinogenesis.^{[6][15]}

5. What is a typical timeline for tumor development with DMH?

The timeline for tumor development can vary depending on the animal species and strain, DMH dose, and administration frequency. Generally, you can expect the following:

- Aberrant Crypt Foci (ACF): Can be observed as early as 8-12 weeks after the initial DMH injection.[\[6\]](#)
- Adenomas and Adenocarcinomas: Typically develop after a longer latency period, often ranging from 3 months to 40 weeks.[\[6\]](#)[\[8\]](#)[\[16\]](#)

Quantitative Data Summary

The following tables summarize quantitative data from representative studies on DMH-induced tumorigenesis.

Table 1: Tumor Incidence and Multiplicity

Animal Model	DMH Dosage and Schedule	Duration	Tumor Incidence	Tumor Multiplicity (mean ± SD)	Reference
Female Mice	Not specified	Not specified	83% with visible tumors	Not specified	[1]
C57BL/6J Mice	20 mg/kg DMH (single dose) + 3 cycles of 3% DSS	10 weeks	90.9% (dysplasia/cancer)	Not specified	[10]
Sprague-Dawley Rats	30 mg/kg DMH weekly	Not specified	Not specified	Not specified	[4]
Wistar Rats	20 mg/kg DMH weekly	7 weeks (euthanized at 11 or 17 weeks)	100% with ACF	Not specified	[5]

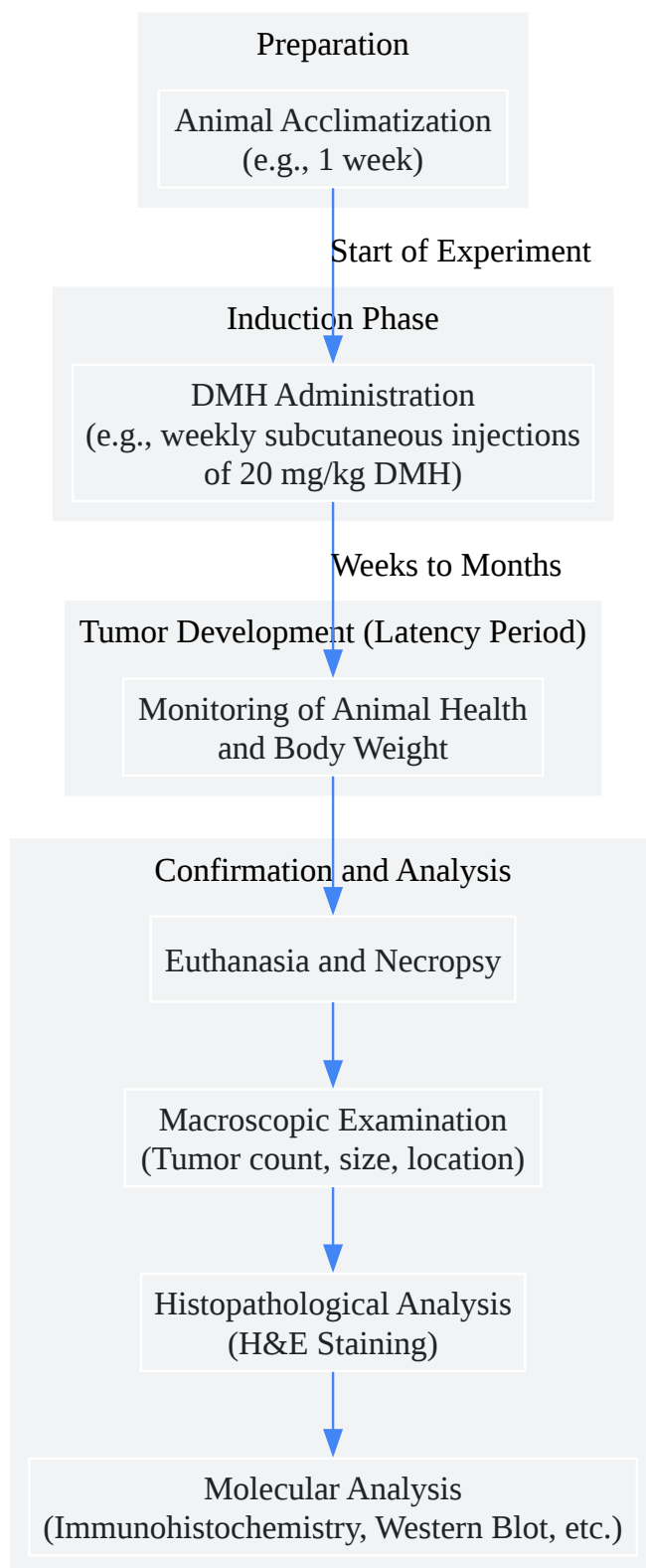
Table 2: Lesion Size

Animal Model	DMH Dosage and Schedule	Duration	Lesion Type	Size Range	Reference
C57BL/6J Mice	20 mg/kg DMH (single dose) + 3 cycles of 3% DSS	10 weeks	Gross lesions	2 to 4 mm	[10]

Experimental Protocols & Visualizations

Experimental Workflow for DMH-Induced Colon Carcinogenesis

This diagram outlines the typical experimental workflow for inducing colon cancer in a rodent model using DMH.

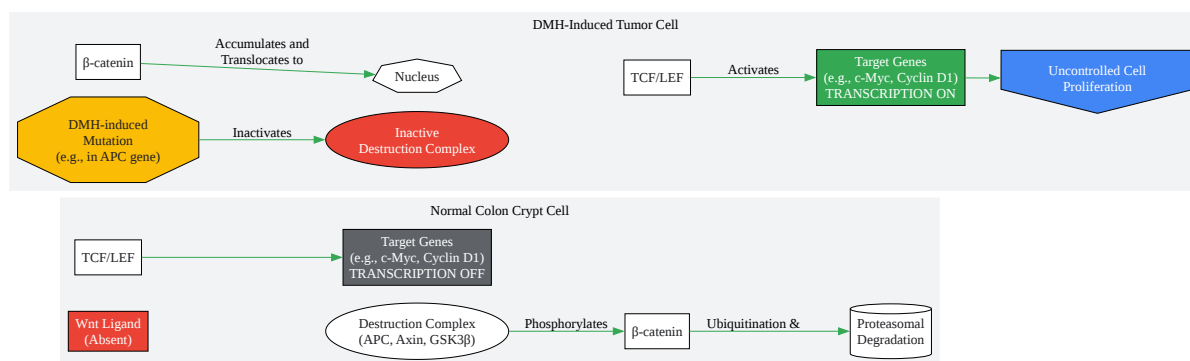


[Click to download full resolution via product page](#)

Caption: Experimental workflow for DMH-induced tumorigenesis.

Simplified Wnt/ β -catenin Signaling Pathway in DMH-Induced Colon Cancer

DMH-induced mutations can lead to the constitutive activation of the Wnt/ β -catenin signaling pathway, a critical driver of colorectal cancer.



[Click to download full resolution via product page](#)

Caption: Wnt/ β -catenin pathway in colon cancer.

Need Custom Synthesis?

BenchChem offers custom synthesis for rare earth carbides and specific isotopic labeling.

Email: info@benchchem.com or [Request Quote Online](#).

References

- 1. Biochemical and molecular aspects of 1,2-dimethylhydrazine (DMH)-induced colon carcinogenesis: a review - PMC [pmc.ncbi.nlm.nih.gov]
- 2. mdpi.com [mdpi.com]
- 3. academic.oup.com [academic.oup.com]
- 4. researchgate.net [researchgate.net]
- 5. An Integrative Approach to Characterize the Early Phases of Dimethylhydrazine-Induced Colorectal Carcinogenesis in the Rat - PMC [pmc.ncbi.nlm.nih.gov]
- 6. journal.waocp.org [journal.waocp.org]
- 7. academic.oup.com [academic.oup.com]
- 8. researchgate.net [researchgate.net]
- 9. Evaluation of Dimethylhydrazine Induced Tumours in Mice as a Model System for Colorectal Cancer - PMC [pmc.ncbi.nlm.nih.gov]
- 10. A novel mouse model for colitis-associated colon carcinogenesis induced by 1,2-dimethylhydrazine and dextran sulfate sodium - PMC [pmc.ncbi.nlm.nih.gov]
- 11. researchgate.net [researchgate.net]
- 12. researchgate.net [researchgate.net]
- 13. clinmedjournals.org [clinmedjournals.org]
- 14. researchgate.net [researchgate.net]
- 15. journal.waocp.org [journal.waocp.org]
- 16. Induction of Colon Cancer in Mice with 1,2-Dimethylhydrazine - PubMed [pubmed.ncbi.nlm.nih.gov]
- To cite this document: BenchChem. [how to confirm successful induction of tumors with DMH]. BenchChem, [2025]. [Online PDF]. Available at: [https://www.benchchem.com/product/b128209#how-to-confirm-successful-induction-of-tumors-with-dmh]

Disclaimer & Data Validity:

The information provided in this document is for Research Use Only (RUO) and is strictly not intended for diagnostic or therapeutic procedures. While BenchChem strives to provide

accurate protocols, we make no warranties, express or implied, regarding the fitness of this product for every specific experimental setup.

Technical Support: The protocols provided are for reference purposes. Unsure if this reagent suits your experiment? [[Contact our Ph.D. Support Team for a compatibility check](#)]

Need Industrial/Bulk Grade? [Request Custom Synthesis Quote](#)

BenchChem

Our mission is to be the trusted global source of essential and advanced chemicals, empowering scientists and researchers to drive progress in science and industry.

Contact

Address: 3281 E Guasti Rd
Ontario, CA 91761, United States
Phone: (601) 213-4426
Email: info@benchchem.com