

historical perspective on calcium pyrophosphate deposition disease

Author: BenchChem Technical Support Team. **Date:** December 2025

Compound of Interest

Compound Name: Calcium pyrophosphate

Cat. No.: B051889

[Get Quote](#)

An In-depth Technical Guide to the Historical Perspective of **Calcium Pyrophosphate** Deposition Disease

For Researchers, Scientists, and Drug Development Professionals

Abstract

Calcium Pyrophosphate Deposition (CPPD) disease, a crystal arthropathy characterized by the accumulation of **calcium pyrophosphate** (CPP) crystals in articular and periarticular tissues, has evolved from a clinical curiosity to a well-defined metabolic disease. This technical guide provides a comprehensive historical perspective on CPPD, detailing the seminal discoveries, the evolution of diagnostic and therapeutic strategies, and the key molecular insights that have shaped our current understanding. It is intended to serve as a valuable resource for researchers, scientists, and professionals involved in the development of novel diagnostics and therapeutics for this prevalent and often debilitating condition.

Early Observations and the Dawn of a New Disease Entity

The story of CPPD begins long before its molecular basis was understood. Early case descriptions in the 19th and early 20th centuries noted the presence of cartilage calcification, termed "chondrocalcinosis," though its clinical significance remained elusive.

- 1842: Roderick McLeod is credited with the first potential observation of chondrocalcinosis, identifying a "white powdery substance" on articular cartilage during autopsies.[1]
- 1873: Robert Adams provided a more detailed account of chondrocalcinosis in a patient with chronic rheumatic disease, observing calcification of the knee meniscus at autopsy.[1]
- 1922-1927: The advent of radiography allowed for the in vivo visualization of these calcifications. Jacques Calvé, Marcel Galland, and Felix Mandl were among the first to document radiographic evidence of calcifications in intervertebral discs and articular cartilage.[1][2]

These early observations laid the groundwork for recognizing chondrocalcinosis as a distinct clinical finding, though it was often misdiagnosed as other forms of arthritis like osteoarthritis or rheumatoid arthritis.[1][2]

The Era of Discovery: Identifying the Culprit Crystal

The mid-20th century marked a turning point in the understanding of this arthropathy, with the identification of the specific crystalline culprit and the coining of terminology that remains in use today.

A pivotal moment came in 1962, when Daniel McCarty and his colleagues published their seminal work. They identified non-urate, weakly positively birefringent, rhomboid-shaped crystals in the synovial fluid of patients presenting with acute, gout-like inflammatory arthritis.[1][3][4] This condition was aptly named "pseudogout" due to its clinical mimicry of gout.[1][4]

Contemporaneously, in 1960-1962, Dusan Zitnan and Stefan Sitaj described familial clusters of chondrocalcinosis, which they termed "chondrocalcinosis articularis," highlighting a potential genetic component to the disease.[1][4]

The distinct clinical and crystallographic findings led to a proliferation of terminology. To bring clarity, the umbrella term **Calcium Pyrophosphate** Deposition (CPPD) disease was introduced in 1975 to encompass the diverse clinical manifestations associated with CPP crystal deposition.[1] In 1969, the term "pyrophosphate arthropathy" was introduced to specifically describe the structural joint damage seen in CPPD.[1]

Table 1: Evolution of CPPD Nomenclature

Year(s)	Key Term(s)	Description	Key Researchers/Events
1920s	Chondrocalcinosis	Radiographic observation of cartilage calcification.	Calvé, Galland, Mandl
1960-1962	Chondrocalcinosis Articularis	Description of familial cases of chondrocalcinosis.	Zitnan and Sitaj
1962	Pseudogout	Acute, gout-like arthritis caused by non-urate crystals.	McCarty et al.
1969	Pyrophosphate Arthropathy	Structural joint changes associated with CPPD.	
1975	Calcium Pyrophosphate Deposition (CPPD) Disease	Overarching term for all clinical manifestations of CPP crystal deposition.	Various investigators

Unraveling the Pathophysiology: From Observation to Molecular Mechanisms

The discovery of CPP crystals spurred intensive research into their formation and pro-inflammatory effects.

The Biochemical Basis of CPP Crystal Formation

Early research focused on the composition of the crystals, identifying them as **calcium pyrophosphate** dihydrate ($\text{Ca}_2\text{P}_2\text{O}_7 \cdot 2\text{H}_2\text{O}$). It was established that an excess of extracellular inorganic pyrophosphate (PPI) is a key factor in CPP crystal formation.^{[5][6]} PPI is a potent

inhibitor of hydroxyapatite formation, but in excess, it combines with calcium to form CPP crystals.[\[6\]](#)[\[7\]](#)

Genetic Insights: The Role of ANKH and Other Genes

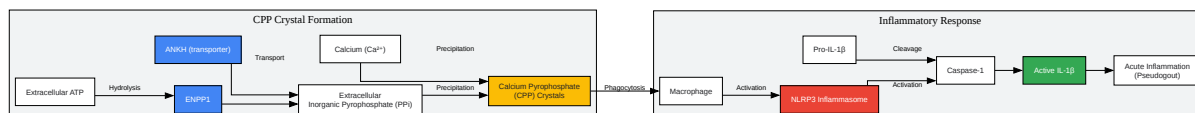
A major breakthrough in understanding the genetic basis of CPPD came in 2001-2002 with the discovery of mutations in the ANKH gene in familial forms of the disease.[\[1\]](#) The ANKH protein is a transmembrane protein that transports inorganic pyrophosphate (PPi) from the intracellular to the extracellular space.[\[5\]](#)[\[8\]](#)[\[9\]](#) Gain-of-function mutations in ANKH lead to increased extracellular PPi levels, predisposing to CPP crystal formation.[\[5\]](#)[\[8\]](#)

More recently, a large-scale genome-wide association study (GWAS) identified two additional genes, RNF144B and ENPP1, associated with CPPD in both European and African American populations.[\[10\]](#)[\[11\]](#) ENPP1 (ectonucleotide pyrophosphatase/phosphodiesterase 1) is an enzyme that generates extracellular PPi from ATP.[\[6\]](#)[\[9\]](#)

The Inflammatory Cascade: NLRP3 Inflammasome Activation

The inflammatory manifestations of CPPD, such as acute pseudogout, are driven by the innate immune system's response to CPP crystals. A key player in this process is the NLRP3 inflammasome. CPP crystals are recognized as a danger signal by macrophages and other immune cells, leading to the assembly and activation of the NLRP3 inflammasome.[\[4\]](#)[\[6\]](#)[\[12\]](#) This, in turn, activates caspase-1, which cleaves pro-interleukin-1 β (pro-IL-1 β) into its active, pro-inflammatory form, IL-1 β .[\[4\]](#)[\[6\]](#)[\[12\]](#) IL-1 β is a potent cytokine that drives the acute inflammatory response seen in pseudogout.

Diagram 1: Simplified Signaling Pathway of CPP Crystal Formation and Inflammation



[Click to download full resolution via product page](#)

Caption: Overview of CPP crystal formation and the subsequent inflammatory cascade.

Evolution of Diagnostic Methodologies

The diagnosis of CPPD has evolved from reliance on clinical suspicion and conventional radiography to more sensitive and specific techniques.

Synovial Fluid Analysis: The Gold Standard

The identification of CPP crystals in synovial fluid by compensated polarized light microscopy remains the gold standard for the definitive diagnosis of CPPD.^[13]

Experimental Protocol: Compensated Polarized Light Microscopy for CPP Crystal Identification

- **Sample Preparation:** A drop of fresh synovial fluid is placed on a clean glass slide and covered with a coverslip. The edges of the coverslip may be sealed with nail polish to prevent drying.
- **Microscope Setup:** A polarizing microscope equipped with a first-order red compensator is used.
- **Crystal Identification:** The slide is examined under the microscope. CPP crystals are typically rhomboid or rod-shaped and exhibit weak positive birefringence. This means they appear blue when their long axis is parallel to the axis of the red compensator and yellow when perpendicular.

Imaging Techniques

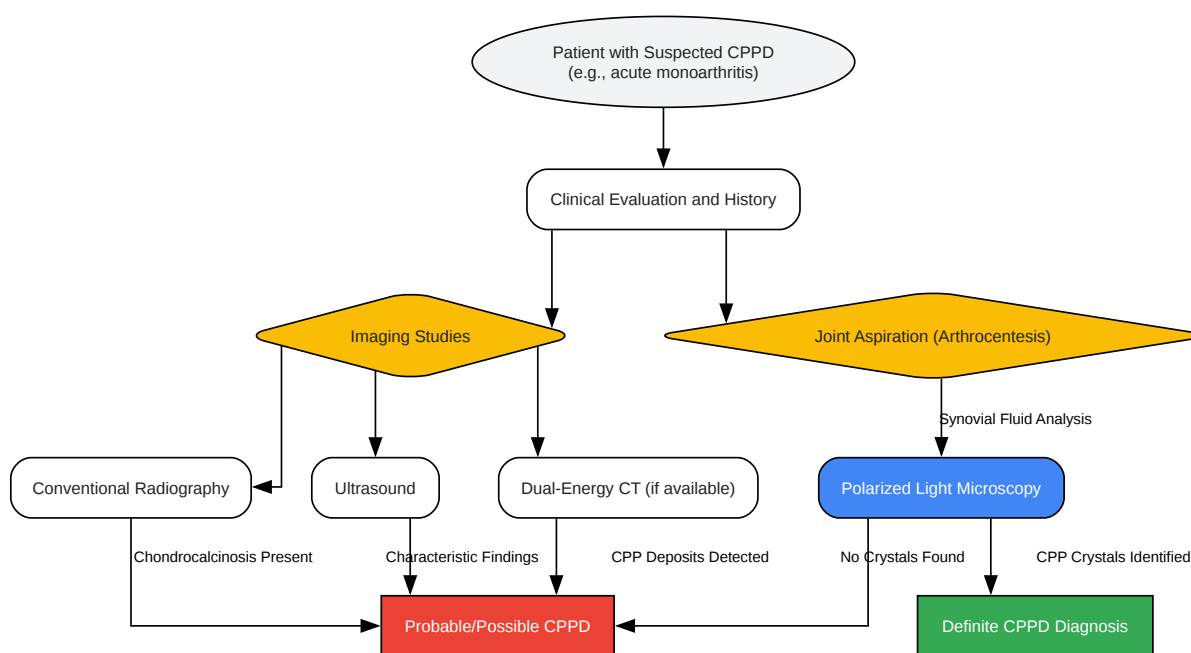
Imaging plays a crucial role in the diagnosis and assessment of CPPD.

- **Conventional Radiography:** The earliest imaging modality used, radiography can detect chondrocalcinosis, the calcification of hyaline and fibrocartilage.^{[2][13]} While specific, it has low sensitivity, especially in early disease.^[14]
- **Ultrasound (US):** In recent years, ultrasound has emerged as a highly sensitive tool for detecting CPP crystal deposition.^{[1][2][14]} The OMERACT (Outcome Measures in Rheumatology) group has developed and validated definitions for the sonographic features of CPPD.^[5]
- **Dual-Energy Computed Tomography (DECT):** DECT is a more advanced imaging technique that can differentiate between different types of crystals, such as monosodium urate and CPP crystals.^{[2][3]}

Table 2: Comparison of Diagnostic Modalities for CPPD

Modality	Key Findings	Advantages	Disadvantages
Polarized Light Microscopy	Rhomboid-shaped, weakly positively birefringent crystals	Gold standard for definitive diagnosis	Invasive (requires joint aspiration), operator dependent
Conventional Radiography	Chondrocalcinosis (linear or punctate calcifications in cartilage)	Widely available, low cost	Low sensitivity in early disease
Ultrasound (US)	Hyperechoic linear deposits in hyaline cartilage, "sparkling" spots in fibrocartilage	High sensitivity, non-invasive, real-time assessment	Operator dependent, lower specificity than microscopy
Dual-Energy CT (DECT)	Color-coded mapping to differentiate CPP from urate crystals	High sensitivity and specificity, non-invasive	Higher cost and radiation exposure, limited availability

Diagram 2: Diagnostic Workflow for Suspected CPPD



[Click to download full resolution via product page](#)

Caption: A typical workflow for the diagnosis of CPPD.

Historical Progression of Therapeutic Strategies

Treatment for CPPD has historically been, and largely remains, symptomatic, aimed at controlling inflammation and pain. There are currently no approved therapies that dissolve or prevent CPP crystal formation.

Management of Acute Flares (Pseudogout)

The management of acute pseudogout mirrors that of acute gout.

- **Non-Steroidal Anti-Inflammatory Drugs (NSAIDs):** These have been a mainstay of treatment for decades to reduce pain and inflammation.
- **Colchicine:** Used for both acute flares and prophylaxis, colchicine's anti-inflammatory effects are well-established in crystal arthropathies.
- **Corticosteroids:** Intra-articular or systemic corticosteroids are highly effective in controlling the severe inflammation of an acute attack.

Prophylaxis and Management of Chronic CPPD

For patients with recurrent flares or chronic inflammatory arthritis, prophylactic strategies are employed.

- **Low-dose Colchicine:** Daily low-dose colchicine has been shown to reduce the frequency of acute flares.^[15]
- **Methotrexate:** The use of methotrexate, a disease-modifying antirheumatic drug (DMARD), has been explored for chronic inflammatory CPPD, with mixed results in clinical trials.^{[1][15]}

The Dawn of Biologic Therapies

More recently, a deeper understanding of the role of IL-1 β in the pathogenesis of CPPD has led to the investigation of biologic therapies that target this cytokine.

- **Anakinra:** An IL-1 receptor antagonist, anakinra has shown efficacy in treating refractory acute and chronic CPPD in case series and small studies.^{[1][2][15]}
- **Tocilizumab:** An IL-6 receptor inhibitor, has also been investigated in pilot studies.^[1]

Table 3: Summary of Key Clinical Trials and Studies in CPPD Treatment

Treatment	Study Design	Patient Population	Key Outcomes
Colchicine (Prophylaxis)	Observational studies	Patients with recurrent pseudogout	Reduction in the frequency of acute attacks.
Methotrexate	Randomized controlled trials	Patients with chronic or recurrent CPPD	Mixed results; some studies showed no significant benefit over placebo.
Anakinra	Systematic reviews of case series and observational studies	Patients with refractory acute or chronic CPPD	High rates of clinical response, particularly in acute, refractory cases.

Future Directions and Unmet Needs

Despite significant progress, several unmet needs remain in the field of CPPD.

- **Disease-Modifying Therapies:** The development of agents that can dissolve existing CPP crystals or prevent their formation is the ultimate goal. The identification of genes like ENPP1 may provide novel therapeutic targets.
- **Improved Diagnostics:** While advanced imaging has improved detection, there is still a need for more accessible, non-invasive, and highly specific diagnostic tools.
- **Standardized Outcome Measures:** The development of validated and standardized outcome measures for clinical trials is crucial for advancing therapeutic research.

Conclusion

The historical journey of **Calcium Pyrophosphate** Deposition disease is a testament to the power of clinical observation, scientific inquiry, and technological advancement. From the initial descriptions of chondrocalcinosis to the elucidation of its molecular and genetic underpinnings, our understanding of CPPD has grown immensely. This historical perspective provides a crucial foundation for the researchers, scientists, and drug development professionals who are

working to translate these fundamental discoveries into novel and effective therapies for patients suffering from this common and often debilitating disease.

Need Custom Synthesis?

BenchChem offers custom synthesis for rare earth carbides and specific isotopic labeling.

Email: info@benchchem.com or [Request Quote Online](#).

References

- 1. Development and validation of an OMERACT ultrasound scoring system for the extent of calcium pyrophosphate crystal deposition at the joint level and patient level - PubMed [pubmed.ncbi.nlm.nih.gov]
- 2. researchgate.net [researchgate.net]
- 3. dottoressafigus.it [dottoressafigus.it]
- 4. invivogen.com [invivogen.com]
- 5. CPPD — Omeract-us [omeract-us.org]
- 6. Frontiers | Inflammatory Potential of Four Different Phases of Calcium Pyrophosphate Relies on NF-κB Activation and MAPK Pathways [frontiersin.org]
- 7. Activation of NLRP3 inflammasome by crystalline structures via cell surface contact - PMC [pmc.ncbi.nlm.nih.gov]
- 8. air.unimi.it [air.unimi.it]
- 9. Definition and Reliability Assessment of Elementary Ultrasonographic Findings in Calcium Pyrophosphate Deposition Disease: A Study by the OMERACT Calcium Pyrophosphate Deposition Disease Ultrasound Subtask Force | The Journal of Rheumatology [jrheum.org]
- 10. ISRCTN [isrctn.com]
- 11. Discovery of new genetic links offers potential for the prevention and treatment of a common form of inflammatory arthritis. — Advanced Pain Diagnostic and Solutions [advancedpaindiagnosticandsolutions.com]
- 12. CPPD Crystals [alab.com.pl]
- 13. Methotrexate in chronic-recurrent calcium pyrophosphate deposition disease: no significant effect in a randomized crossover trial | springermedizin.de [springermedizin.de]

- 14. Anakinra compared to prednisone in the treatment of acute CPPD crystal arthritis: A randomized controlled double-blinded pilot study - PubMed [pubmed.ncbi.nlm.nih.gov]
- 15. mdpi.com [mdpi.com]
- To cite this document: BenchChem. [historical perspective on calcium pyrophosphate deposition disease]. BenchChem, [2025]. [Online PDF]. Available at: [https://www.benchchem.com/product/b051889#historical-perspective-on-calcium-pyrophosphate-deposition-disease]

Disclaimer & Data Validity:

The information provided in this document is for Research Use Only (RUO) and is strictly not intended for diagnostic or therapeutic procedures. While BenchChem strives to provide accurate protocols, we make no warranties, express or implied, regarding the fitness of this product for every specific experimental setup.

Technical Support: The protocols provided are for reference purposes. Unsure if this reagent suits your experiment? [[Contact our Ph.D. Support Team for a compatibility check](#)]

Need Industrial/Bulk Grade? [Request Custom Synthesis Quote](#)

BenchChem

Our mission is to be the trusted global source of essential and advanced chemicals, empowering scientists and researchers to drive progress in science and industry.

Contact

Address: 3281 E Guasti Rd

Ontario, CA 91761, United States

Phone: (601) 213-4426

Email: info@benchchem.com