

addressing age-related variations in Tc-99m medronate scan quality

Author: BenchChem Technical Support Team. **Date:** December 2025

Compound of Interest

Compound Name: *Technetium TC-99M medronate*

Cat. No.: *B1242282*

[Get Quote](#)

Technical Support Center: Tc-99m Medronate Scans

This technical support center provides troubleshooting guides and frequently asked questions (FAQs) to address common issues encountered during Tc-99m medronate bone scans, with a specific focus on age-related variations in scan quality.

Troubleshooting Guides

This section provides a systematic approach to identifying and resolving common problems encountered during Tc-99m medronate scans.

Issue 1: Poor Image Quality in Geriatric Patients

Symptom: Low bone-to-soft tissue contrast, diffusely increased soft tissue uptake, and poor visualization of skeletal structures in elderly patients.

Root Cause Analysis and Solutions:

An inverse linear correlation has been observed between a patient's age and the quality of their bone scan.^[1] This is often attributable to age-related decline in renal function, which is crucial for clearing the radiotracer from soft tissues.^{[2][3]} Dehydration can further impede this clearance.^[3]

Troubleshooting Workflow: Geriatric Image Quality



[Click to download full resolution via product page](#)

Caption: Workflow for troubleshooting poor scan quality in elderly patients.

Experimental Protocol: Delayed 24-Hour Imaging

- Patient Preparation: Following the standard injection of Tc-99m medronate, instruct the patient on a hydration schedule, encouraging them to drink plenty of fluids and void frequently over the next 24 hours to aid soft tissue clearance.[2][3]
- Image Acquisition: At 24 hours post-injection, acquire whole-body or static images as per the standard protocol.
- Considerations: Be aware that due to the 6-hour half-life of Tc-99m, only about 6.25% of the initial activity will remain, requiring a longer acquisition time to achieve adequate image counts.[3]

Issue 2: Suboptimal Image Quality or Artifacts in Pediatric Scans

Symptom: Motion artifacts (blurring), low image counts, or images that are difficult to interpret in pediatric patients.

Root Cause Analysis and Solutions:

Troubleshooting Workflow: Pediatric Image Quality



[Click to download full resolution via product page](#)

Data Presentation: Pediatric Dosage and Acquisition Parameters

Age/Weight Category	Recommended Tc-99m Activity (MBq/kg)	Minimum Activity (MBq)	Key Acquisition Considerations
Neonates & Infants	7-11	9.25	Swaddling, feeding before scan, use of fast acquisition technology. [3] [4] [6]
Children (1-5 years)	7-11	As per guidelines	Psychological preparation, immobilization devices, potential for sedation. [3] [5]
Children (>5 years)	As per weight-based guidelines	As per guidelines	Clear communication, distraction techniques, optimized CT parameters in SPECT/CT. [4] [5]

Note: Dosing should always follow established guidelines, such as those from the European Association of Nuclear Medicine (EANM) or local institutional protocols.

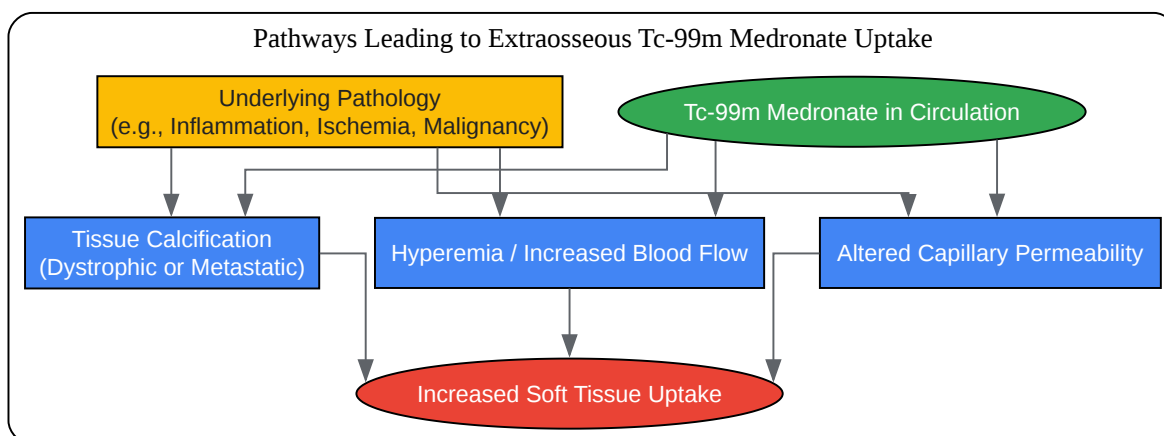
Issue 3: Non-specific Soft Tissue Uptake

Symptom: Accumulation of Tc-99m medronate in non-osseous tissues, which can be focal or diffuse.

Root Cause Analysis and Solutions:

Extraosseous uptake of Tc-99m medronate is a known phenomenon and can be caused by a wide range of conditions.[\[7\]](#)[\[8\]](#)[\[9\]](#) The underlying mechanisms include increased blood flow, altered capillary permeability, and the presence of calcium deposits in soft tissues.[\[7\]](#)[\[10\]](#) In patients with chronic kidney disease, this is often correlated with hyperphosphatemia.[\[11\]](#)

Signaling Pathway: Mechanisms of Soft Tissue Uptake



[Click to download full resolution via product page](#)

Caption: Mechanisms contributing to soft tissue uptake of Tc-99m medronate.

Frequently Asked Questions (FAQs)

Q1: Why is image quality often reduced in elderly patients undergoing a Tc-99m medronate bone scan?

A1: Reduced image quality in elderly patients is often due to age-related decreases in renal function.[2] The kidneys are responsible for clearing the Tc-99m medronate tracer from the soft tissues. When renal function is impaired, the tracer is cleared more slowly, resulting in higher background activity and lower contrast between bone and soft tissue.[3] Dehydration can also contribute to this issue.[3]

Q2: What is the "flare phenomenon" and how does it affect scan interpretation?

A2: The "flare phenomenon" can occur in patients undergoing chemotherapy for bone metastases. It refers to an apparent worsening of lesions on a bone scan 2 to 6 months after starting treatment, with new lesions appearing or existing ones looking larger or more intense. [3] This is thought to represent a healing response in the bone, with increased bone turnover and sclerosis of prior lesions, rather than disease progression.[3]

Q3: What causes unexpected uptake in the stomach, thyroid, and salivary glands?

A3: This pattern of uptake is typically caused by "free pertechnetate," which results from poor labeling of the medronate (MDP) with Tc-99m.[3][12] If the radiopharmaceutical is not prepared correctly or is used more than 4-5 hours after preparation, the Tc-99m can dissociate and will be taken up by tissues that normally accumulate pertechnetate.[13]

Q4: How should Tc-99m medronate dosage be adjusted for pediatric patients?

A4: Pediatric doses should be calculated based on the patient's body weight to minimize radiation exposure while ensuring diagnostic image quality.[4] The standard adult dose is not appropriate for children. For example, a common guideline for children under 5 is 7 to 11 MBq per kg.[3] It is crucial to follow established protocols, such as those provided by the EANM, and to use the lowest possible dose that provides a diagnostic image (the ALARA principle).[5]

Q5: What are the most common patient-related artifacts and how can they be avoided?

A5: The most common patient-related artifacts are caused by urine contamination and motion.
[14]

- **Urine Contamination:** Can create "hot spots" that may obscure or be mistaken for pathology. This can be avoided by encouraging the patient to void immediately before imaging and carefully checking for any contamination on the patient's skin or clothing.[15][16]
- **Motion Artifacts:** Cause blurring and loss of detail, particularly problematic in pediatric and frail elderly patients. This can be minimized through clear communication, making the patient comfortable, using immobilization devices, and, in some pediatric cases, sedation.[4][5]

Q6: Can a recent CT scan with iodinated contrast affect a Tc-99m medronate scan?

A6: While iodinated contrast agents used in CT scans can pose a risk of contrast-induced nephropathy, particularly in patients with pre-existing renal impairment, Tc-99m medronate itself has minimal nephrotoxicity at diagnostic doses.[17][18] The primary concern would be if the iodinated contrast significantly worsens renal function, which would then delay the clearance of the Tc-99m medronate, potentially affecting image quality as described in Q1. Proper hydration is recommended for both procedures.[17]

Need Custom Synthesis?

BenchChem offers custom synthesis for rare earth carbides and specific isotopic labeling.

Email: info@benchchem.com or [Request Quote Online](#).

References

- 1. The effect of age on the quality of bone scans using technetium-99m pyrophosphate - PubMed [pubmed.ncbi.nlm.nih.gov]
- 2. Technetium tc 99m medronate (intravenous route) - Side effects & uses - Mayo Clinic [mayoclinic.org]
- 3. Bone Scan - StatPearls - NCBI Bookshelf [ncbi.nlm.nih.gov]
- 4. Nuclear Medicine Pediatric Assessment, Protocols, and Interpretation - StatPearls - NCBI Bookshelf [ncbi.nlm.nih.gov]
- 5. EANM procedural recommendations for managing the paediatric patient in diagnostic nuclear medicine - PMC [pmc.ncbi.nlm.nih.gov]
- 6. med.emory.edu [med.emory.edu]
- 7. researchgate.net [researchgate.net]
- 8. radiographics.rsna.org [radiographics.rsna.org]
- 9. researchgate.net [researchgate.net]
- 10. Unusual Soft Tissue Uptake of Tc-99m MDP in Radiation-induced Sarcoma: Diagnostic Conundrum - PMC [pmc.ncbi.nlm.nih.gov]
- 11. Increased technetium-99 m hydroxy diphosphonate soft tissue uptake on bone scintigraphy in chronic kidney disease patients with secondary hyperparathyroidism: correlation with hyperphosphataemia - PubMed [pubmed.ncbi.nlm.nih.gov]
- 12. med.emory.edu [med.emory.edu]
- 13. auntminnie.com [auntminnie.com]
- 14. Identification and analysis of common artifacts in 99Tcm -MDP bone scan:report of 278 cases [journal.dmu.edu.cn]
- 15. accessdata.fda.gov [accessdata.fda.gov]
- 16. accessdata.fda.gov [accessdata.fda.gov]
- 17. droracle.ai [droracle.ai]

- 18. Changes in renal function in elderly patients following intravenous iodinated contrast administration: a retrospective study - PubMed [pubmed.ncbi.nlm.nih.gov]
- To cite this document: BenchChem. [addressing age-related variations in Tc-99m medronate scan quality]. BenchChem, [2025]. [Online PDF]. Available at: [https://www.benchchem.com/product/b1242282#addressing-age-related-variations-in-tc-99m-medronate-scan-quality]

Disclaimer & Data Validity:

The information provided in this document is for Research Use Only (RUO) and is strictly not intended for diagnostic or therapeutic procedures. While BenchChem strives to provide accurate protocols, we make no warranties, express or implied, regarding the fitness of this product for every specific experimental setup.

Technical Support: The protocols provided are for reference purposes. Unsure if this reagent suits your experiment? [[Contact our Ph.D. Support Team for a compatibility check](#)]

Need Industrial/Bulk Grade? [Request Custom Synthesis Quote](#)

BenchChem

Our mission is to be the trusted global source of essential and advanced chemicals, empowering scientists and researchers to drive progress in science and industry.

Contact

Address: 3281 E Guasti Rd
Ontario, CA 91761, United States
Phone: (601) 213-4426
Email: info@benchchem.com