

Validating HYNIC-iPSMA TFA Imaging Findings with Histopathology: A Comparative Guide

Author: BenchChem Technical Support Team. **Date:** December 2025

Compound of Interest

Compound Name: HYNIC-iPSMA TFA

Cat. No.: B15604253

[Get Quote](#)

For Researchers, Scientists, and Drug Development Professionals

The accurate detection and staging of prostate cancer are critical for determining appropriate treatment strategies and improving patient outcomes. Prostate-specific membrane antigen (PSMA)-targeted imaging has emerged as a highly sensitive method for this purpose. This guide provides a comprehensive comparison of the performance of 99mTc-HYNIC-iPSMA SPECT/CT, a widely accessible radiopharmaceutical imaging technique, with histopathology, the gold standard for cancer diagnosis. Furthermore, it compares its diagnostic accuracy with alternative imaging modalities like 68Ga-PSMA PET/CT and multiparametric MRI (mpMRI), supported by experimental data.

Performance of 99mTc-HYNIC-iPSMA SPECT/CT Validated by Histopathology

Histopathological examination of surgically removed tissues remains the definitive method for confirming the presence and extent of cancer. Several studies have evaluated the diagnostic accuracy of 99mTc-HYNIC-iPSMA SPECT/CT by correlating its findings with histopathology results, particularly in the context of lymph node metastases, a crucial prognostic factor.

A retrospective study involving 31 patients with newly diagnosed prostate cancer who underwent 99mTc-HYNIC-iPSMA SPECT/CT provides insight into its reliability. In a subset of seven patients who subsequently underwent pelvic lymph node dissection, the imaging findings were entirely consistent with the histopathological results, with no metastatic lymph nodes

detected in either modality[1]. This suggests a high negative predictive value in this small cohort.

Quantitative Analysis of Diagnostic Accuracy

To provide a clearer picture of 99mTc-HYNIC-iPSMA SPECT/CT's performance, the following table summarizes key diagnostic accuracy metrics from a study that performed a head-to-head comparison with histopathology in a larger patient group.

Performance Metric	99mTc-HYNIC-iPSMA SPECT/CT	Alternative: 68Ga-PSMA PET/CT	Alternative: mpMRI
Sensitivity	97.7% (Primary Tumor)[2]	90.9% (Primary Tumor)[2]	90.9% (Primary Tumor)[2]
Specificity	75.0% (Primary Tumor)[2]	75.0% (Primary Tumor)[2]	75.0% (Primary Tumor)[2]
Positive Predictive Value (PPV)	Not Reported	66.7% (Lymph Nodes) [3]	59.1% (Lymph Nodes) [3]
Negative Predictive Value (NPV)	Not Reported	84.3% (Lymph Nodes) [3]	78.7% (Lymph Nodes) [3]

Comparison with Alternative Imaging Modalities

While histopathology is the gold standard, in clinical practice, non-invasive imaging techniques are crucial for initial staging and management. Here, we compare 99mTc-HYNIC-iPSMA SPECT/CT with two key alternatives: 68Ga-PSMA PET/CT and multiparametric MRI (mpMRI).

99mTc-HYNIC-iPSMA SPECT/CT vs. 68Ga-PSMA PET/CT

68Ga-PSMA PET/CT is a well-established and highly sensitive imaging modality for prostate cancer. Multiple studies have conducted head-to-head comparisons with 99mTc-HYNIC-iPSMA SPECT/CT.

One prospective study found that while 68Ga-PSMA PET/CT detected a significantly higher mean number of lesions overall, there was no significant difference in the detection of lymph node and bone metastases between the two methods[2]. Both modalities demonstrated

comparable diagnostic accuracy for detecting retroperitoneal and pelvic lymph nodes[4][5][6]. A strong correlation has been observed between the uptake values (SUVmax for PET and TBR for SPECT) in the prostate, bone, and lymph nodes, supporting the comparable performance of both tracers in these areas[5][6][7].

99mTc-HYNIC-iPSMA SPECT/CT vs. multiparametric MRI (mpMRI)

Multiparametric MRI is considered the standard for local staging of prostate cancer. A retrospective study comparing 99mTc-PSMA SPECT/CT with mpMRI for the detection of primary prostate cancer found no significant difference in their detection capabilities[2]. Both imaging techniques demonstrated identical specificities of 75.0%, while 99mTc-PSMA SPECT/CT showed a slightly higher sensitivity of 97.7% compared to 90.9% for mpMRI[2]. Interestingly, the combination of both modalities was found to improve diagnostic efficacy compared to either technique alone[2].

Experimental Protocols

Detailed methodologies are crucial for the replication and validation of research findings. The following sections outline the typical experimental protocols for 99mTc-HYNIC-iPSMA SPECT/CT imaging and the subsequent histopathological validation.

99mTc-HYNIC-iPSMA SPECT/CT Imaging Protocol

Patient Preparation and Radiotracer Administration:

- Patients are typically required to be well-hydrated.
- An intravenous injection of approximately 740 MBq (20 mCi) of 99mTc-HYNIC-iPSMA is administered[1].

Imaging Acquisition:

- Imaging is performed 3 to 4 hours after the injection[1].
- Planar whole-body images are acquired using a SPECT/CT scanner equipped with a low-energy, all-purpose collimator[1].

- The acquisition parameters for the whole-body scan are typically a table speed of 10 cm/min, a 256 x 256 matrix, and a 140 keV energy window[8].
- SPECT imaging of specific regions (e.g., pelvis, abdomen) is then performed with parameters such as 30 seconds per frame for a total of 60 frames in a 128 x 128 matrix[8].
- A low-dose CT scan is acquired for attenuation correction and anatomical localization, typically at 120 kV and 90 mAs[8].

Histopathological Validation Protocol

Specimen Handling and Processing:

- Following surgical resection (e.g., radical prostatectomy with pelvic lymph node dissection), the specimens are fixed in formalin.
- Lymph nodes are dissected from the surrounding adipose tissue. Nodes smaller than 1.0 cm are bisected, while larger nodes are sliced at 2 mm intervals[9].
- The size, color, consistency, and any visible abnormalities of the cut surfaces are recorded[9].

Microscopic Examination:

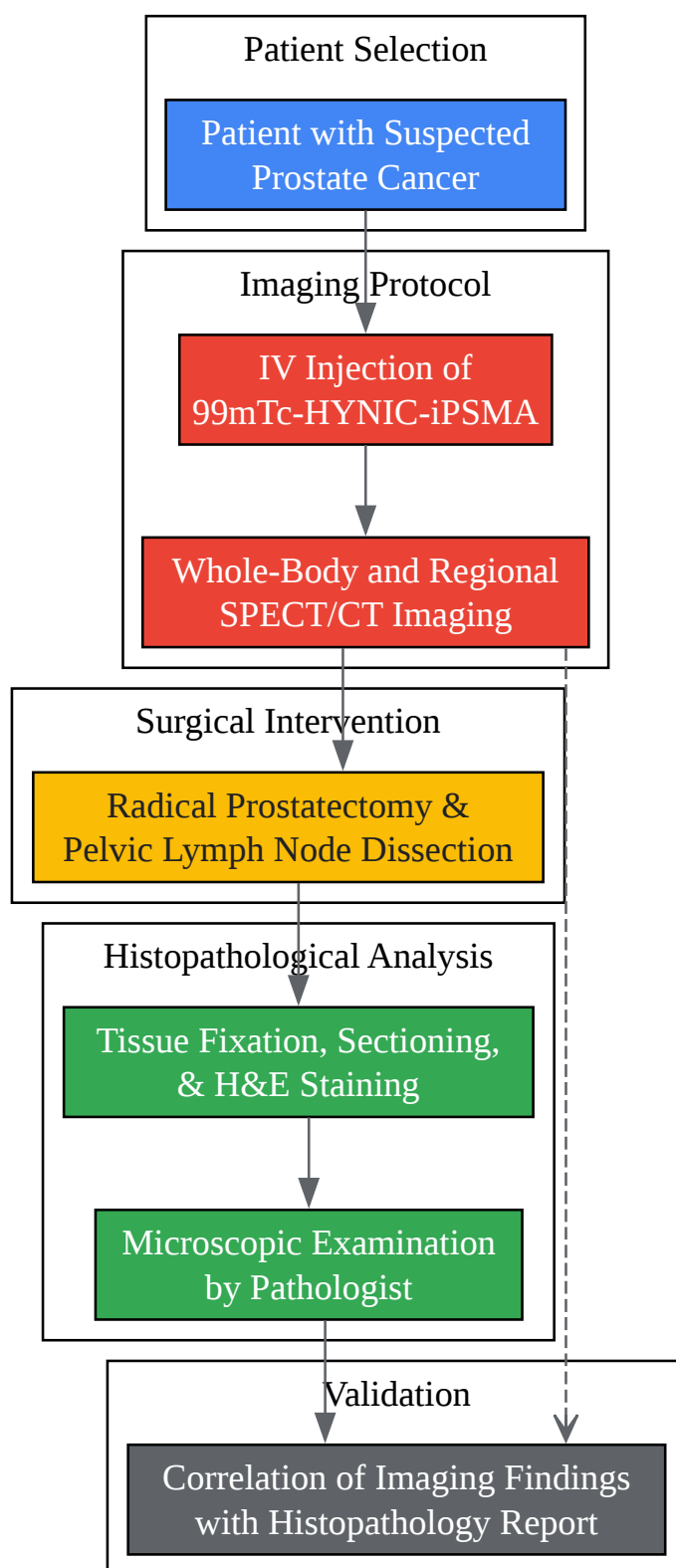
- The tissue slices are processed and embedded in paraffin wax.
- Sections of 3-4 μm thickness are cut and stained with hematoxylin and eosin (H&E)[9][10].
- For cases with a high clinical suspicion of malignancy but negative initial sections, at least three levels of the tissue block are sectioned and examined[9].
- A diagnosis of adenocarcinoma is based on specific histological features, including glandular architecture, cellular morphology, and invasion into surrounding tissues[10].
Immunohistochemistry for markers like high molecular weight cytokeratins can be used to aid in the differentiation of benign from malignant glands[10].

Correlation with Imaging:

- The location of metastatic deposits within the resected lymph nodes, as identified by the pathologist, is correlated with the location of radiotracer uptake on the ^{99m}Tc-HYNIC-iPSMA SPECT/CT images. This allows for a direct comparison of the imaging findings with the ground truth of histopathology.

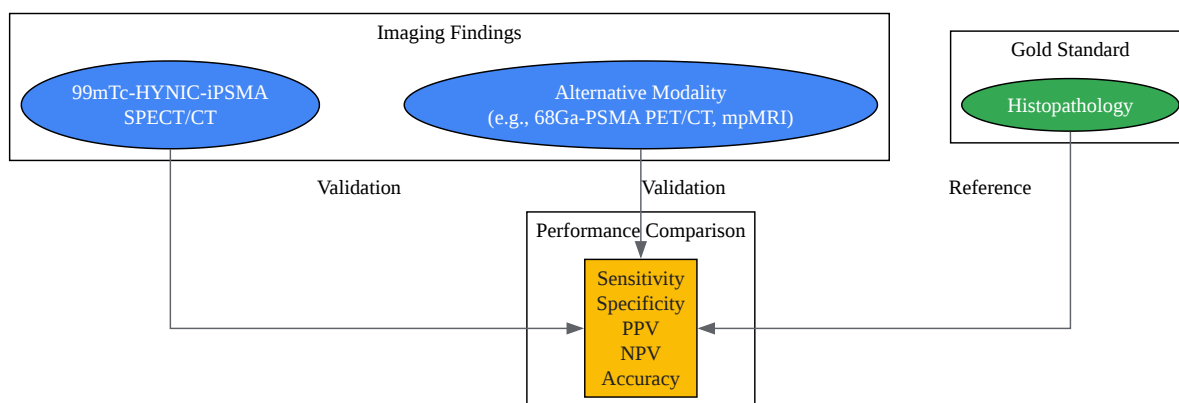
Visualizing the Workflow and Validation Logic

To better illustrate the processes described, the following diagrams, created using the DOT language, depict the experimental workflow and the logical relationship of validating imaging findings.



[Click to download full resolution via product page](#)

Experimental Workflow from Patient Selection to Histopathological Validation.



[Click to download full resolution via product page](#)

Logical Framework for Validating Imaging Modalities against Histopathology.

Need Custom Synthesis?

BenchChem offers custom synthesis for rare earth carbides and specific isotopic labeling.

Email: info@benchchem.com or [Request Quote Online](#).

References

- 1. Frontiers | The efficacy of 99mTc-HYNIC-PSMA SPECT/CT in detecting primary lesions and metastasis in newly diagnosed prostate cancer [frontiersin.org]
- 2. researchgate.net [researchgate.net]
- 3. Histological comparison between predictive value of preoperative 3-T multiparametric MRI and 68 Ga-PSMA PET/CT scan for pathological outcomes at radical prostatectomy and pelvic lymph node dissection for prostate cancer - PubMed [pubmed.ncbi.nlm.nih.gov]
- 4. researchgate.net [researchgate.net]

- 5. Head to head comparison performance of 99mTc-EDDA/HYNIC-iPSMA SPECT/CT and 68Ga-PSMA-11 PET/CT a prospective study in biochemical recurrence prostate cancer patients - PMC [pmc.ncbi.nlm.nih.gov]
- 6. e-century.us [e-century.us]
- 7. Head to head comparison performance of 99mTc-EDDA/HYNIC-iPSMA SPECT/CT and 68Ga-PSMA-11 PET/CT a prospective study in biochemical recurrence prostate cancer patients - PubMed [pubmed.ncbi.nlm.nih.gov]
- 8. researchgate.net [researchgate.net]
- 9. rcpaath.org [rcpaath.org]
- 10. Histopathology of Prostate Cancer - PMC [pmc.ncbi.nlm.nih.gov]
- To cite this document: BenchChem. [Validating HYNIC-iPSMA TFA Imaging Findings with Histopathology: A Comparative Guide]. BenchChem, [2025]. [Online PDF]. Available at: [https://www.benchchem.com/product/b15604253#validating-hynic-ipsma-tfa-imaging-findings-with-histopathology]

Disclaimer & Data Validity:

The information provided in this document is for Research Use Only (RUO) and is strictly not intended for diagnostic or therapeutic procedures. While BenchChem strives to provide accurate protocols, we make no warranties, express or implied, regarding the fitness of this product for every specific experimental setup.

Technical Support: The protocols provided are for reference purposes. Unsure if this reagent suits your experiment? [[Contact our Ph.D. Support Team for a compatibility check](#)]

Need Industrial/Bulk Grade? [Request Custom Synthesis Quote](#)

BenchChem

Our mission is to be the trusted global source of essential and advanced chemicals, empowering scientists and researchers to drive progress in science and industry.

Contact

Address: 3281 E Guasti Rd

Ontario, CA 91761, United States

Phone: (601) 213-4426

Email: info@benchchem.com