

Validating Gadoxetic Acid MRI Findings with Histopathology: A Comparative Guide for Researchers

Author: BenchChem Technical Support Team. **Date:** December 2025

Compound of Interest

Compound Name: *Gadoxetic acid*

Cat. No.: *B1262754*

[Get Quote](#)

For researchers, scientists, and drug development professionals, the accurate characterization of focal liver lesions is paramount. **Gadoxetic acid**-enhanced Magnetic Resonance Imaging (MRI) has emerged as a powerful tool in this domain, offering both dynamic and hepatobiliary phase imaging. This guide provides a comprehensive comparison of **gadoxetic acid** MRI with alternative imaging modalities, supported by experimental data and histopathological validation.

Gadoxetic acid, a hepatocyte-specific contrast agent, enhances the diagnostic capabilities of liver MRI by providing functional information about hepatocytes.[1][2] Approximately 50% of the injected dose is taken up by functional hepatocytes, leading to enhancement of normal liver parenchyma in the hepatobiliary phase (HBP), typically acquired 20 minutes after contrast administration.[3][4] This unique property significantly improves the detection and characterization of focal liver lesions compared to conventional extracellular contrast agents or other imaging modalities like computed tomography (CT).[2][5][6]

Comparative Diagnostic Performance

Histopathological analysis of resected liver tissue serves as the gold standard for the definitive diagnosis of focal liver lesions. Numerous studies have validated the findings of **gadoxetic acid** MRI against this standard, demonstrating its high diagnostic accuracy.

Hepatocellular Carcinoma (HCC)

Gadoxetic acid-enhanced MRI is particularly valuable for the diagnosis of HCC, especially for early-stage and small lesions.^{[1][7]} The characteristic feature of most HCCs on **gadoxetic acid** MRI is arterial phase hyperenhancement followed by "washout" in the portal venous or delayed phases, and hypointensity in the hepatobiliary phase due to the lack of functional hepatocytes.^{[1][4]}

A key advantage of **gadoxetic acid** is its ability to differentiate HCC from benign hepatocellular lesions like focal nodular hyperplasia (FNH), which often shows iso- or hyperintensity in the HBP due to the presence of functional hepatocytes.^{[1][5]}

Feature	Gadoxetic Acid MRI	Multidetector CT (MDCT)	Reference
Sensitivity for HCC	91.45%	71.6%	^[8]
Sensitivity for small HCC (<1.5 cm)	Increased by 24.7% vs MDCT	-	^[8]
Overall Per-Lesion Sensitivity (Malignant Lesions)	58% - 64%	-	^[9]
PPV for Malignant Lesions	98% - 100%	-	^[9]

Colorectal Liver Metastases (CRLM)

For the detection of CRLM, especially after chemotherapy, **gadoxetic acid** MRI has shown superiority over contrast-enhanced CT (CECT). The improved conspicuity of lesions against the enhanced liver parenchyma in the HBP is a significant factor.

Feature	Gadoxetic Acid MRI (EOB-MRI)	Contrast-Enhanced CT (CECT)	Reference
Sensitivity for CRLM (≤ 1.0 cm)	86%	45.5%	[10]
Indeterminate Lesion Diagnosis	7%	33%	[10]
Interobserver Concordance (lesions ≤ 1.0 cm)	72%	51%	[10]

Benign Lesions: FNH vs. Hepatocellular Adenoma (HCA)

The differentiation between FNH and HCA is a common diagnostic challenge. **Gadoxetic acid** MRI significantly aids in this differentiation. FNH, being composed of hyperplastic hepatocytes, typically appears iso- or hyperintense in the HBP.[\[1\]](#)[\[5\]](#) In contrast, most HCAs, lacking functional hepatocytes and bile ducts, appear hypointense in the HBP.[\[5\]](#)[\[11\]](#)

A systematic review reported high sensitivity and specificity for differentiating HCA from FNH based on HBP hypointensity.

Feature	Value	Reference
Pooled Sensitivity for HCA (Low SI in HBP)	92%	[11]
Pooled Specificity for HCA (Low SI in HBP)	95%	[11]

Experimental Protocols

Standardized protocols are crucial for reproducible and comparable results. The following outlines typical methodologies for **gadoxetic acid** MRI and subsequent histopathological validation.

Gadoxetic Acid MRI Protocol

A standard liver MRI protocol with **gadoxetic acid** includes pre-contrast sequences followed by dynamic post-contrast imaging and a delayed hepatobiliary phase.

- Pre-contrast sequences: T1-weighted in- and out-of-phase, and T2-weighted images.[12][13]
- Contrast Agent: **Gadoxetic acid** (e.g., Primovist® or Eovist®) administered intravenously as a bolus injection (e.g., 0.025 mmol/kg body weight at 1-2 mL/s), followed by a saline flush.[3][13]
- Dynamic Phases: Imaging is performed during the late arterial, portal venous, and transitional phases.[13][14]
- Hepatobiliary Phase (HBP): T1-weighted fat-suppressed images are acquired approximately 20 minutes after contrast injection.[13][15]

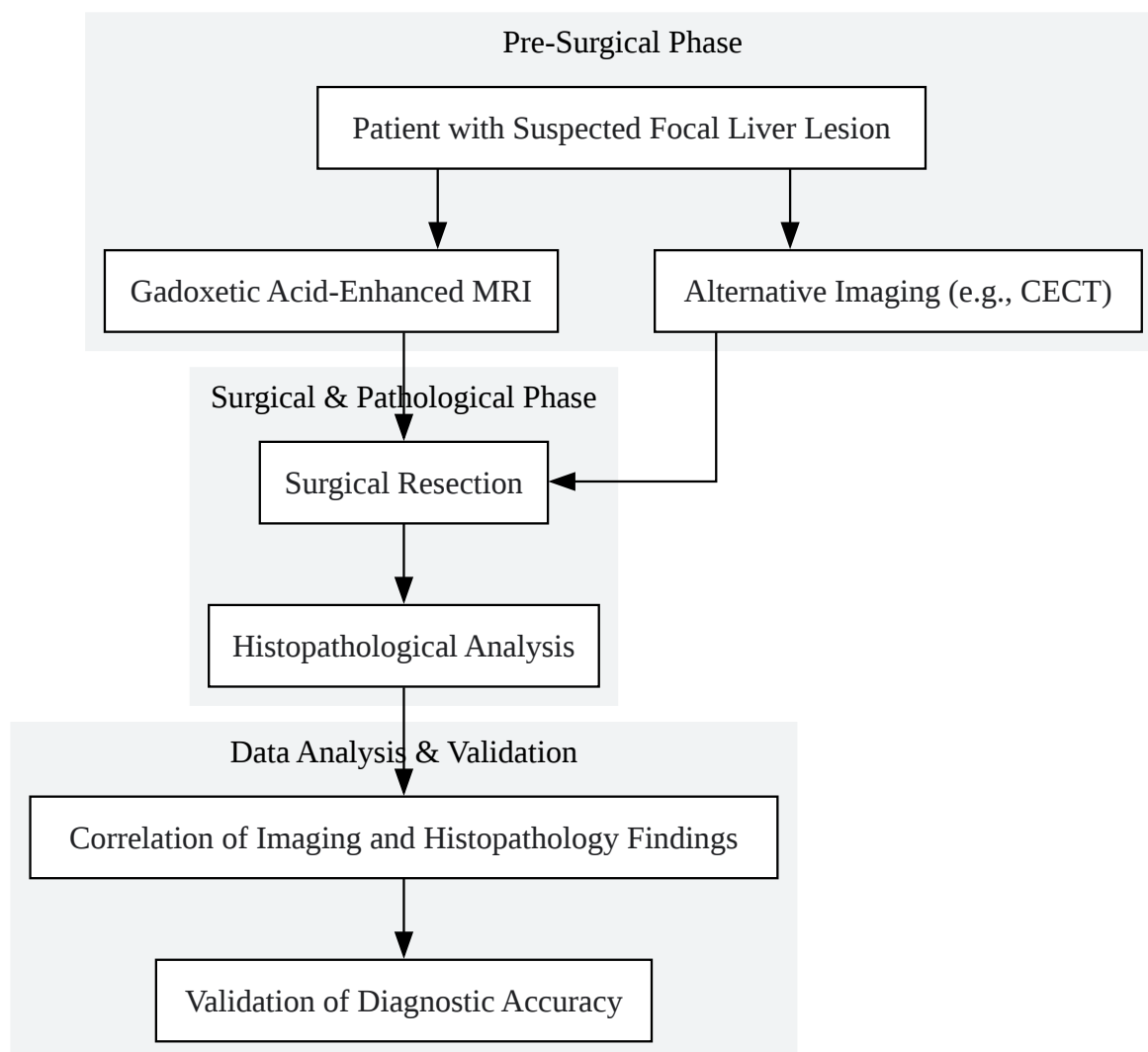
Histopathological Validation

Following surgical resection of the liver lesion, the specimen is processed for histopathological examination, which serves as the reference standard.

- Specimen Handling: The resected liver specimen is fixed in formalin.
- Gross Examination: The lesion is measured, and its gross features are documented.
- Sectioning: The specimen is sectioned, and representative tissue blocks are selected.
- Microscopic Examination: The tissue blocks are processed, embedded in paraffin, sectioned, and stained with Hematoxylin and Eosin (H&E).
- Immunohistochemistry: In some cases, special stains or immunohistochemistry are performed to confirm the diagnosis (e.g., for subtyping HCAs).[16]
- Correlation: The histopathological findings are then correlated with the pre-operative MRI findings.

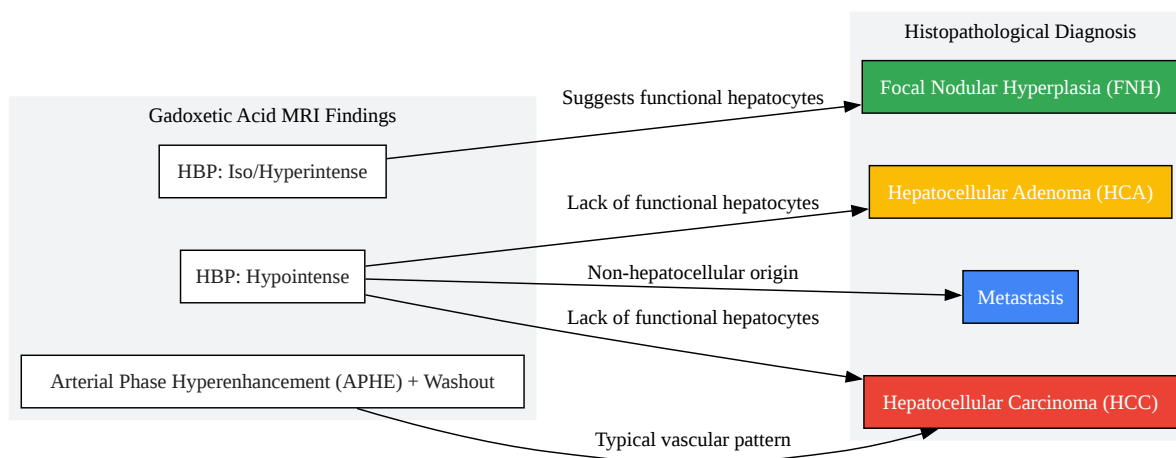
Visualization of Workflows and Pathways

To further elucidate the processes and relationships discussed, the following diagrams are provided.



[Click to download full resolution via product page](#)

Experimental workflow for validating MRI findings.



[Click to download full resolution via product page](#)

Need Custom Synthesis?

BenchChem offers custom synthesis for rare earth carbides and specific isotopic labeling.

Email: info@benchchem.com or [Request Quote Online](#).

References

- 1. Gadoxetic acid-enhanced magnetic resonance imaging: Hepatocellular carcinoma and mimickers - PMC [pmc.ncbi.nlm.nih.gov]
- 2. Indeterminate liver lesions on gadoxetic acid-enhanced magnetic resonance imaging of the liver: Case-based radiologic-pathologic review - PMC [pmc.ncbi.nlm.nih.gov]
- 3. Improved Characterization of Focal Liver Lesions With Liver-Specific Gadoxetic Acid Disodium–Enhanced Magnetic Resonance Imaging: A Multicenter Phase 3 Clinical Trial - PMC [pmc.ncbi.nlm.nih.gov]

- 4. Liver-specific agents for contrast-enhanced MRI: role in oncological imaging - PMC [pmc.ncbi.nlm.nih.gov]
- 5. Focal liver lesions detection and characterization: The advantages of gadoxetic acid-enhanced liver MRI - PMC [pmc.ncbi.nlm.nih.gov]
- 6. Detection and characterization of liver lesions using gadoxetic acid as a tissue-specific contrast agent - PMC [pmc.ncbi.nlm.nih.gov]
- 7. Hepatocellular Carcinoma | Gadoxetic acid-enhanced MRI in hepatocellular carcinoma: a comprehensive review of diagnostic, surveillance, and treatment response prediction and assessment | springermedicine.com [springermedicine.com]
- 8. The role of gadoxetic acid as a paramagnetic contrast medium in the characterization and detection of focal liver lesions: a review - PMC [pmc.ncbi.nlm.nih.gov]
- 9. Diagnostic Accuracy of Preoperative Gadoxetic Acid-enhanced 3-T MR Imaging for Malignant Liver Lesions by Using Ex Vivo MR Imaging-matched Pathologic Findings as the Reference Standard - PMC [pmc.ncbi.nlm.nih.gov]
- 10. Prospective comparison of gadoxetic acid-enhanced liver MRI and contrast-enhanced CT with histopathological correlation for preoperative detection of colorectal liver metastases following chemotherapy and potential impact on surgical plan - PubMed [pubmed.ncbi.nlm.nih.gov]
- 11. Diagnostic Value of Gadoxetic Acid-Enhanced MR Imaging to Distinguish HCA and Its Subtype from FNH: A Systematic Review - PMC [pmc.ncbi.nlm.nih.gov]
- 12. Gadoxetic acid-enhanced magnetic resonance imaging can predict the pathologic stage of solitary hepatocellular carcinoma - PMC [pmc.ncbi.nlm.nih.gov]
- 13. Diagnostic performance of abbreviated gadoxetic acid-enhanced magnetic resonance protocols with contrast-enhanced computed tomography for detection of colorectal liver metastases - PMC [pmc.ncbi.nlm.nih.gov]
- 14. Optimal Segment Selection on Gadoxetic Acid-Enhanced MRI to Improve Diagnostic Accuracy in the Histological Grading of Liver Inflammation and Fibrosis in Patients with Chronic Hepatitis B - PMC [pmc.ncbi.nlm.nih.gov]
- 15. Pathology-MRI Correlation of Hepatocarcinogenesis: Recent Update - PMC [pmc.ncbi.nlm.nih.gov]
- 16. Benign focal liver lesions: The role of magnetic resonance imaging - PMC [pmc.ncbi.nlm.nih.gov]
- To cite this document: BenchChem. [Validating Gadoxetic Acid MRI Findings with Histopathology: A Comparative Guide for Researchers]. BenchChem, [2025]. [Online PDF].

Available at: [<https://www.benchchem.com/product/b1262754#validating-gadoxetic-acid-mri-findings-with-histopathology>]

Disclaimer & Data Validity:

The information provided in this document is for Research Use Only (RUO) and is strictly not intended for diagnostic or therapeutic procedures. While BenchChem strives to provide accurate protocols, we make no warranties, express or implied, regarding the fitness of this product for every specific experimental setup.

Technical Support: The protocols provided are for reference purposes. Unsure if this reagent suits your experiment? [[Contact our Ph.D. Support Team for a compatibility check](#)]

Need Industrial/Bulk Grade? [Request Custom Synthesis Quote](#)

BenchChem

Our mission is to be the trusted global source of essential and advanced chemicals, empowering scientists and researchers to drive progress in science and industry.

Contact

Address: 3281 E Guasti Rd
Ontario, CA 91761, United States
Phone: (601) 213-4426
Email: info@benchchem.com