

Validating Clometacin-Induced Liver Injury: A Comparative Guide to Preclinical Histological Assessment

Author: BenchChem Technical Support Team. **Date:** December 2025

Compound of Interest

Compound Name: Clometacin

Cat. No.: B1669217

[Get Quote](#)

For Researchers, Scientists, and Drug Development Professionals

This guide provides a comparative overview of established preclinical models and methodologies for the histological validation of drug-induced liver injury (DILI) with autoimmune features, offering a framework for assessing compounds like **Clometacin**. **Clometacin**, an anti-inflammatory drug, has been associated with a distinct form of hepatotoxicity characterized by features resembling autoimmune hepatitis. This document outlines key experimental protocols, presents comparative data from relevant animal models, and illustrates essential workflows and signaling pathways to guide researchers in the robust preclinical validation of similar DILI profiles.

Comparative Analysis of Preclinical Models for Autoimmune-Like DILI

Since no specific preclinical model for **Clometacin**-induced liver injury has been formally established, this guide draws comparisons with well-characterized models of drug-induced autoimmune-like hepatitis. The Halothane-induced liver injury model in BALB/cJ mice and the experimental autoimmune hepatitis (EAH) model are particularly relevant due to their immunological components and histological features that echo the reported effects of **Clometacin** in humans.

Table 1: Comparison of Key Histological and Biochemical Features

| Feature | Human Clometacin-Induced Liver Injury | Halothane-Induced Liver Injury (BALB/cJ Mice) | Experimental Autoimmune Hepatitis (EAH) (S-100 Model) |
|------------------------------|--|---|--|
| Primary Histological Finding | Acute hepatitis with centrilobular necrosis, chronic active hepatitis[1] | Extensive centrilobular necrosis, inflammatory cell infiltrate, steatosis[2][3] | Perivascular inflammatory infiltrates and hepatocyte necrosis[4] |
| Immune Cell Infiltrate | Lymphoplasmacytic infiltrate | Neutrophil and CD4+ T cell infiltration[2][5] | Mononuclear cell infiltration, primarily T-lymphocytes[4][6][7] |
| Autoimmune Features | Akin to autoimmune chronic active hepatitis, presence of autoantibodies[1] | Elicits antibody formation against trifluoroacetylated protein neoantigens[8] | Induction of T-cell reactivity against liver S-100 proteins[4] |
| Fibrosis | Can progress to cirrhosis[9] | Not a primary acute feature, but chronic models can show fibrosis | Can lead to fibrosis with prolonged inflammation |
| Serum ALT/AST Levels | Significantly elevated | Dose-dependent, can exceed 8000 U/L[2] | Significantly increased[6] |
| Serum Bilirubin | Elevated in cholestatic cases | Not consistently reported as a primary marker | Can be elevated depending on severity |

Experimental Protocols

Halothane-Induced Liver Injury Model

This model is valuable for studying idiosyncratic DILI with an immune component.

Species and Strain: Female BALB/cJ mice (8 weeks old) are particularly susceptible[2]. C57BL/6 mice are resistant, highlighting a genetic predisposition[2][3].

Induction Protocol:

- Fast mice for 15 hours prior to induction to increase sensitivity[2].
- Administer Halothane (e.g., 15-30 mmol/kg) via intraperitoneal (i.p.) injection. Anesthesia is typically transient at higher doses[2].
- Collect blood and liver tissue for analysis 24 hours post-administration[2].

Endpoint Analysis:

- Biochemistry: Measure serum Alanine Aminotransferase (ALT) and Aspartate Aminotransferase (AST) levels.
- Histology: Process liver tissue for Hematoxylin and Eosin (H&E) and Masson's Trichrome staining.

Experimental Autoimmune Hepatitis (EAH) Model (S-100)

This model is used to investigate the autoimmune pathogenesis of hepatitis.

Species and Strain: C57BL/6 mice are most susceptible[4].

Induction Protocol:

- Prepare a syngeneic liver homogenate and obtain the 100,000 g supernatant (S-100 fraction)[4][10].
- Emulsify the S-100 protein in Complete Freund's Adjuvant (CFA).
- Administer a single intraperitoneal (i.p.) injection of the S-100/CFA emulsion to induce hepatitis[4]. In some protocols, injections are repeated on days 0 and 7[6].
- Monitor disease progression over several weeks. Peak histological changes are often observed around 4 weeks post-induction[4].

Endpoint Analysis:

- Biochemistry: Monitor serum ALT and AST levels.

- Immunology: Assess for the presence of autoantibodies and liver-infiltrating T-cells.
- Histology: Perform H&E and Masson's Trichrome staining to evaluate inflammation and fibrosis.

Histological Processing and Staining

Hematoxylin and Eosin (H&E) Staining:

- Fix liver tissue in 10% neutral buffered formalin.
- Process the tissue through graded alcohols and xylene, and embed in paraffin.
- Cut 4-5 μm sections and mount on glass slides.
- Deparaffinize and rehydrate the sections.
- Stain with Hematoxylin to stain nuclei blue/purple and Eosin to stain cytoplasm and extracellular matrix pink[11][12].

Masson's Trichrome Staining:

- Follow steps 1-4 for H&E staining.
- After rehydration, mordant sections in Bouin's solution.
- Stain with Weigert's iron hematoxylin.
- Stain with Biebrich scarlet-acid fuchsin.
- Differentiate in phosphomolybdic-phosphotungstic acid solution.
- Counterstain with aniline blue to stain collagen blue[13][14].

Quantitative Histological Assessment

A semi-quantitative scoring system, such as the modified Ishak score, is recommended for the objective assessment of liver histology.

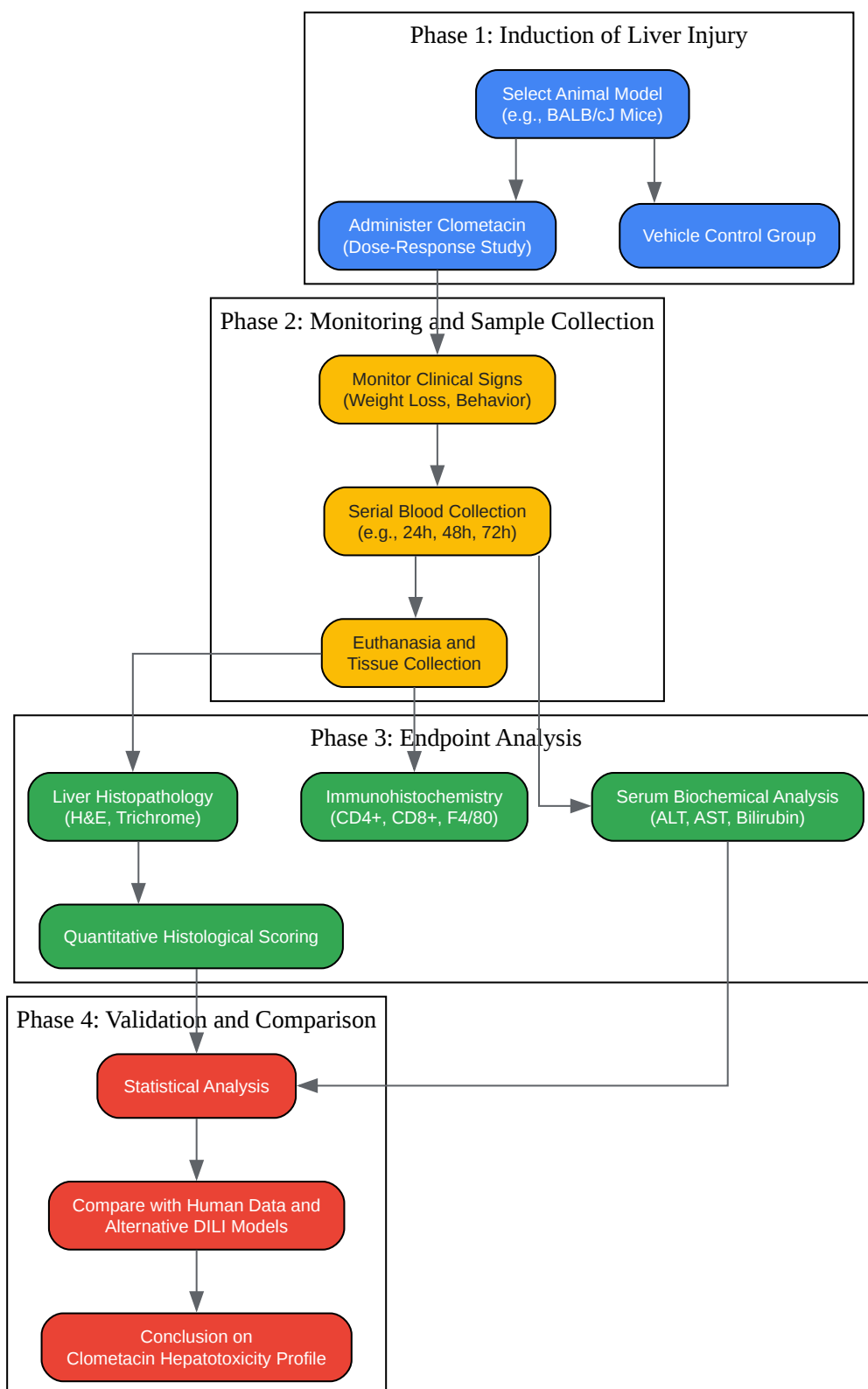
Table 2: Modified Histological Scoring System for Murine Liver Injury

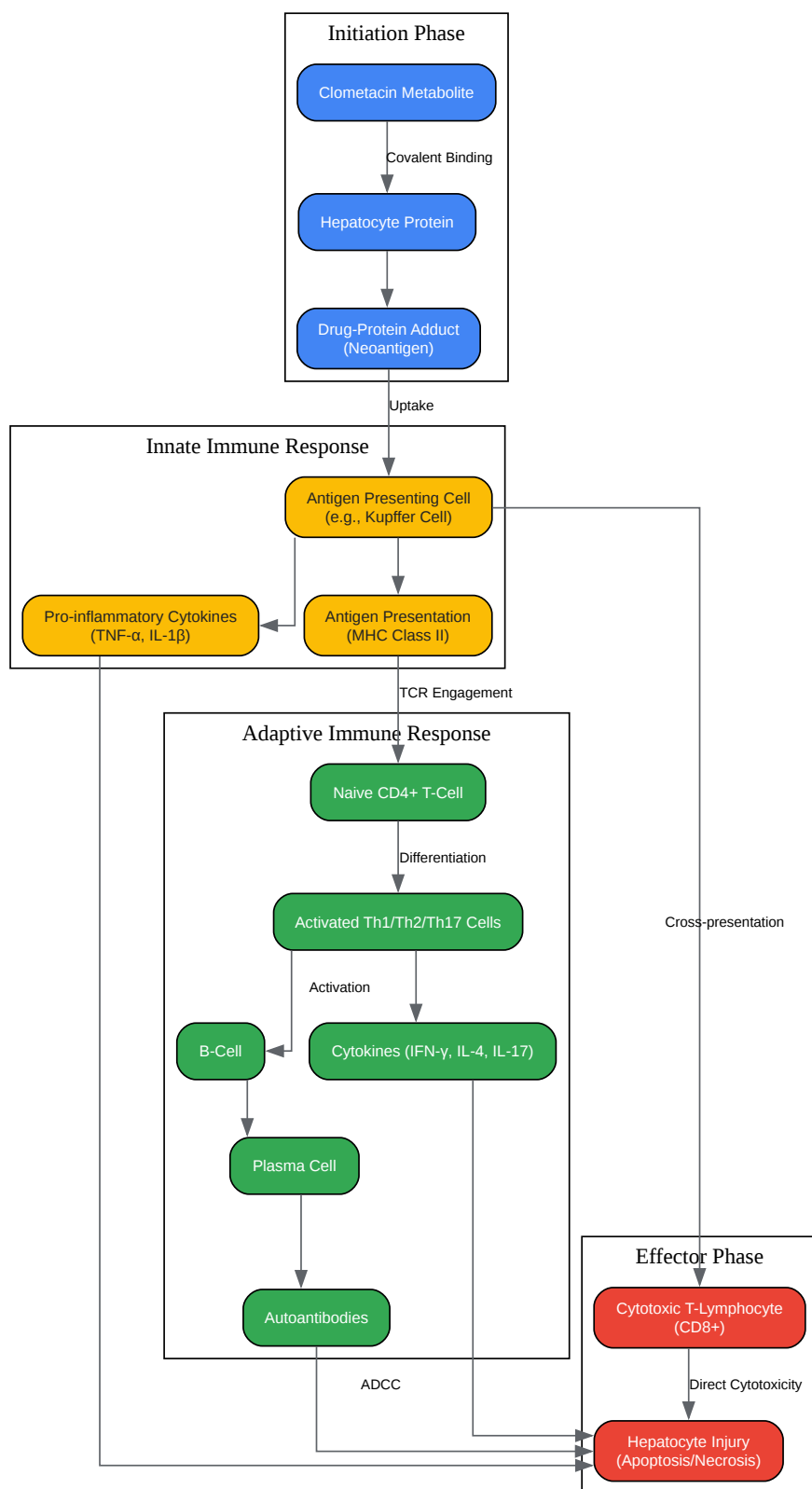
| Feature | Score | Description |
|----------------------------|---|--------------------------|
| Necrosis & Apoptosis | 0 | No necrosis or apoptosis |
| 1 | Focal or spotty necrosis/apoptosis | |
| 2 | Confluent necrosis | |
| 3 | Bridging necrosis (portal-portal or portal-central) | |
| 4 | Pan-acinar or multi-acinar necrosis | |
| Inflammation | 0 | No inflammation |
| 1 | Mild portal inflammation | |
| 2 | Moderate portal inflammation with mild piecemeal necrosis | |
| 3 | Marked portal inflammation with moderate piecemeal necrosis | |
| 4 | Severe portal inflammation with severe piecemeal necrosis | |
| Fibrosis (Trichrome Stain) | 0 | No fibrosis |
| 1 | Fibrous expansion of some portal areas | |
| 2 | Fibrous expansion of most portal areas | |
| 3 | Fibrous expansion of most portal areas with occasional portal-portal bridging | |
| 4 | Marked bridging fibrosis with architectural distortion | |

| | |
|---|-----------------------|
| 5 | Incomplete cirrhosis |
| 6 | Established cirrhosis |

Adapted from various histological scoring systems for chronic hepatitis[15][16].

Visualizing Experimental Workflows and Signaling Pathways





[Click to download full resolution via product page](#)

Need Custom Synthesis?

BenchChem offers custom synthesis for rare earth carbides and specific isotopic labeling.

Email: info@benchchem.com or [Request Quote Online](#).

References

- 1. Cytochrome P450 2D6 as a Model Antigen - PMC [pmc.ncbi.nlm.nih.gov]
- 2. A Mouse Model of Severe Halothane Hepatitis Based on Human Risk Factors - PMC [pmc.ncbi.nlm.nih.gov]
- 3. A mouse model of severe halothane hepatitis based on human risk factors - PubMed [pubmed.ncbi.nlm.nih.gov]
- 4. Experimental autoimmune hepatitis: disease induction, time course and T-cell reactivity - PubMed [pubmed.ncbi.nlm.nih.gov]
- 5. Drug-induced allergic hepatitis develops in mice when myeloid-derived suppressor cells are depleted prior to halothane treatment - PubMed [pubmed.ncbi.nlm.nih.gov]
- 6. Umbilical Cord-Derived Mesenchymal Stem Cells Attenuate S100-Induced Autoimmune Hepatitis via Modulating Th1 and Th17 Cell Responses in Mice - PMC [pmc.ncbi.nlm.nih.gov]
- 7. β -arrestin2 deficiency ameliorates S-100-induced autoimmune hepatitis in mice by inhibiting infiltration of monocyte-derived macrophage and attenuating hepatocyte apoptosis - PMC [pmc.ncbi.nlm.nih.gov]
- 8. HALOTHANE-INDUCED HEPATITIS: PARADIGM OR PARADOX FOR DRUG-INDUCED LIVER INJURY - PMC [pmc.ncbi.nlm.nih.gov]
- 9. urschrisen.de [urschrisen.de]
- 10. Animal Models for Autoimmune Hepatitis: Are Current Models Good Enough? - PMC [pmc.ncbi.nlm.nih.gov]
- 11. Liver Biopsy Interpretation: Special Stains | AASLD [aasld.org]
- 12. ueg.eu [ueg.eu]
- 13. creative-bioarray.com [creative-bioarray.com]
- 14. Role of special stains in diagnostic liver pathology - PMC [pmc.ncbi.nlm.nih.gov]
- 15. UpToDate 2018 [doctorabad.com]

- 16. researchgate.net [researchgate.net]
- To cite this document: BenchChem. [Validating Clometacin-Induced Liver Injury: A Comparative Guide to Preclinical Histological Assessment]. BenchChem, [2025]. [Online PDF]. Available at: [<https://www.benchchem.com/product/b1669217#validating-clometacin-induced-liver-injury-with-histology>]

Disclaimer & Data Validity:

The information provided in this document is for Research Use Only (RUO) and is strictly not intended for diagnostic or therapeutic procedures. While BenchChem strives to provide accurate protocols, we make no warranties, express or implied, regarding the fitness of this product for every specific experimental setup.

Technical Support: The protocols provided are for reference purposes. Unsure if this reagent suits your experiment? [[Contact our Ph.D. Support Team for a compatibility check](#)]

Need Industrial/Bulk Grade? [Request Custom Synthesis Quote](#)

BenchChem

Our mission is to be the trusted global source of essential and advanced chemicals, empowering scientists and researchers to drive progress in science and industry.

Contact

Address: 3281 E Guasti Rd
Ontario, CA 91761, United States
Phone: (601) 213-4426
Email: info@benchchem.com