

# Unveiling the Diagnostic Precision of Technetium-99m Sestamibi: A Meta-Analysis Comparison

**Author:** BenchChem Technical Support Team. **Date:** December 2025

## Compound of Interest

Compound Name: *TECHNETIUM SESTAMIBI*

Cat. No.: *B1142544*

[Get Quote](#)

For Immediate Release

A Comprehensive Review of Technetium-99m Sestamibi's Diagnostic Performance Across Key Clinical Applications

This guide offers a meta-analysis of the diagnostic performance of Technetium-99m Sestamibi (MIBI), a widely utilized radiopharmaceutical for diagnostic imaging. The following sections provide a comparative overview of its efficacy in the diagnosis of breast cancer, hyperparathyroidism, and coronary artery disease, supported by quantitative data from various studies. Detailed experimental protocols are also outlined to provide researchers, scientists, and drug development professionals with a thorough understanding of the methodologies employed in these diagnostic accuracy studies.

## Quantitative Data Summary

The diagnostic performance of Technetium-99m Sestamibi varies across different clinical applications and patient populations. The following tables summarize the key performance metrics from meta-analyses and significant studies.

### Table 1: Diagnostic Performance of Technetium-99m Sestamibi in Breast Cancer Detection

Study Population	Imaging Technique	Sensitivity (%)	Specificity (%)	Positive Predictive Value (PPV) (%)	Negative Predictive Value (NPV) (%)
Overall	Scintimammography	85.2	86.6	88.2	83.6
Palpable Masses	Scintimammography	87.8	87.5	Not Reported	Not Reported
Non-palpable Masses	Scintimammography	66.8	86.9	Not Reported	Not Reported
Dense Breasts	Molecular Breast Imaging (MBI)	91	93	Not Reported	Not Reported

Table 2: Diagnostic Performance of Technetium-99m Sestamibi in Hyperparathyroidism

Imaging Technique	Sensitivity (%)	Specificity (%)	Additional Notes
Planar Imaging	70-90	Not Widely Reported	Performance can be limited by small adenomas and multiglandular disease.
SPECT	79-91	Not Widely Reported	Improves localization, especially for ectopic adenomas.
SPECT/CT	88-95	Not Widely Reported	Offers superior localization by combining functional and anatomical imaging.

**Table 3: Diagnostic Performance of Technetium-99m Sestamibi in Coronary Artery Disease (CAD)**

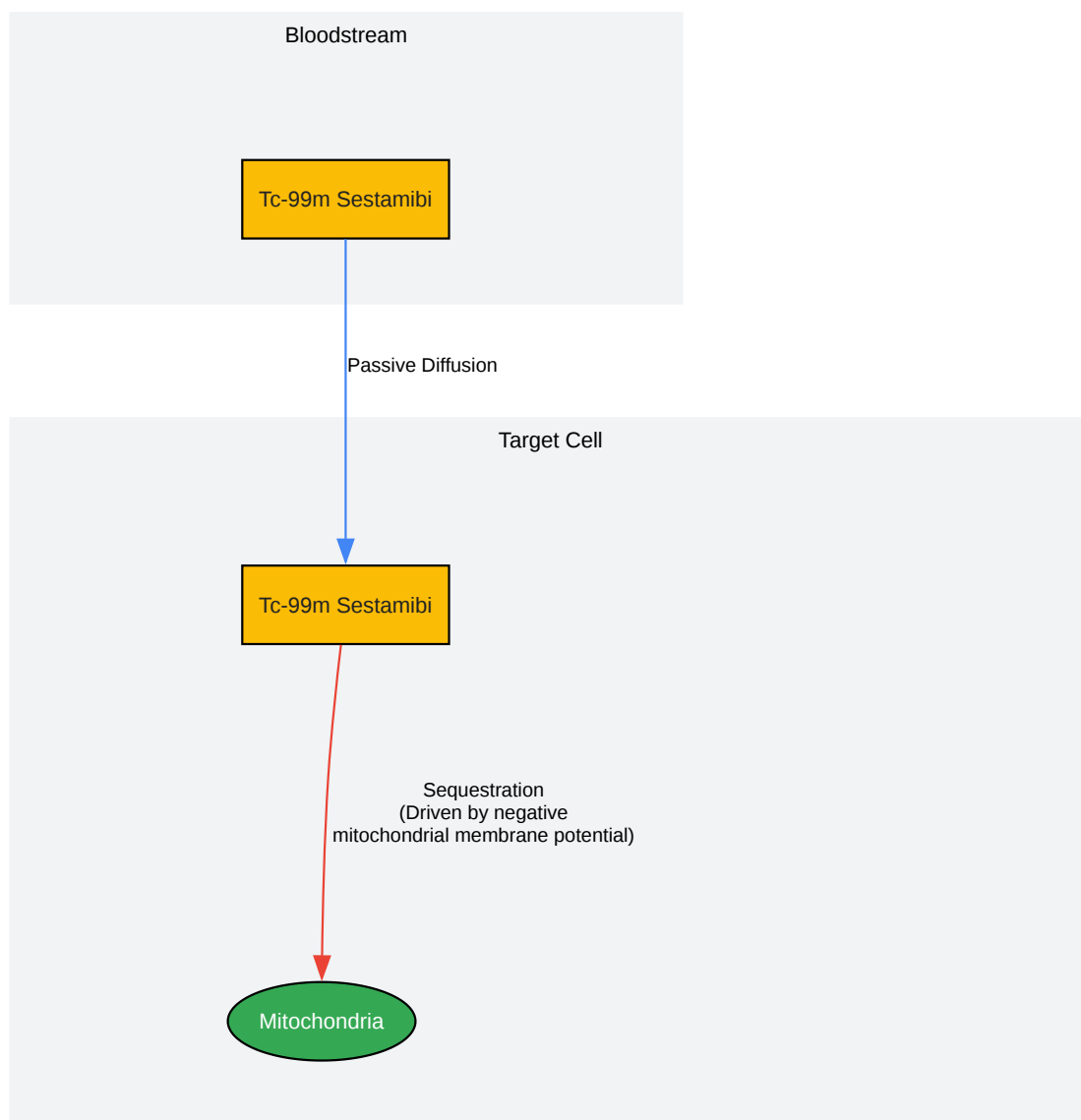
Stress Protocol	Imaging Technique	Sensitivity (%)	Specificity (%)
Exercise Stress	SPECT	~85-90	~70-75
Pharmacological Stress (Dipyridamole)	SPECT	91	28 (in high-risk population)
Pharmacological Stress (Adenosine) in Women	SPECT	93	78

## Experimental Protocols

The methodologies for diagnostic accuracy studies of Technetium-99m Sestamibi share a common workflow but have specific variations depending on the clinical application.

## Signaling Pathway of Technetium-99m Sestamibi Uptake

The uptake of Technetium-99m Sestamibi is primarily driven by the mitochondrial and plasma membrane potentials of metabolically active cells.

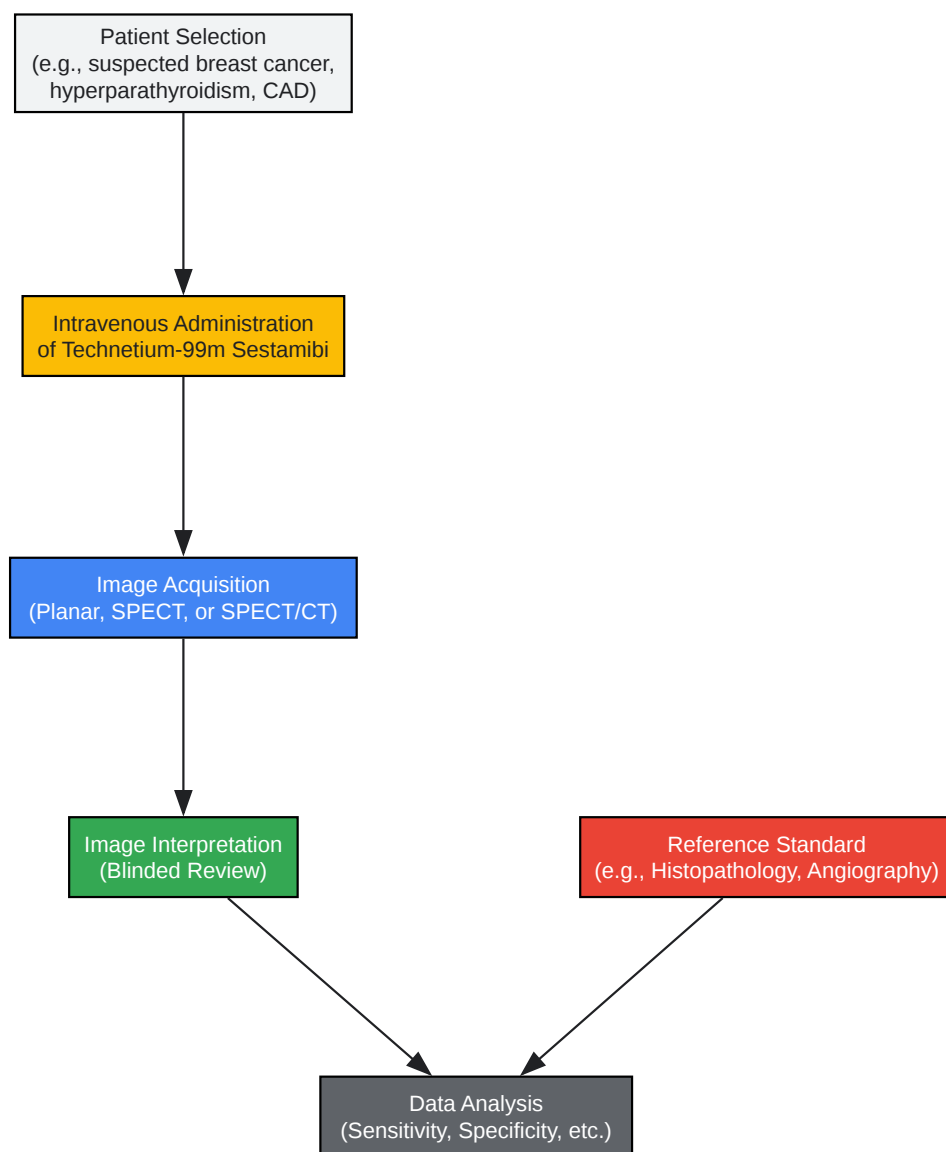


[Click to download full resolution via product page](#)

Cellular uptake of Tc-99m Sestamibi.

## General Experimental Workflow

The following diagram illustrates a typical workflow for a diagnostic accuracy study involving Technetium-99m Sestamibi.



[Click to download full resolution via product page](#)

Diagnostic accuracy study workflow.

## Detailed Methodologies

### 1. Breast Cancer (Scintimammography/Molecular Breast Imaging)

- **Patient Selection:** Patients with suspicious mammographic or clinical findings are recruited. A key exclusion criterion is pregnancy or breastfeeding.
- **Radiopharmaceutical Administration:** 740-1110 MBq (20-30 mCi) of Technetium-99m Sestamibi is injected intravenously in the arm contralateral to the suspected breast lesion.
- **Image Acquisition:** Imaging begins 5-10 minutes post-injection. Planar images in the craniocaudal and mediolateral oblique views are acquired for each breast. For MBI, dedicated breast gamma cameras are used.
- **Image Interpretation:** Images are interpreted by experienced nuclear medicine physicians who are blinded to the results of other imaging modalities and the final diagnosis. Increased focal uptake of the radiotracer is considered indicative of malignancy.
- **Reference Standard:** The gold standard for diagnosis is histopathological examination of biopsy or surgical specimens.

### 2. Hyperparathyroidism

- **Patient Selection:** Patients with biochemical evidence of primary hyperparathyroidism are included.
- **Radiopharmaceutical Administration:** An intravenous injection of 555-925 MBq (15-25 mCi) of Technetium-99m Sestamibi is administered.
- **Image Acquisition:** A dual-phase imaging protocol is commonly used. Early planar images of the neck and mediastinum are acquired 10-20 minutes post-injection, followed by delayed imaging at 1.5-3 hours. SPECT or SPECT/CT may be performed after the early or delayed planar images to improve localization.
- **Image Interpretation:** A focus of persistent or increased tracer activity on delayed images compared to the thyroid gland is indicative of a parathyroid adenoma. SPECT/CT allows for precise anatomical localization of the abnormal gland.

- Reference Standard: Surgical findings and subsequent histopathological confirmation of resected parathyroid tissue serve as the reference standard.

### 3. Coronary Artery Disease (Myocardial Perfusion Imaging)

- Patient Selection: Patients with suspected or known coronary artery disease are enrolled.
- Radiopharmaceutical Administration: A two-dose protocol (rest and stress) is typically employed. For the rest study, 296-444 MBq (8-12 mCi) of Technetium-99m Sestamibi is injected. For the stress study, a higher dose of 740-1110 MBq (20-30 mCi) is administered at peak stress.
- Stress Protocol: Stress can be induced by either physical exercise (treadmill or bicycle) or pharmacological agents such as dipyridamole, adenosine, or regadenoson.
- Image Acquisition: Gated SPECT imaging is performed 15-60 minutes after each injection to assess both myocardial perfusion and ventricular function.
- Image Interpretation: Images from the rest and stress studies are compared to identify areas of reduced tracer uptake. A perfusion defect that is present only on stress images indicates ischemia, while a fixed defect on both rest and stress images suggests prior myocardial infarction.
- Reference Standard: Coronary angiography is the gold standard for the anatomical diagnosis of coronary artery stenosis.
- To cite this document: BenchChem. [Unveiling the Diagnostic Precision of Technetium-99m Sestamibi: A Meta-Analysis Comparison]. BenchChem, [2025]. [Online PDF]. Available at: [\[https://www.benchchem.com/product/b1142544#meta-analysis-of-technetium-sestamibi-diagnostic-performance\]](https://www.benchchem.com/product/b1142544#meta-analysis-of-technetium-sestamibi-diagnostic-performance)

---

#### Disclaimer & Data Validity:

The information provided in this document is for Research Use Only (RUO) and is strictly not intended for diagnostic or therapeutic procedures. While BenchChem strives to provide accurate protocols, we make no warranties, express or implied, regarding the fitness of this product for every specific experimental setup.

**Technical Support:** The protocols provided are for reference purposes. Unsure if this reagent suits your experiment? [[Contact our Ph.D. Support Team for a compatibility check](#)]

**Need Industrial/Bulk Grade?** [Request Custom Synthesis Quote](#)

## BenchChem

Our mission is to be the trusted global source of essential and advanced chemicals, empowering scientists and researchers to drive progress in science and industry.

### Contact

Address: 3281 E Guasti Rd  
Ontario, CA 91761, United States  
Phone: (601) 213-4426  
Email: [info@benchchem.com](mailto:info@benchchem.com)