

Unveiling Cardiac Pathology: A Comparative Guide to 99mTc-PYP Uptake and Histological Findings

Author: BenchChem Technical Support Team. **Date:** December 2025

Compound of Interest

Compound Name: *Hynic-ctp*

Cat. No.: *B15559713*

[Get Quote](#)

For Researchers, Scientists, and Drug Development Professionals

This guide provides a comprehensive comparison of 99mTc-pyrophosphate (PYP) scintigraphy, often referred to as **Hynic-ctp** in broader radiopharmaceutical contexts, with gold-standard histological findings in heart tissue. We delve into its application in diagnosing and evaluating cardiac amyloidosis and myocardial infarction, presenting supporting experimental data, detailed protocols, and visual workflows to aid in research and development.

Section 1: 99mTc-PYP in Cardiac Amyloidosis

Technetium-99m pyrophosphate (99mTc-PYP) scintigraphy has emerged as a highly accurate, non-invasive imaging modality for the diagnosis of transthyretin cardiac amyloidosis (ATTR-CA).[1][2] Its diagnostic power lies in the avidity of the radiotracer for amyloid fibrils rich in calcium microcalcifications.[3][4]

Quantitative Imaging vs. Histological Burden

The uptake of 99mTc-PYP in the myocardium is quantitatively assessed using two primary methods: the semi-quantitative Perugini score and the heart-to-contralateral lung (H/CL) ratio.[5][6][7] The Perugini score is a visual grading of myocardial uptake relative to rib uptake, while the H/CL ratio provides a more objective measure of tracer retention.[5][6] Studies have

demonstrated a significant positive correlation between these imaging metrics and the histological amyloid load determined from endomyocardial biopsies.[8]

Imaging Parameter	Correlation with Histological Amyloid Load (r-value)	p-value	Reference
Perugini Score	0.69	<0.001	[8]
Planar Scintigraphy (ROI mean)	0.64	<0.001	[8]
SPECT/CT (ROI mean)	0.53	0.008	[8]
Heart-to-Contralateral Lung (H/CL) Ratio	0.43	0.037	[8]

A study on a similar bone-avid tracer, 99mTc-DPD, demonstrated these correlations with Congo Red-stained histological sections.

Comparative Performance of Radiotracers

While 99mTc-PYP is a widely used agent, 99mTc-hydroxymethylene diphosphonate (HMDP) has proven to be a reliable alternative, especially in times of 99mTc-PYP shortages. A meta-analysis comparing the diagnostic performance of these bone-avid tracers for ATTR-CA revealed comparable sensitivities and specificities.

Radiotracer	Sensitivity for ATTR-CA	Specificity for ATTR-CA	Reference
99mTc-PYP	97.44%	93.75%	[6]
99mTc-HMDP	98.33%	98.59%	[6]
99mTc-DPD	99.58%	87.55%	[6]

Section 2: 99mTc-PYP in Myocardial Infarction

Historically, 99mTc-PYP was a primary tool for imaging acute myocardial infarction.^[9] Its uptake is dependent on both the degree of myocardial necrosis and the residual blood flow to the infarcted area.^[10] The tracer is believed to bind to calcium deposits within the necrotic myocytes.^{[9][11]}

Tracer Uptake and Degree of Myocardial Injury

Experimental studies have quantified the relationship between the duration of ischemia and the subsequent 99mTc-PYP uptake, demonstrating a progressive increase in tracer accumulation with more prolonged ischemic events that lead to irreversible cell injury and infarction.

Ischemia Duration	99mTc-PYP Uptake Ratio (Ischemic/Normal Area)	Histological Outcome	Reference
10 minutes	1.18 ± 0.009	Reversible Injury	^[11]
30 minutes	4.09 ± 1.75	Severe Injury, some necrosis	^[11]
60 minutes	12.2 ± 2.9 (transmural)	Myocardial Infarction	^[11]

Section 3: Experimental Protocols

99mTc-PYP Cardiac Imaging Protocol

This protocol is a synthesis of common practices for the diagnosis of cardiac amyloidosis.

- **Patient Preparation:** No specific preparation, such as fasting, is required.
- **Radiopharmaceutical Administration:** An intravenous injection of 10-20 mCi (370-740 MBq) of 99mTc-PYP is administered.
- **Imaging Timepoints:** Planar and SPECT/CT imaging are typically performed 1 hour and/or 3 hours post-injection. If significant blood pool activity is present at 1 hour, 3-hour imaging is

recommended.[6]

- Planar Imaging Acquisition:
 - Acquire anterior, left anterior oblique (LAO), and left lateral views.
 - Acquire for a set number of counts (e.g., 750,000) per view.
- SPECT/CT Imaging Acquisition:
 - Perform a 180° or 360° acquisition over the chest.
 - Use a low-energy, high-resolution (LEHR) collimator.
 - Acquire in a 64x64 or 128x128 matrix.
- Image Analysis:
 - Perugini Score: Visually grade myocardial uptake on a scale of 0 to 3 by comparing it to rib uptake (0 = no uptake; 1 = uptake less than ribs; 2 = uptake equal to ribs; 3 = uptake greater than ribs).[5]
 - H/CL Ratio: Draw a region of interest (ROI) over the heart on the anterior planar view and an identical ROI over the contralateral lung. Calculate the ratio of the mean counts in the heart ROI to the mean counts in the contralateral lung ROI. A ratio ≥ 1.5 at 1 hour is considered highly suggestive of ATTR-CA.[1][7]

Histological Staining for Cardiac Amyloidosis (Congo Red)

This protocol outlines the standard procedure for identifying amyloid deposits in heart tissue.

- Tissue Preparation:
 - Fix endomyocardial biopsy or autopsy heart tissue in 10% neutral buffered formalin.
 - Process and embed the tissue in paraffin.

- Cut sections at 8-10 μm thickness. Thicker sections enhance the birefringence.
- Staining Procedure:
 - Deparaffinize and hydrate tissue sections to distilled water.
 - Stain with an alkaline Congo Red solution for 20-60 minutes.
 - Rinse with distilled water.
 - Differentiate briefly in an alkaline alcohol solution.
 - Counterstain with Mayer's hematoxylin.
 - Dehydrate through graded alcohols and clear in xylene.
 - Mount with a synthetic resinous medium.
- Microscopic Analysis:
 - Under standard light microscopy, amyloid deposits will appear pink to red.
 - Under a polarizing microscope, amyloid deposits will exhibit a pathognomonic apple-green birefringence.

Histological Staining for Myocardial Infarction (Triphenyltetrazolium Chloride - TTC)

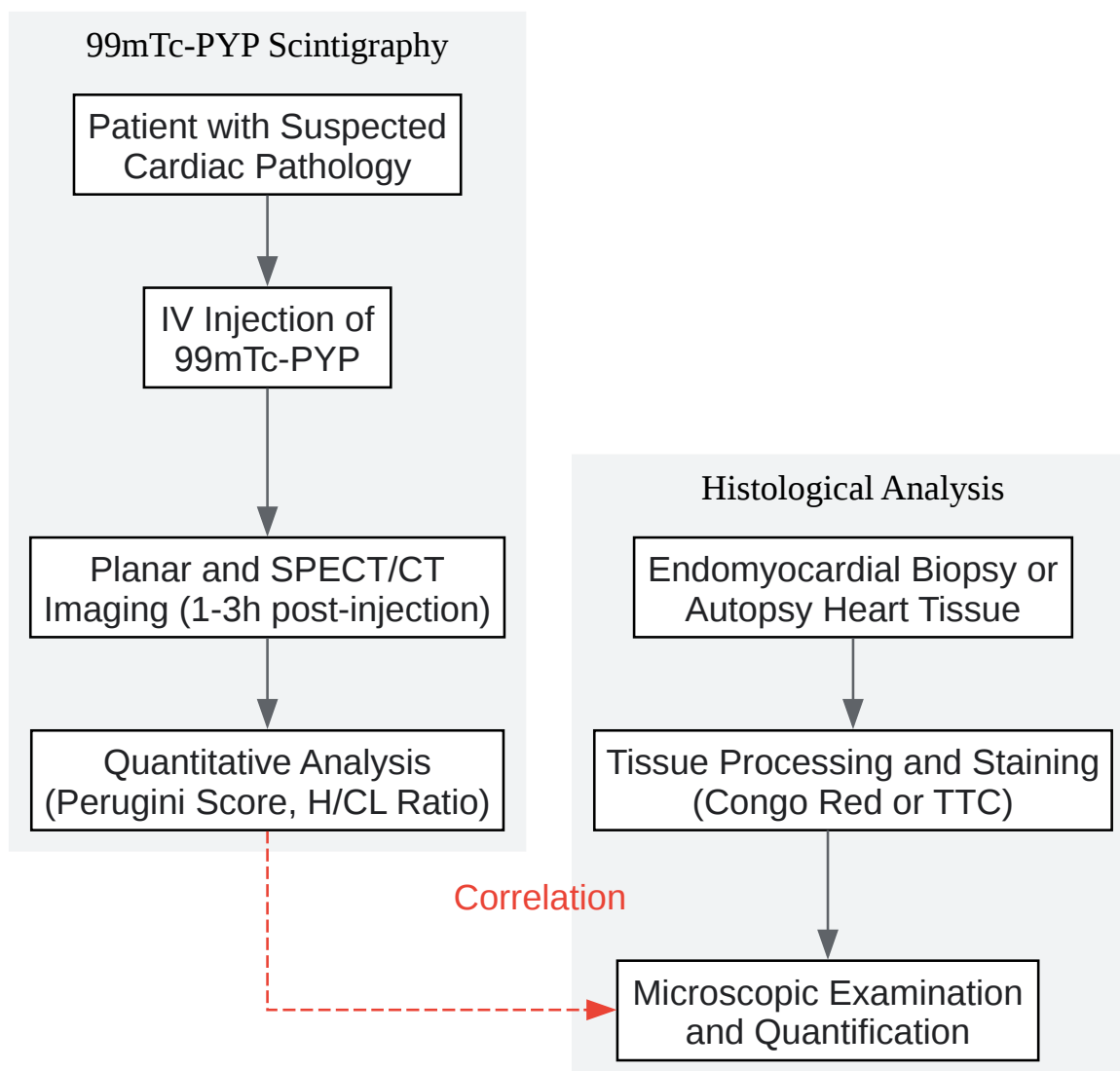
This protocol is used to grossly delineate infarcted from viable myocardium.

- Tissue Preparation:
 - Excise the heart and slice the ventricles transversely into uniform sections (e.g., 1 cm thick).
- Staining Procedure:
 - Prepare a 1% solution of TTC in a phosphate buffer (pH 7.4).

- Immerse the heart slices in the TTC solution and incubate at 37°C for 20-30 minutes.
- Analysis:
 - Viable myocardium, containing active dehydrogenase enzymes, will stain a brick red color.
 - Infarcted myocardium, lacking these enzymes, will remain pale or white.
 - The slices can be photographed, and the area of infarction can be quantified using planimetry software as a percentage of the total ventricular area.

Section 4: Visualizing the Pathways and Processes

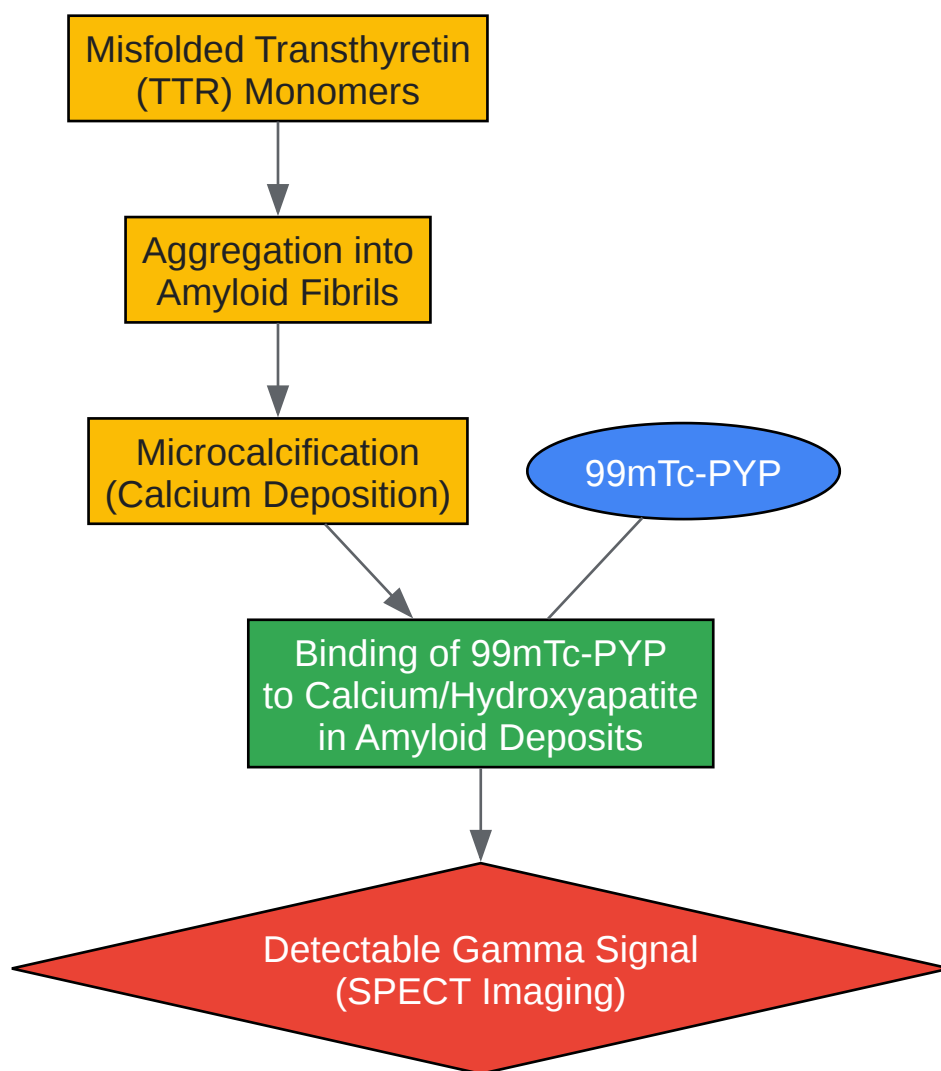
Experimental Workflow



[Click to download full resolution via product page](#)

Caption: Experimental workflow from patient imaging to histological correlation.

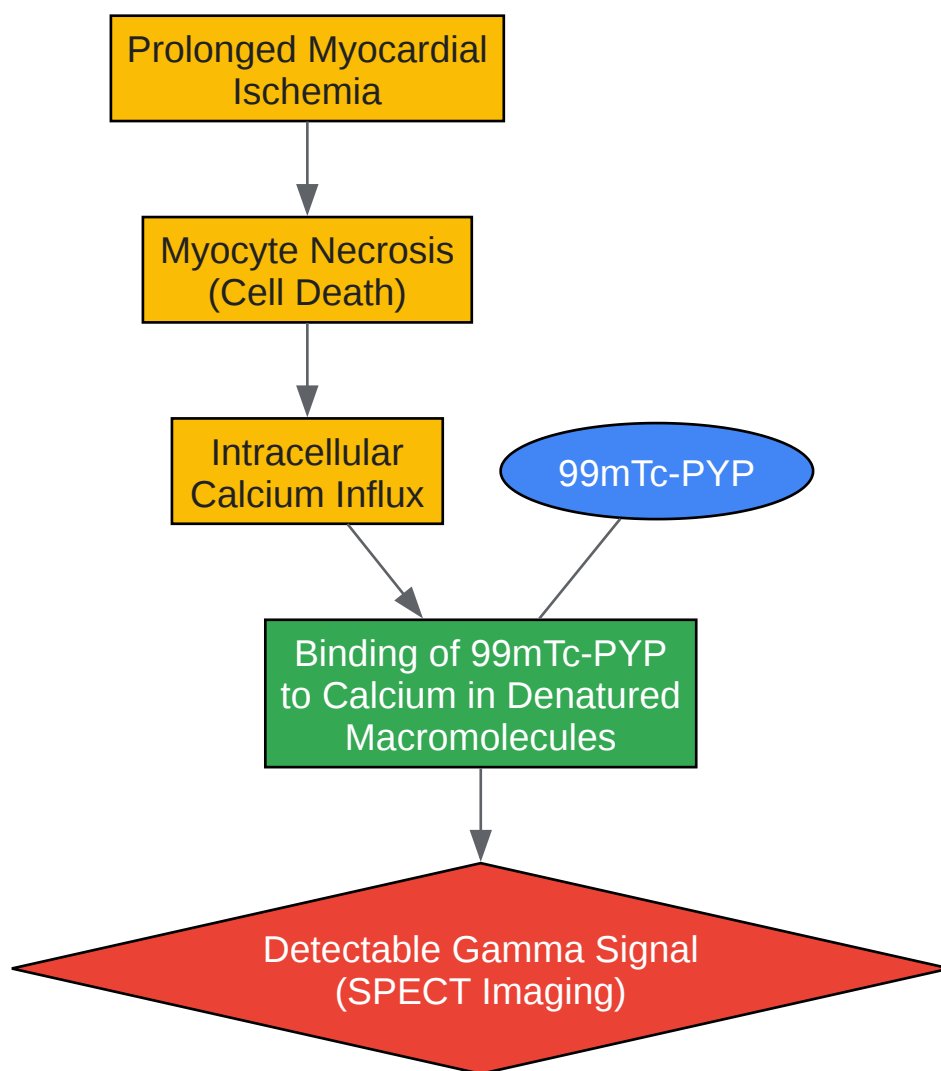
Proposed Mechanism of 99mTc-PYP Uptake in Cardiac Amyloidosis



[Click to download full resolution via product page](#)

Caption: ^{99m}Tc-PYP uptake mechanism in transthyretin cardiac amyloidosis.

Proposed Mechanism of ^{99m}Tc-PYP Uptake in Myocardial Infarction



[Click to download full resolution via product page](#)

Caption: 99mTc-PYP uptake mechanism in acute myocardial infarction.

Need Custom Synthesis?

BenchChem offers custom synthesis for rare earth carbides and specific isotopic labeling.

Email: info@benchchem.com or [Request Quote Online](#).

References

- 1. 99mTc-Pyrophosphate scintigraphy for differentiating light-chain cardiac amyloidosis from the transthyretin-related familial and senile cardiac amyloidoses - PMC

[pmc.ncbi.nlm.nih.gov]

- 2. 99mTc Bone-Avid Tracer Cardiac Scintigraphy: Role in Noninvasive Diagnosis of Transthyretin Cardiac Amyloidosis - PMC [pmc.ncbi.nlm.nih.gov]
- 3. Microcalcification and 99mTc-Pyrophosphate Uptake without Increased Bone Metabolism in Cardiac Tissue from Patients with Transthyretin Cardiac Amyloidosis - PMC [pmc.ncbi.nlm.nih.gov]
- 4. geiselmed.dartmouth.edu [geiselmed.dartmouth.edu]
- 5. asnc.org [asnc.org]
- 6. arci.org [arci.org]
- 7. Correlation of 99mTc-DPD bone scintigraphy with histological amyloid load in patients with ATTR cardiac amyloidosis - PubMed [pubmed.ncbi.nlm.nih.gov]
- 8. appliedradiology.com [appliedradiology.com]
- 9. Mechanism of localization of 99mTc-labeled pyrophosphate and tetracycline in infarcted myocardium - PubMed [pubmed.ncbi.nlm.nih.gov]
- 10. Technetium-99m-pyrophosphate uptake as an indicator of myocardial injury without infarct - PubMed [pubmed.ncbi.nlm.nih.gov]
- 11. Serial scanning with technetium pyrophosphate (99mTc-PYP) in advanced ATTR cardiac amyloidosis - PMC [pmc.ncbi.nlm.nih.gov]
- To cite this document: BenchChem. [Unveiling Cardiac Pathology: A Comparative Guide to 99mTc-PYP Uptake and Histological Findings]. BenchChem, [2025]. [Online PDF]. Available at: [https://www.benchchem.com/product/b15559713#correlation-of-hynic-ctp-uptake-with-histological-findings-in-heart-tissue]

Disclaimer & Data Validity:

The information provided in this document is for Research Use Only (RUO) and is strictly not intended for diagnostic or therapeutic procedures. While BenchChem strives to provide accurate protocols, we make no warranties, express or implied, regarding the fitness of this product for every specific experimental setup.

Technical Support: The protocols provided are for reference purposes. Unsure if this reagent suits your experiment? [[Contact our Ph.D. Support Team for a compatibility check](#)]

Need Industrial/Bulk Grade? [Request Custom Synthesis Quote](#)

BenchChem

Our mission is to be the trusted global source of essential and advanced chemicals, empowering scientists and researchers to drive progress in science and industry.

Contact

Address: 3281 E Guasti Rd

Ontario, CA 91761, United States

Phone: (601) 213-4426

Email: info@benchchem.com