

# Ultrasound Outperforms Radiography in Chondrocalcinosis Detection, Studies Show

**Author:** BenchChem Technical Support Team. **Date:** December 2025

## Compound of Interest

Compound Name: *Calcium pyrophosphate*

Cat. No.: *B7822615*

[Get Quote](#)

For researchers, scientists, and drug development professionals, emerging evidence indicates that ultrasound is a more sensitive and reliable tool for the detection of chondrocalcinosis, the deposition of **calcium pyrophosphate** dihydrate (CPPD) crystals in articular cartilage, when compared to traditional radiography. Multiple studies demonstrate that ultrasound not only has higher sensitivity in identifying these crystal deposits but also offers a non-invasive, radiation-free alternative for the diagnosis and monitoring of this condition.

Chondrocalcinosis is a hallmark of CPPD, a common inflammatory arthritis.<sup>[1]</sup> Accurate detection is crucial for correct diagnosis and management. While radiography has been the standard imaging modality, its limitations in visualizing non-calcified or minimally calcified deposits have been a significant drawback.<sup>[1][2]</sup> Ultrasound, with its ability to visualize soft tissues and subtle calcifications, is proving to be a superior diagnostic tool.<sup>[1][3]</sup>

## Quantitative Comparison of Diagnostic Accuracy

A review of several key studies highlights the superior performance of ultrasound over radiography in detecting chondrocalcinosis. The data, summarized in the table below, consistently shows higher sensitivity for ultrasound, with comparable or slightly lower specificity in some cases. The gold standard for diagnosis in these studies was typically the identification of CPPD crystals in synovial fluid or through histological examination.<sup>[4][5]</sup>

Study (Joint)	Modality	Sensitivity	Specificity	Reference Standard
Filippou et al. (Knee)	Ultrasound	96%	87%	Histology[5][6]
Radiography	75%	93%	Histology[5][6]	
Ottaviani et al. (Knee)	Ultrasound	100%	92.3%	CPP Crystal ID[7]
Radiography	64%	100%	CPP Crystal ID[7]	
Ellabban et al. (Knee, Shoulder, Wrist)	Ultrasound	84.2%	100%	Synovial Fluid Analysis[2][8]
Radiography	13.2%	100%	Synovial Fluid Analysis[2][8]	
Forein et al. (Wrist)	Ultrasound	94%	85%	Clinical Diagnosis
Radiography	53.1%	100%	Clinical Diagnosis[6]	
Cipolletta et al. (Wrist)	Ultrasound	95%	85%	Clinical Diagnosis
Radiography	72%	100%	Clinical Diagnosis[6]	
Gutierrez et al. (Knee)	Ultrasound (Hyaline Cartilage)	59.5%	-	Clinical Diagnosis[6][9]
Radiography (Hyaline Cartilage)	45.9%	-	Clinical Diagnosis[6][9]	
Ultrasound (Meniscal)	90.5%	-	Clinical Diagnosis[9]	

Fibrocartilage)

Radiography

(Meniscal

83.7%

-

Clinical

Diagnosis[9]

Fibrocartilage)

## Experimental Protocols

The methodologies employed in these validation studies are crucial for understanding the context of the presented data. Below are detailed experimental protocols for both ultrasound and radiography for the detection of chondrocalcinosis.

### Ultrasound Examination Protocol

- **Patient Population:** Patients presenting with joint effusion or suspicion of inflammatory arthritis were typically recruited.[7][8] Exclusion criteria often included known cases of chondrocalcinosis, gout, or autoimmune diseases.[2]
- **Equipment:** High-frequency linear array transducers (typically 10-18 MHz) are used for optimal visualization of superficial joint structures.[10]
- **Scanning Technique:**
  - **Joints Examined:** The most commonly assessed joints are the knees and wrists, as they are frequently affected by chondrocalcinosis.[6][10][11] Other joints like the shoulders, elbows, and hips may also be included.[8]
  - **Knee Examination:** The patient is positioned supine with the knee in maximal flexion. Longitudinal and transverse scans are performed over the medial and lateral femoral condyles and menisci.[9]
  - **Wrist Examination:** The dorsal aspect of the wrist is examined with the hand in a neutral position to visualize the triangular fibrocartilage complex (TFCC) and the radiocarpal and midcarpal joints.[6]
- **Sonographic Findings:** The characteristic findings of chondrocalcinosis on ultrasound include:

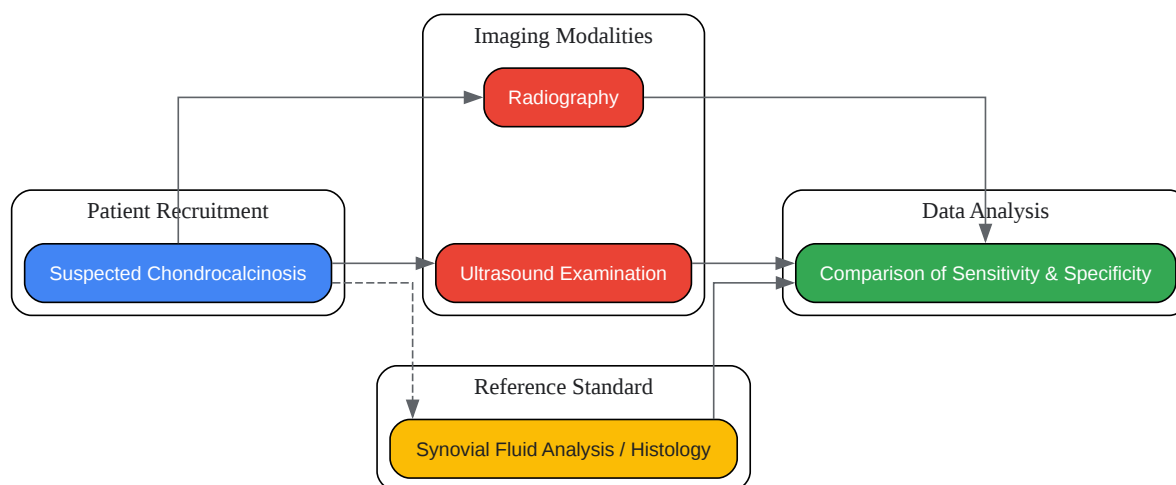
- Hyperechoic dots or lines running parallel to the joint surface within the hyaline cartilage. [3]
- Punctate hyperechoic spots within the fibrocartilage of the menisci or TFCC. [3][6]
- Homogeneous hyperechoic nodular or oval deposits. [6]
- Reference Standard: The gold standard for confirming chondrocalcinosis is the microscopic identification of **calcium pyrophosphate** dihydrate (CPPD) crystals in synovial fluid obtained through arthrocentesis or in tissue samples via histology. [4][5]

### Radiography Protocol

- Patient Population: Similar patient cohorts as in the ultrasound studies are used.
- Equipment: Standard digital radiography equipment is utilized.
- Imaging Technique:
  - Joints Examined: A screening survey often includes anteroposterior (AP) views of both knees, an AP view of the pelvis (to visualize the symphysis pubis and hips), and posteroanterior (PA) views of both hands and wrists. [1]
  - Knee Examination: Anteroposterior and lateral views are standard. Weight-bearing views are often preferred to assess joint space narrowing.
  - Wrist Examination: Posteroanterior and lateral views are obtained.
- Radiographic Findings: Chondrocalcinosis appears as linear or punctate calcifications within the hyaline or fibrocartilage. [12]
- Reference Standard: As with ultrasound, synovial fluid analysis or histology serves as the definitive diagnostic standard. [4][5]

## Visualizing the Validation Workflow

The logical flow of a typical validation study comparing ultrasound and radiography for chondrocalcinosis detection can be visualized as follows:



[Click to download full resolution via product page](#)

Caption: Validation workflow for ultrasound vs. radiography in chondrocalcinosis detection.

In conclusion, the available evidence strongly supports the use of ultrasound as a primary imaging modality for the detection of chondrocalcinosis. Its higher sensitivity, non-invasive nature, and lack of ionizing radiation make it a valuable tool for clinicians and researchers. While radiography remains a widely available and specific method, its lower sensitivity may lead to underdiagnosis of this common condition.[1][2] Future research and clinical practice guidelines should consider integrating ultrasound more prominently into the diagnostic pathway for suspected chondrocalcinosis.

#### Need Custom Synthesis?

BenchChem offers custom synthesis for rare earth carbides and specific isotopic labeling.

Email: [info@benchchem.com](mailto:info@benchchem.com) or [Request Quote Online](#).

## References

- 1. Diagnosis and Treatment of Calcium Pyrophosphate Deposition (CPPD) Disease: A Review - PMC [pmc.ncbi.nlm.nih.gov]
- 2. Imaging of Calcium Pyrophosphate Deposition Disease - PMC [pmc.ncbi.nlm.nih.gov]
- 3. Ultrasonography in chondrocalcinosis - PubMed [pubmed.ncbi.nlm.nih.gov]
- 4. A “new” technique for the diagnosis of chondrocalcinosis of the knee: sensitivity and specificity of high-frequency ultrasonography - PMC [pmc.ncbi.nlm.nih.gov]
- 5. clinexprheumatol.org [clinexprheumatol.org]
- 6. emedicine.medscape.com [emedicine.medscape.com]
- 7. Sensitivity and Reproducibility of Ultrasonography in Calcium Pyrophosphate Crystal Deposition in Knee Cartilage: A Cross-sectional Study - PubMed [pubmed.ncbi.nlm.nih.gov]
- 8. Ultrasonographic diagnosis of articular chondrocalcinosis - PubMed [pubmed.ncbi.nlm.nih.gov]
- 9. Ultrasound detection of cartilage calcification at knee level in calcium pyrophosphate deposition disease - PubMed [pubmed.ncbi.nlm.nih.gov]
- 10. Ultrasonographic Assessment of Calcium Pyrophosphate Deposition Disease: A Comprehensive Review - PMC [pmc.ncbi.nlm.nih.gov]
- 11. mdpi.com [mdpi.com]
- 12. An Update on the Diagnosis and Management of Calcium Crystal Disease - PMC [pmc.ncbi.nlm.nih.gov]
- To cite this document: BenchChem. [Ultrasound Outperforms Radiography in Chondrocalcinosis Detection, Studies Show]. BenchChem, [2025]. [Online PDF]. Available at: [https://www.benchchem.com/product/b7822615#validation-of-ultrasound-against-radiography-for-chondrocalcinosis-detection]

---

### Disclaimer & Data Validity:

The information provided in this document is for Research Use Only (RUO) and is strictly not intended for diagnostic or therapeutic procedures. While BenchChem strives to provide accurate protocols, we make no warranties, express or implied, regarding the fitness of this product for every specific experimental setup.

**Technical Support:** The protocols provided are for reference purposes. Unsure if this reagent suits your experiment? [[Contact our Ph.D. Support Team for a compatibility check](#)]

**Need Industrial/Bulk Grade?** [Request Custom Synthesis Quote](#)

## BenchChem

Our mission is to be the trusted global source of essential and advanced chemicals, empowering scientists and researchers to drive progress in science and industry.

### Contact

Address: 3281 E Guasti Rd  
Ontario, CA 91761, United States  
Phone: (601) 213-4426  
Email: [info@benchchem.com](mailto:info@benchchem.com)