

Troubleshooting poor gallbladder visualization in HIDA scans

Author: BenchChem Technical Support Team. **Date:** December 2025

Compound of Interest

Compound Name: Mebrofenin

Cat. No.: B129125

[Get Quote](#)

Technical Support Center: Troubleshooting HIDA Scans

Welcome to the technical support center for troubleshooting poor gallbladder visualization in hepatobiliary iminodiacetic acid (HIDA) scans. This resource is designed for researchers, scientists, and drug development professionals to address common issues encountered during these imaging experiments.

Frequently Asked Questions (FAQs)

Q1: What is the primary cause of gallbladder non-visualization in a HIDA scan?

A1: The most common reason for the gallbladder not to be visualized within the standard imaging time (up to 4 hours) is an obstruction of the cystic duct.^[1] This obstruction prevents the radiotracer from entering the gallbladder and is a strong indicator of acute cholecystitis.^[1]^[2]^[3]

Q2: Can factors other than acute cholecystitis lead to poor or non-visualization of the gallbladder?

A2: Yes, several conditions can result in "false-positive" non-visualization, where the gallbladder fails to appear despite the absence of acute cholecystitis. These factors include:

- **Improper Patient Preparation:** Inadequate fasting (less than 4 hours) or prolonged fasting (more than 24 hours) can affect results.
- **Severe Liver Disease:** Impaired liver function can lead to poor uptake and excretion of the HIDA radiotracer.
- **Total Parenteral Nutrition (TPN):** Patients on TPN may experience gallbladder stasis, preventing the tracer from entering.
- **Critical Illness:** Critically ill patients may exhibit gallbladder abnormalities without having acute cholecystitis.
- **Chronic Cholecystitis:** Severe chronic inflammation can lead to a shrunken, non-functional gallbladder that doesn't visualize.
- **High-Grade Biliary Obstruction:** Obstruction of the common bile duct can prevent the tracer from reaching the biliary tree.

Q3: What is a normal timeframe for gallbladder visualization in a HIDA scan?

A3: In a healthy individual, the gallbladder should be visualized within one hour of injecting the radiotracer. Visualization that occurs later (up to 4 hours) may be indicative of chronic cholecystitis.

Q4: What is the role of morphine in a HIDA scan when the gallbladder is not visualized?

A4: If the gallbladder is not seen within 60 minutes, morphine can be administered intravenously. Morphine causes the sphincter of Oddi to contract, which increases pressure within the common bile duct and promotes the flow of the radiotracer into the gallbladder if the cystic duct is patent. Non-visualization 30 minutes after morphine administration is highly indicative of acute cholecystitis.

Q5: When is cholecystokinin (CCK) or its analogue, sincalide, used in HIDA scans?

A5: CCK or sincalide is used for two main purposes:

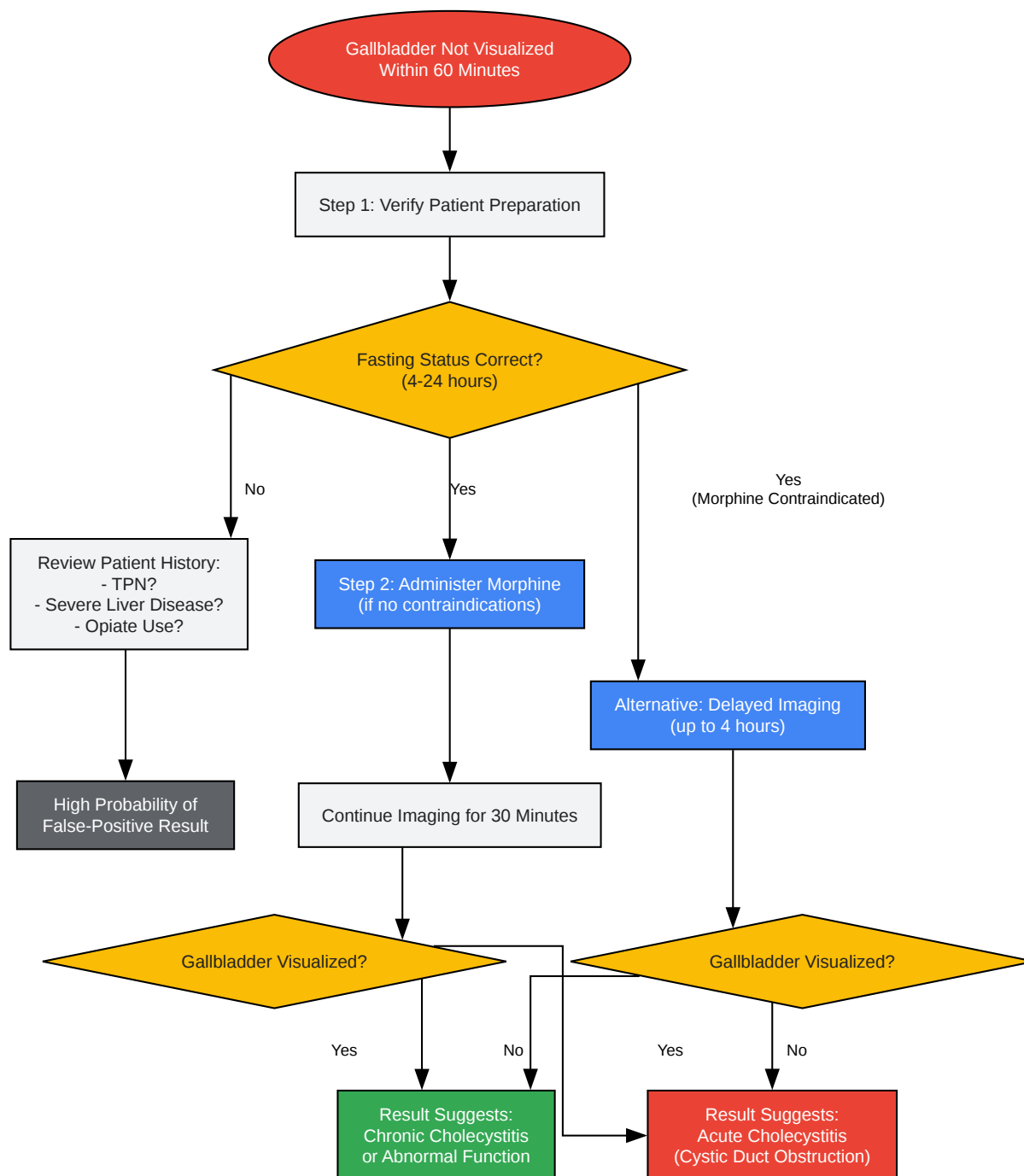
- **Pre-treatment for Prolonged Fasting:** For patients fasting longer than 24 hours, pre-treatment with sincalide can empty the gallbladder of concentrated bile, reducing the risk of a false-positive result.
- **Gallbladder Ejection Fraction (GBEF) Measurement:** After the gallbladder is visualized, CCK is administered to stimulate gallbladder contraction. The GBEF is then calculated to assess gallbladder function, which is useful in diagnosing chronic cholecystitis.

Troubleshooting Guide for Poor Gallbladder Visualization

This guide provides a systematic approach to identifying and resolving issues related to poor gallbladder visualization during HIDA scans.

Issue 1: Gallbladder Not Visualized Within 60 Minutes

This is the most common issue. Follow this workflow to determine the cause and appropriate next steps.



[Click to download full resolution via product page](#)

Caption: Troubleshooting workflow for non-visualization at 60 minutes.

Issue 2: Suspected False-Positive Due to Patient Status

Certain patient conditions can lead to non-visualization even with a patent cystic duct.

Patient Condition	Cause of Poor Visualization	Recommended Action
Prolonged Fasting (>24 hours)	Gallbladder is full of viscous bile, preventing entry of the radiotracer.	Pre-treat with Sincalide (CCK) 30-60 minutes before the radiotracer to empty the gallbladder.
Total Parenteral Nutrition (TPN)	Lack of oral intake leads to gallbladder stasis.	Pre-treat with Sincalide (CCK) as with prolonged fasting.
Severe Hepatocellular Disease	Impaired liver cells cannot efficiently take up and excrete the radiotracer into the bile.	HIDA scan may not be diagnostic. Consider alternative imaging modalities.
Recent Opiate Use	Opiates like morphine can cause sphincter of Oddi spasm, mimicking a blockage.	Discontinue opiates for at least 6 hours prior to the scan.

Key Experimental Protocols

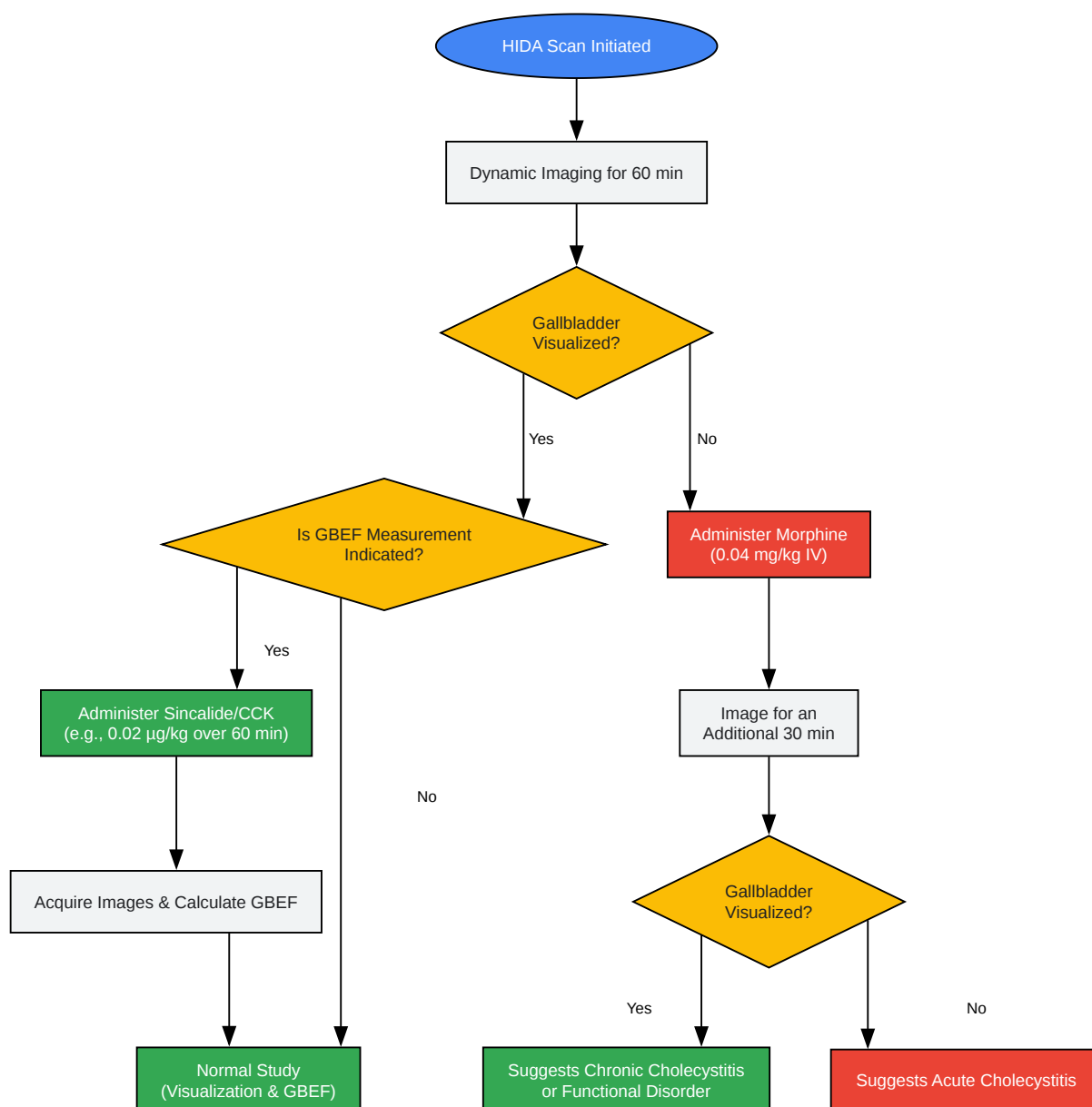
Standard HIDA Scan Protocol for Gallbladder Visualization

- Patient Preparation: Ensure the patient has fasted for a minimum of 4 hours but no more than 24 hours. Confirm no recent opiate use.
- Radiotracer Administration: Intravenously inject a standard dose of a ^{99m}Tc -labeled HIDA agent (e.g., **Mebrofenin**).
- Imaging Acquisition:
 - Begin dynamic imaging immediately after injection.
 - Acquire images at 1-minute intervals for 60 minutes.

- Initial Interpretation:
 - Normal: Gallbladder is visualized within 60 minutes.
 - Abnormal: Gallbladder is not visualized within 60 minutes. Proceed to the appropriate intervention protocol.

Pharmacological Intervention Protocols

The logical flow for deciding on and applying pharmacological interventions is crucial for accurate diagnosis.



[Click to download full resolution via product page](#)

Caption: Decision pathway for pharmacological interventions in HIDA scans.

Intervention	Dosage	Administration	Purpose
Morphine Sulfate	0.04 mg/kg	Intravenous (IV)	To augment gallbladder filling when not visualized by 60 minutes.
Sincalide (CCK-8)	0.02 µg/kg	IV infusion over 30-60 minutes	Pre-treatment for prolonged fasting or to measure Gallbladder Ejection Fraction (GBEF).

Note on GBEF: A gallbladder ejection fraction of less than 35% is generally considered abnormal and may indicate chronic acalculous cholecystitis.

Need Custom Synthesis?

BenchChem offers custom synthesis for rare earth carbides and specific isotopic labeling.

Email: info@benchchem.com or [Request Quote Online](#).

References

- 1. Untitled Document [meddean.luc.edu]
- 2. HIDA scan - Mayo Clinic [mayoclinic.org]
- 3. droracle.ai [droracle.ai]
- To cite this document: BenchChem. [Troubleshooting poor gallbladder visualization in HIDA scans]. BenchChem, [2025]. [Online PDF]. Available at: [\[https://www.benchchem.com/product/b129125#troubleshooting-poor-gallbladder-visualization-in-hida-scans\]](https://www.benchchem.com/product/b129125#troubleshooting-poor-gallbladder-visualization-in-hida-scans)

Disclaimer & Data Validity:

The information provided in this document is for Research Use Only (RUO) and is strictly not intended for diagnostic or therapeutic procedures. While BenchChem strives to provide

accurate protocols, we make no warranties, express or implied, regarding the fitness of this product for every specific experimental setup.

Technical Support: The protocols provided are for reference purposes. Unsure if this reagent suits your experiment? [[Contact our Ph.D. Support Team for a compatibility check](#)]

Need Industrial/Bulk Grade? [Request Custom Synthesis Quote](#)

BenchChem

Our mission is to be the trusted global source of essential and advanced chemicals, empowering scientists and researchers to drive progress in science and industry.

Contact

Address: 3281 E Guasti Rd
Ontario, CA 91761, United States
Phone: (601) 213-4426
Email: info@benchchem.com