

Troubleshooting artifacts in Iofetamine SPECT imaging

Author: BenchChem Technical Support Team. **Date:** December 2025

Compound of Interest

Compound Name: Iofetamine

Cat. No.: B3416847

[Get Quote](#)

Technical Support Center: Iofetamine SPECT Imaging

Welcome to the technical support center for **Iofetamine** SPECT imaging. This resource is designed for researchers, scientists, and drug development professionals to help troubleshoot and resolve common artifacts and issues encountered during imaging experiments.

Frequently Asked Questions (FAQs)

Q1: What is **Iofetamine** (IMP) SPECT imaging used for?

A1: **Iofetamine** hydrochloride I-123 (also known as IMP) is a radiopharmaceutical used for cerebral blood perfusion imaging with Single Photon Emission Computed Tomography (SPECT). It is a valuable tool in the evaluation of various neurological conditions, including stroke, dementia, and epilepsy, by providing functional images of the brain.[\[1\]](#)

Q2: What are the most common sources of artifacts in SPECT imaging?

A2: Artifacts in SPECT imaging can arise from three main sources: patient-related factors (e.g., motion, soft tissue attenuation), technical issues (e.g., equipment malfunction, incorrect reconstruction parameters), and radiopharmaceutical-specific factors (e.g., biodistribution).[\[2\]](#)
[\[3\]](#)

Q3: How does patient preparation impact the quality of **Iofetamine** SPECT images?

A3: Proper patient preparation is crucial for obtaining high-quality **lofetamine** SPECT images. Inadequate preparation can lead to artifacts that may obscure or mimic pathological findings. Key aspects of patient preparation include ensuring patient comfort to minimize motion, providing clear instructions, and managing medications that may interfere with cerebral blood flow.^[4]

Troubleshooting Guides

This section provides detailed troubleshooting for specific artifacts that may be encountered during **lofetamine** SPECT imaging.

Patient Motion Artifacts

Issue: Images appear blurry, with misregistration of anatomical structures or artificial defects.

Cause: Patient movement during the scan is a common cause of image degradation in SPECT imaging.^{[5][6]} Motion can be gradual or abrupt and can significantly impact the diagnostic quality of the images.^[2]

Solution:

- Prevention:
 - Thoroughly explain the procedure to the patient to improve cooperation.^[2]
 - Ensure the patient is in a comfortable and stable position before starting the acquisition.
 - Use head restraints or other immobilization devices when appropriate.
- Detection:
 - Visually inspect the raw projection data (sinogram) for discontinuities or shifts.
 - Review the reconstructed images for blurring or "double" contours.
- Correction:
 - If motion is detected during the scan, the acquisition may need to be repeated.

- Some modern imaging systems have motion correction software that can retrospectively correct for minor movements.[\[6\]](#)

Attenuation Artifacts

Issue: Apparent areas of reduced tracer uptake that do not correspond to a true physiological deficit.

Cause: Photon attenuation is the absorption or scattering of gamma rays by the patient's own tissues before they reach the detector. This can be particularly problematic in brain SPECT due to the varying densities of the skull and brain tissue.[\[7\]](#)[\[8\]](#)

Solution:

- Prevention:
 - Proper patient positioning to minimize the amount of attenuating material in the field of view.
- Detection:
 - Recognize patterns of attenuation that are common, such as apparent decreased uptake in deep brain structures.
- Correction:
 - Attenuation Correction Algorithms: The most effective way to address attenuation is to use an attenuation correction algorithm during image reconstruction. Common methods include:
 - Chang's Method: An analytical method that assumes a uniform attenuation coefficient.[\[8\]](#)
 - CT-based Attenuation Correction: Utilizes a CT scan acquired simultaneously with the SPECT data to create a detailed attenuation map of the patient's head.[\[9\]](#)[\[10\]](#) This method is generally more accurate than analytical methods.

Extracerebral Uptake Artifacts

Issue: High tracer uptake in organs outside the brain, such as the lungs and liver, causing artifacts in the adjacent brain regions.

Cause: **lofetamine** is known to have significant uptake in the lungs and is metabolized by the liver.^[11] High activity in these organs can lead to "spillover" of counts into the reconstructed brain images, potentially obscuring or mimicking pathology, particularly in the temporal lobes and cerebellum.

Solution:

- Prevention:
 - Adhere to recommended injection and uptake protocols to allow for sufficient clearance of the tracer from extracerebral tissues.
- Detection:
 - Carefully review the raw projection data and reconstructed images for evidence of high extracerebral activity.
- Correction:
 - Image Reconstruction: Utilize reconstruction algorithms that can model and correct for scatter and spillover from adjacent hot sources.
 - Region of Interest (ROI) Analysis: When performing quantitative analysis, carefully draw ROIs to exclude areas that may be contaminated by extracerebral activity.

Quantitative Data Summary

The following tables summarize key quantitative parameters related to **lofetamine** SPECT imaging quality control and the impact of common artifacts.

Table 1: **lofetamine** SPECT Quality Control Parameters

Parameter	Frequency	Acceptance Criteria
Uniformity	Daily	Integral uniformity < 4%, Differential uniformity < 3% [12]
Energy Resolution	Daily	Within $\pm 10\%$ of the value for 140 keV [12]
Spatial Resolution	Weekly	< 4mm [12]
Center of Rotation (COR)	Weekly	Offset < 0.5 pixels [12]
Pixel Size Calibration	Annually	Within $\pm 2\%$ of the nominal value
SPECT-CT Registration	Annually	Misregistration < 2 pixels

Table 2: Quantitative Impact of Motion Artifacts on SPECT Imaging

Motion Type	Degree of Motion	Resultant Perfusion Defect (if uncorrected)
Upward Creep	Uniform shift	Can create significant defects, extent varies with detector type [6]
Abrupt Shift (early in acquisition)	> 1 pixel	Can create the largest defects with a single-head detector [6]
Abrupt Shift (middle of acquisition)	> 1 pixel	Can create the largest defects with a dual-head detector [6]
Bounce (returning pattern)	-	Generally fails to produce significant perfusion defects [6]

Experimental Protocols

Detailed Protocol for Iofetamine SPECT Acquisition and Processing

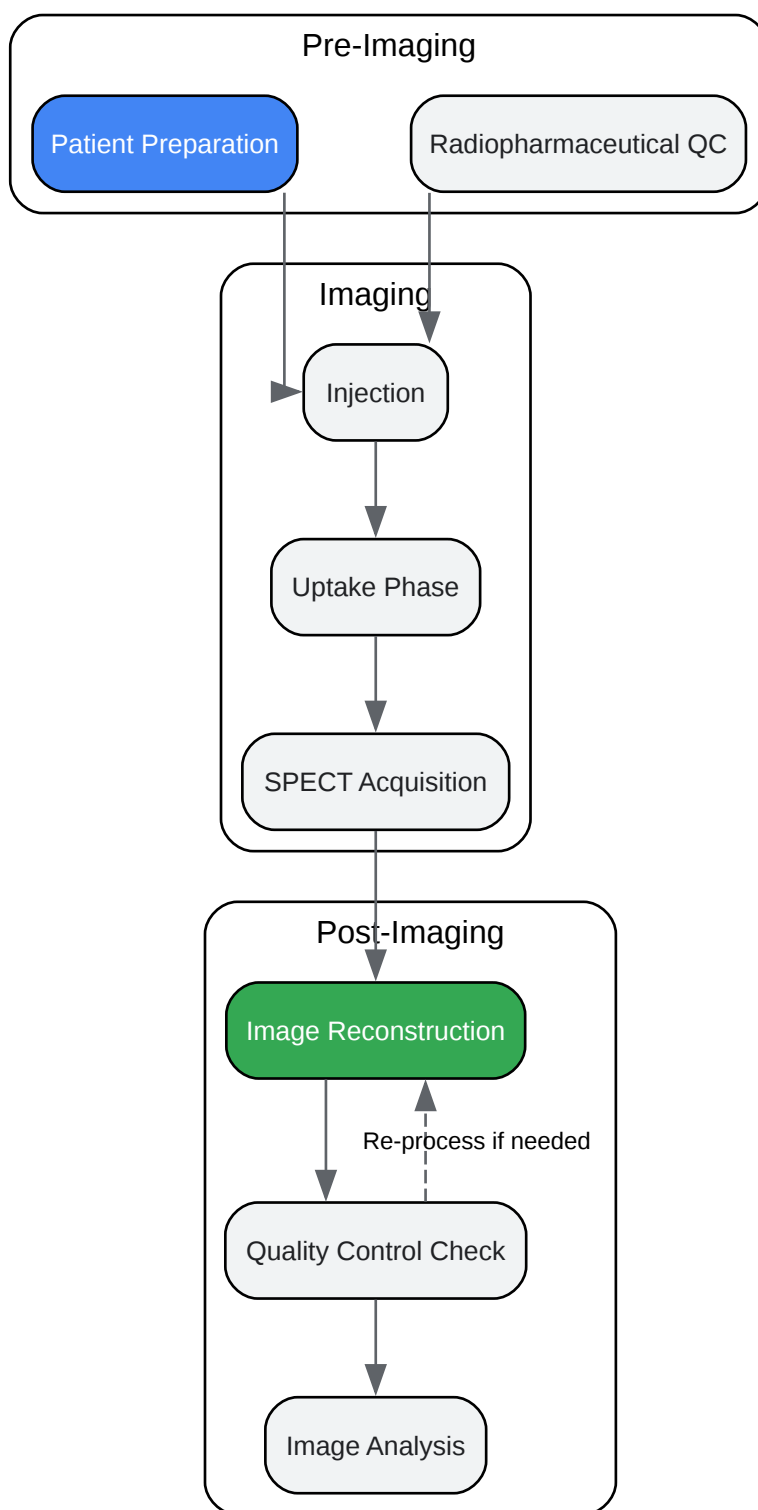
This protocol is a general guideline and should be adapted based on the specific equipment and institutional procedures.

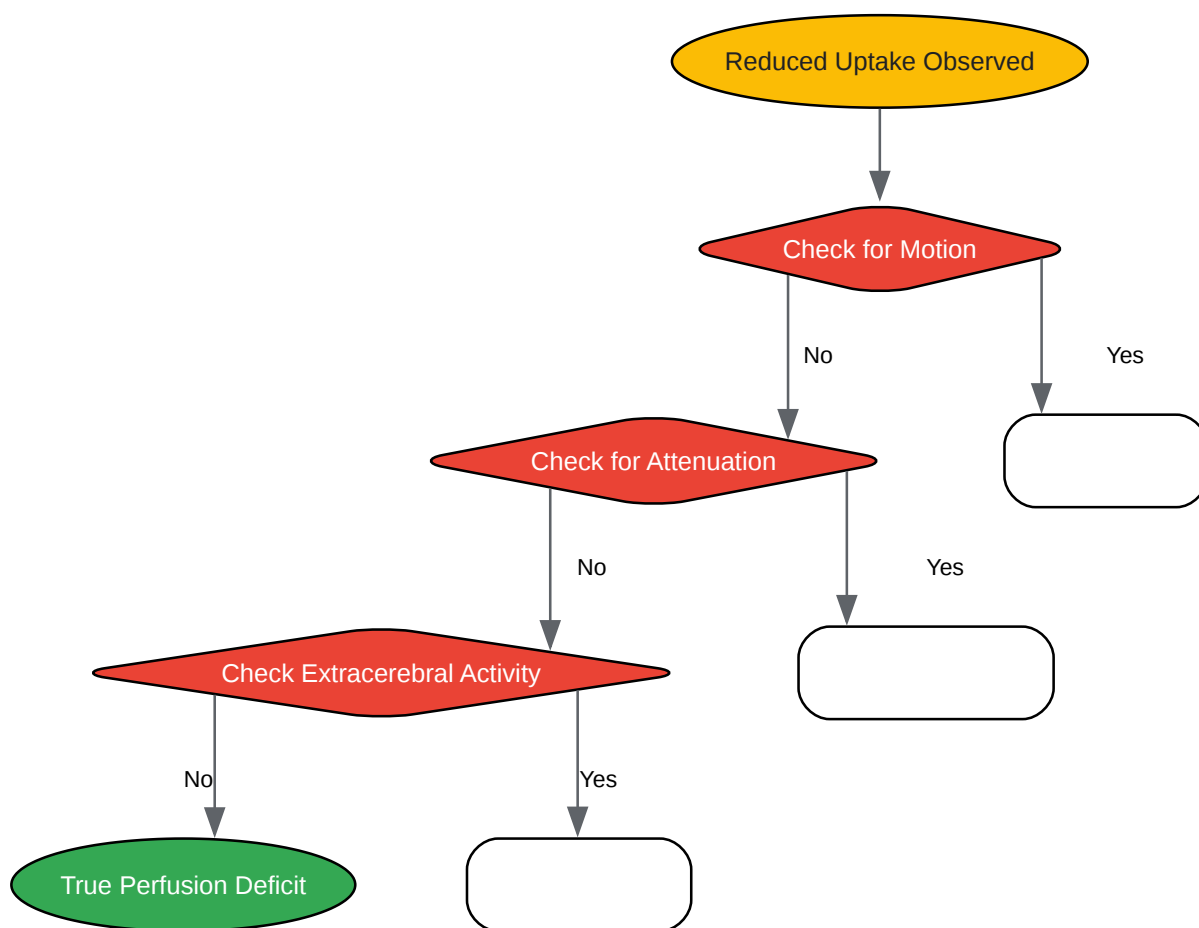
- Patient Preparation:
 - Instruct the patient to remain in a quiet, dimly lit room for 15-20 minutes prior to injection to minimize sensory input.
 - Ensure the patient is well-hydrated.[\[4\]](#)
 - Review the patient's current medications for any that may affect cerebral blood flow.
- Radiopharmaceutical Administration:
 - Administer the appropriate dose of **lofetamine** I-123 intravenously.
 - The injection should be performed in a quiet environment to avoid patient anxiety, which can alter cerebral perfusion.
- Image Acquisition:
 - Position the patient comfortably on the imaging table with their head in a head holder to minimize motion.
 - Acquisition should typically begin 20-30 minutes post-injection.[\[13\]](#)[\[14\]](#)
 - Acquisition Parameters:
 - Collimator: Low-energy, high-resolution (LEHR) collimator.
 - Energy Window: 159 keV with a 15-20% window.
 - Matrix Size: 128x128.
 - Projections: 120-128 projections over 360 degrees.
 - Acquisition Time: 20-30 seconds per projection.
- Image Reconstruction:

- Use an iterative reconstruction algorithm (e.g., Ordered Subsets Expectation Maximization - OSEM).[\[15\]](#)[\[16\]](#)
- Apply attenuation correction (preferably CT-based) and scatter correction.[\[9\]](#)[\[15\]](#)
- Apply a post-reconstruction filter (e.g., Butterworth or Gaussian) to reduce noise. The choice of filter and its parameters should be optimized for the specific system.[\[15\]](#)
- Image Analysis:
 - Reorient the reconstructed images into the standard anatomical planes (transverse, coronal, sagittal).
 - Perform visual and/or quantitative analysis of regional cerebral blood flow. For quantitative analysis, use a standardized brain atlas to define regions of interest.[\[17\]](#)

Visualizations

Iofetamine SPECT Imaging Workflow





[Click to download full resolution via product page](#)

Need Custom Synthesis?

BenchChem offers custom synthesis for rare earth carbides and specific isotopic labeling.

Email: info@benchchem.com or [Request Quote Online](#).

References

- 1. Iofetamine HCl I-123 (Iodoamphetamine) brain SPECT atlas - PubMed [pubmed.ncbi.nlm.nih.gov]
- 2. Recognizing and preventing artifacts with SPECT and PET imaging | Radiology Key [radiologykey.com]
- 3. How to detect and avoid myocardial perfusion SPECT artifacts - PubMed [pubmed.ncbi.nlm.nih.gov]

- 4. SPECT Scan Prep: Powerful Tips for a Successful Test - Liv Hospital [int.livhospital.com]
- 5. A quantitative assessment of patient motion and its effect on myocardial perfusion SPECT images - PubMed [pubmed.ncbi.nlm.nih.gov]
- 6. Quantitative assessment of motion artifacts and validation of a new motion-correction program for myocardial perfusion SPECT - PubMed [pubmed.ncbi.nlm.nih.gov]
- 7. lettersinhighenergyphysics.com [lettersinhighenergyphysics.com]
- 8. openmedscience.com [openmedscience.com]
- 9. CT-based attenuation correction in I-123-ioflupane SPECT - PubMed [pubmed.ncbi.nlm.nih.gov]
- 10. Understanding Attenuation Correction - Digirad [digirad.com]
- 11. SPECT and planar brain imaging in crack abuse: iodine-123-iodoamphetamine uptake and localization - PubMed [pubmed.ncbi.nlm.nih.gov]
- 12. inis.iaea.org [inis.iaea.org]
- 13. Early and delayed imaging with 123I-IMP SPECT in patients with ischemic cerebrovascular disease - PubMed [pubmed.ncbi.nlm.nih.gov]
- 14. nuclearord.fr [nuclearord.fr]
- 15. Impact of reconstruction parameters on spatial resolution and its comparison between cadmium-zinc-telluride SPECT/CT and conventional SPECT/CT - PubMed [pubmed.ncbi.nlm.nih.gov]
- 16. Investigation of a deep learning-based reconstruction approach utilizing dual-view projection for myocardial perfusion SPECT imaging - PMC [pmc.ncbi.nlm.nih.gov]
- 17. Alzheimer disease: quantitative analysis of I-123-iodoamphetamine SPECT brain imaging - PubMed [pubmed.ncbi.nlm.nih.gov]
- To cite this document: BenchChem. [Troubleshooting artifacts in Iofetamine SPECT imaging]. BenchChem, [2025]. [Online PDF]. Available at: [<https://www.benchchem.com/product/b3416847#troubleshooting-artifacts-in-iofetamine-spect-imaging>]

Disclaimer & Data Validity:

The information provided in this document is for Research Use Only (RUO) and is strictly not intended for diagnostic or therapeutic procedures. While BenchChem strives to provide

accurate protocols, we make no warranties, express or implied, regarding the fitness of this product for every specific experimental setup.

Technical Support: The protocols provided are for reference purposes. Unsure if this reagent suits your experiment? [[Contact our Ph.D. Support Team for a compatibility check](#)]

Need Industrial/Bulk Grade? [Request Custom Synthesis Quote](#)

BenchChem

Our mission is to be the trusted global source of essential and advanced chemicals, empowering scientists and researchers to drive progress in science and industry.

Contact

Address: 3281 E Guasti Rd
Ontario, CA 91761, United States
Phone: (601) 213-4426
Email: info@benchchem.com