

Technical Support Center: Ultrasound Imaging of Chondrocalcinosis

Author: BenchChem Technical Support Team. **Date:** December 2025

Compound of Interest

Compound Name: Calcium pyrophosphate

Cat. No.: B7822615

[Get Quote](#)

This technical support center provides troubleshooting guides and frequently asked questions (FAQs) to assist researchers, scientists, and drug development professionals in minimizing artifacts during ultrasound imaging of chondrocalcinosis.

Frequently Asked Questions (FAQs)

Q1: What are the characteristic ultrasound findings of chondrocalcinosis?

A1: Chondrocalcinosis, the deposition of **calcium pyrophosphate** (CPP) crystals in cartilage, presents with distinct features on ultrasound. The most common findings are hyperechoic (bright) dots or lines running parallel to the joint surface within the hyaline cartilage.[1] In fibrocartilage, such as the menisci of the knee or the triangular fibrocartilage complex (TFCC) of the wrist, CPP deposits appear as hyperechoic images.[1] According to the Outcome Measures in Rheumatology (OMERACT) working group, CPP deposits are defined as hyperechoic deposits with an echogenicity similar to the bone cortex, which typically do not create posterior acoustic shadowing.[2] These deposits can vary in size and shape and remain fixed within the tissue during dynamic scanning.[2]

Q2: Which joints are most important to scan when suspecting chondrocalcinosis?

A2: Studies have shown that a reduced scanning protocol that includes bilateral assessment of the knees, wrists, and hips provides excellent accuracy for the diagnosis of **calcium pyrophosphate** deposition (CPPD) disease.[3][4][5] The menisci of the knee are the most

frequently affected structures.[2] Therefore, a focused examination of these joints is often sufficient and improves the feasibility of the ultrasound examination.[3][4]

Q3: What are the most common artifacts encountered when imaging for chondrocalcinosis?

A3: The most common artifacts in musculoskeletal ultrasound for chondrocalcinosis are:

- **Anisotropy:** This artifact causes structures like tendons and ligaments to appear hypoechoic (darker) when the ultrasound beam is not perpendicular to them, potentially mimicking pathology.[6][7][8]
- **Acoustic Shadowing:** This appears as a dark area behind a highly reflective structure, such as a large calcification or bone, where the ultrasound beam is blocked.[9][10] While CPP crystals typically do not cause significant shadowing, larger deposits might.[2][11]
- **Reverberation:** This artifact presents as multiple, equally spaced hyperechoic lines, created when the ultrasound beam bounces between two strong parallel reflectors.[12]

Q4: Can ultrasound distinguish between different types of crystal deposits?

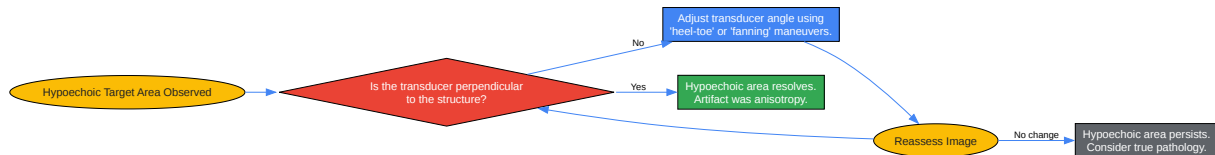
A4: The appearance and location of crystal deposits can help distinguish between different crystal arthropathies.[1] For instance, monosodium urate (MSU) crystals in gout often deposit on the surface of hyaline cartilage, creating a "double contour sign," while CPP crystals are typically found within the cartilage itself.[13] Furthermore, CPP deposits generally do not cause posterior acoustic shadowing, which can be a distinguishing feature from other types of calcifications.[2]

Troubleshooting Guides

Issue 1: Hypoechoic or "Blacked-out" Target Area (Suspected Anisotropy)

Problem: The target tissue (e.g., tendon, ligament, or even the bone surface) appears abnormally dark, potentially obscuring CPP deposits or being misinterpreted as a lesion.[6][14]

Solution Workflow:



[Click to download full resolution via product page](#)

Caption: Troubleshooting workflow for anisotropy artifact.

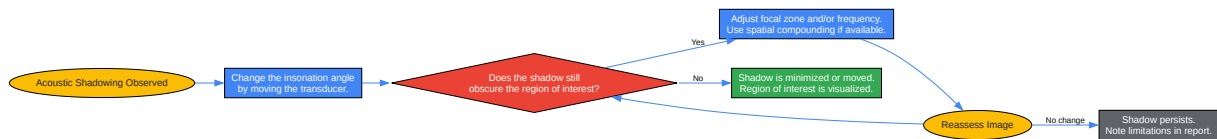
Detailed Steps:

- Recognize the Possibility of Anisotropy: Be aware that tendons, ligaments, and even the bone surface can appear hypoechoic if the ultrasound beam is not striking them at a 90-degree angle.[6][14]
- Perform Corrective Maneuvers:
 - Heel-Toe Maneuver: For long-axis views, gently rock the transducer along its length to alter the angle of insonation.[8][15]
 - Fanning/Toggling: Sweep the transducer from side to side without changing its footprint to find the angle of maximal echogenicity.[7][8]
- Confirm the Diagnosis: If the hypoechoic appearance resolves with these adjustments, the artifact was due to anisotropy.[6] If the area remains dark, it is more likely to represent a true pathological finding.

Issue 2: Posterior Acoustic Shadowing Obscuring Deeper Structures

Problem: A dark shadow behind a structure (like a large calcification or bone) prevents visualization of the tissues underneath.

Solution Workflow:



[Click to download full resolution via product page](#)

Caption: Troubleshooting workflow for acoustic shadowing.

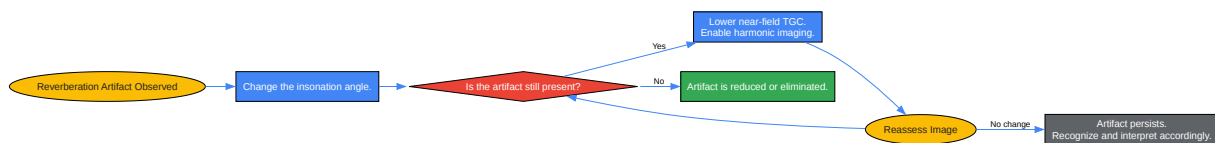
Detailed Steps:

- Alter the Angle of Insonation: Scan the area from different angles to try and "look around" the shadowing structure.[9]
- Adjust Machine Settings:
 - Focal Zone: Adjust the focal zone to be deeper than the structure causing the shadow, which can sometimes reduce the shadow's intensity.[10]
 - Frequency: Lowering the transducer frequency may improve penetration, but at the cost of resolution.
 - Spatial Compounding: If available, this feature uses multiple lines of sight to create an image, which can reduce shadowing.
- Use a Standoff Pad: For very superficial structures causing shadowing, a standoff pad can improve visualization.

Issue 3: Spurious Lines Appearing in the Image (Reverberation Artifact)

Problem: Multiple, equally spaced bright lines appear deep to a strong reflector, which can mimic tissue layers or obscure underlying anatomy.

Solution Workflow:



[Click to download full resolution via product page](#)

Caption: Troubleshooting workflow for reverberation artifact.

Detailed Steps:

- Change the Angle of Insonation: Slightly altering the transducer angle can disrupt the parallel reflection causing the reverberation.[12]
- Optimize Machine Settings:
 - Time Gain Compensation (TGC): Reduce the gain in the near-field to decrease the intensity of the initial strong reflection.[9]
 - Harmonic Imaging: This mode can help reduce reverberation artifacts.[9]
- Identify and Ignore: In some cases, the artifact cannot be completely eliminated. It is important to recognize it as an artifact and not misinterpret it as an anatomical structure.

Data Presentation

Table 1: Recommended Starting Ultrasound Parameters for Chondrocalcinosis Imaging

Parameter	Knee	Wrist	Hip
Transducer Type	Linear	Linear	Curvilinear or Linear
Frequency	High (e.g., >10 MHz)	High (e.g., >12 MHz)	Lower (e.g., 5-9 MHz) for deeper structures, High for superficial
Depth	2-4 cm (adjust to visualize cartilage and menisci)	1-3 cm (adjust to visualize TFCC and carpal bones)	4-8 cm (adjust to visualize femoral head and labrum)
Focal Zone(s)	Set at the level of the hyaline cartilage or meniscus	Set at the level of the TFCC	Set at the level of the femoral head-neck junction
Gain	Adjust for optimal brightness, avoiding over-saturation of hyperechoic structures	Adjust for optimal brightness, comparing CPP echogenicity to bone cortex	Adjust for optimal brightness and adequate penetration
Dynamic Range	Adjust to optimize contrast between CPP deposits and surrounding tissue	Adjust to optimize contrast between CPP deposits and surrounding tissue	Adjust to balance contrast and penetration

Note: These are starting parameters and should be optimized for each patient and machine.

Experimental Protocols

Protocol 1: Standardized Ultrasound Examination of the Knee for Chondrocalcinosis

This protocol is based on EULAR and OMERACT recommendations.[\[2\]](#)[\[16\]](#)[\[17\]](#)

1. Patient Positioning:

- The patient should be in a supine position with the knee flexed to the maximum possible degree to expose the femoral trochlear cartilage.[\[18\]](#)

2. Transducer and Machine Settings:

- Use a high-frequency linear transducer (>10 MHz).
- Set the focal zone at the level of the hyaline cartilage.
- Optimize gain and dynamic range as described in Table 1.

3. Scanning Procedure:

- Anterior Longitudinal (Suprapatellar) View:
 - Place the transducer in a longitudinal plane superior to the patella.
 - Visualize the quadriceps tendon, suprapatellar fat pad, and the hyaline cartilage of the femoral trochlea.
 - Scan medially and laterally to assess the entire trochlear cartilage for hyperechoic deposits.
- Anterior Transverse View:
 - Rotate the transducer 90 degrees to obtain a transverse view.
 - Sweep from proximal to distal over the femoral trochlea.
- Medial and Lateral Menisci:
 - Return to a longitudinal view and place the transducer over the medial and lateral joint lines.
 - Identify the triangular-shaped meniscus.

- Carefully scan the entire meniscus from anterior to posterior for punctate or linear hyperechoic deposits.[2] Use slight tilting of the probe to improve visualization between the bones.[2]

Protocol 2: Standardized Ultrasound Examination of the Wrist for Chondrocalcinosis

1. Patient Positioning:

- The patient should be seated facing the examiner with their hand in a palm-down position, resting on a flat surface.[19]

2. Transducer and Machine Settings:

- Use a high-frequency linear transducer (>12 MHz).
- Set the focal zone at the level of the triangular fibrocartilage complex (TFCC).
- Optimize gain and dynamic range.

3. Scanning Procedure:

- Dorsal View (for TFCC):
 - Place the transducer in a transverse plane over the dorsal aspect of the wrist, between the ulna and the triquetrum.
 - Identify the triangular, hyperechoic TFCC.
 - Scan in both transverse and longitudinal planes to detect any hyperechoic spots within the TFCC.
- Palmar View:
 - Ask the patient to turn their palm up.
 - Examine the radiocarpal and midcarpal joints for any other evidence of CPP deposition.

Need Custom Synthesis?

BenchChem offers custom synthesis for rare earth carbides and specific isotopic labeling.

Email: info@benchchem.com or [Request Quote Online](#).

References

- 1. Ultrasonography in chondrocalcinosis - PubMed [pubmed.ncbi.nlm.nih.gov]
- 2. mdpi.com [mdpi.com]
- 3. academic.oup.com [academic.oup.com]
- 4. Diagnosis of calcium pyrophosphate crystal deposition disease by ultrasonography: how many and which sites should be scanned? - PubMed [pubmed.ncbi.nlm.nih.gov]
- 5. Ultrasound Diagnosis of Calcium Pyrophosphate Crystal Deposition: Which Sites Should Be Scanned? - ACR Meeting Abstracts [acrabstracts.org]
- 6. pocus.org [pocus.org]
- 7. Musculoskeletal Ultrasound: Understanding Common Artifacts - Gulfcoast Ultrasound News Blog [gcus.com]
- 8. asianpainacademy.com [asianpainacademy.com]
- 9. iame.com [iame.com]
- 10. radiopaedia.org [radiopaedia.org]
- 11. A “new” technique for the diagnosis of chondrocalcinosis of the knee: sensitivity and specificity of high-frequency ultrasonography - PMC [pmc.ncbi.nlm.nih.gov]
- 12. radiopaedia.org [radiopaedia.org]
- 13. Usefulness of ultrasound in the diagnosis of crystal deposition diseases - PubMed [pubmed.ncbi.nlm.nih.gov]
- 14. Diagnostic errors in musculoskeletal ultrasound imaging and how to avoid them - PMC [pmc.ncbi.nlm.nih.gov]
- 15. m.youtube.com [m.youtube.com]
- 16. eprints.whiterose.ac.uk [eprints.whiterose.ac.uk]
- 17. ard.bmj.com [ard.bmj.com]

- 18. Ultrasound in the Diagnosis of Crystal Deposition Disease | Musculoskeletal Key [musculoskeletalkey.com]
- 19. essr.org [essr.org]
- To cite this document: BenchChem. [Technical Support Center: Ultrasound Imaging of Chondrocalcinosis]. BenchChem, [2025]. [Online PDF]. Available at: [https://www.benchchem.com/product/b7822615#minimizing-artifacts-in-ultrasound-imaging-of-chondrocalcinosis]

Disclaimer & Data Validity:

The information provided in this document is for Research Use Only (RUO) and is strictly not intended for diagnostic or therapeutic procedures. While BenchChem strives to provide accurate protocols, we make no warranties, express or implied, regarding the fitness of this product for every specific experimental setup.

Technical Support: The protocols provided are for reference purposes. Unsure if this reagent suits your experiment? [[Contact our Ph.D. Support Team for a compatibility check](#)]

Need Industrial/Bulk Grade? [Request Custom Synthesis Quote](#)

BenchChem

Our mission is to be the trusted global source of essential and advanced chemicals, empowering scientists and researchers to drive progress in science and industry.

Contact

Address: 3281 E Guasti Rd

Ontario, CA 91761, United States

Phone: (601) 213-4426

Email: info@benchchem.com