

Technical Support Center: Troubleshooting Lymphoscan Axillary Node Uptake

Author: BenchChem Technical Support Team. **Date:** December 2025

Compound of Interest

Compound Name: *Lymphoscan*

Cat. No.: *B224265*

[Get Quote](#)

This technical support guide is designed for researchers, scientists, and drug development professionals to address common issues encountered during **Lymphoscan** experiments, specifically focusing on poor or no uptake in the axillary lymph nodes.

Frequently Asked Questions (FAQs)

Q1: What is **Lymphoscan** and how does it work for axillary node imaging?

Lymphoscintigraphy, often referred to by the proprietary name **Lymphoscan**, is a nuclear medicine imaging technique used to map the lymphatic system.^[1] It involves the injection of a radiotracer, typically Technetium-99m sulfur colloid, which is taken up by the lymphatic vessels and transported to the draining lymph nodes.^[1] A gamma camera detects the radiation emitted by the tracer, creating images that visualize the lymphatic pathways and sentinel lymph nodes (SLNs), the first nodes to receive lymphatic drainage from a specific area.^{[1][2]} In the context of axillary node imaging, this technique is crucial for staging cancers like breast cancer and melanoma.^{[3][4]}

Q2: What are the common causes of poor or no **Lymphoscan** uptake in the axillary nodes?

Failure to visualize the sentinel lymph node can be attributed to several factors, which can be broadly categorized as patient-related, tumor-related, or technical.^{[5][6][7]}

- Patient-Related Factors: Older age (≥ 70 years) and a high body mass index (BMI ≥ 30 kg/m²) are significantly associated with nonvisualization of the SLN.^{[5][8]} Larger breast size can

also increase the transit time of the radiotracer.[9]

- **Tumor-Related Factors:** Extensive tumor infiltration in the lymph nodes can obstruct lymphatic flow, preventing the radiotracer from reaching the nodes.[3][6][10][11] Larger tumor size and higher tumor grade have also been associated with nonvisualization.[10]
- **Technical and Procedural Factors:** The injection technique, including the site and depth of injection, is critical.[3][6] Previous surgery or radiation to the breast or axilla can alter lymphatic drainage pathways.[7][12] The absence of massaging the injection site may also contribute to poor uptake.[1][7]

Q3: Can a failed **Lymphoscan** predict the status of the axillary lymph nodes?

No, the failure to visualize a sentinel node on a preoperative lymphoscintigram does not necessarily predict a higher likelihood of axillary lymph node metastases.[5] Studies have shown that the rate of positive SLNs is similar in patients with and without preoperative visualization.[5] In many cases of nonvisualization on the scan, the SLN can still be successfully identified intraoperatively using a combination of a gamma probe and blue dye.[4][13]

Q4: What immediate steps can be taken during the procedure if there is no uptake?

If initial imaging shows no uptake, several measures can be taken:

- **Continue Imaging:** Sequential or continuous imaging for a longer duration (e.g., 30-60 minutes or even several hours) may be necessary as transit times can vary.[1][7][9]
- **Massage the Injection Site:** Gently massaging the area of injection can help improve the distribution and uptake of the radiotracer.[1][7]
- **Re-injection:** In some cases, a second injection of the radiotracer may be performed, which can significantly improve the visualization rate.[8]
- **Alternative Views:** Obtaining additional imaging views, such as a modified oblique view of the axilla (MOVA), can improve the identification of axillary sentinel nodes.[9]

Troubleshooting Guide

This guide provides a systematic approach to troubleshooting poor or no **Lymphoscan** uptake.

Problem: No radiotracer uptake detected in the axillary region during initial imaging.

Possible Causes & Solutions

Possible Cause	Troubleshooting Steps	Rationale
Patient-Related Factors		
High BMI / Large Breast Size	<ul style="list-style-type: none">- Increase the time between injection and imaging.[9]- Consider a higher activity dose of the radiotracer within approved limits.[12]- Utilize advanced imaging techniques like SPECT/CT for better localization.[6]	Adipose tissue can attenuate the gamma signal, and larger breast size is associated with increased radiotracer transit time. [5] [9]
Older Age	<ul style="list-style-type: none">- Be aware of potentially slower lymphatic flow and allow for longer imaging times.	The drainage function of lymphatic vessels can decline with age. [14]
Tumor-Related Factors		
Extensive Nodal Metastasis	<ul style="list-style-type: none">- Carefully palpate the axilla for any suspicious nodes.[3]- If a palpable node is present, it should be considered for removal and evaluation, as a node replaced by a tumor is unlikely to absorb the tracer.[3]	A high tumor burden can physically block the lymphatic channels, preventing the tracer from reaching the sentinel node. [6] [10] [11]
Technical/Procedural Issues		
Suboptimal Injection Technique	<ul style="list-style-type: none">- Ensure the injection is intradermal or subdermal, not directly into the tumor or a seroma cavity.[1][3]- A combination of deep and superficial injections may be beneficial.[1]- For breast imaging, subareolar or periareolar injections have shown high success rates.[15]	The injection technique significantly influences the migration of the radiotracer to the lymphatic system.

Insufficient Radiotracer Migration	- Gently massage the injection site for 2-5 minutes following injection.[1][7][15]	Massage can enhance the movement of the radiotracer from the injection site into the lymphatic vessels.[1]
Altered Lymphatic Drainage	- Review the patient's history for prior surgeries or radiation to the breast or axilla.[7][12] - Be prepared for unexpected drainage patterns, including to internal mammary or supraclavicular nodes.[4][9]	Previous interventions can scar and reroute lymphatic pathways.[12]
Imaging Acquisition Parameters	- Use a modified oblique view of the axilla (MOVA) in addition to standard anterior views.[9] - Attenuate intense activity at the injection site with lead shielding to better visualize faint nodal uptake.[1]	Optimized imaging angles and techniques can significantly improve the detection of sentinel nodes.[9]

Experimental Protocols

Standard Lymphoscintigraphy Protocol for Axillary Node Mapping

This protocol is a generalized summary based on common practices.[1][16] Institutions may have variations.

- Patient Preparation:
 - Explain the procedure to the patient and obtain informed consent.[16][17]
 - Remove any jewelry or metallic objects that could interfere with imaging.[1]
 - Position the patient appropriately (e.g., supine with the arm abducted for breast lymphoscintigraphy).[1]

- Radiopharmaceutical Preparation and Injection:
 - The typical radiotracer is Technetium-99m (99mTc) sulfur colloid.[\[1\]](#)
 - The activity generally ranges from 0.1 to 10 mCi, adjusted based on the timing of the surgery.[\[1\]](#)
 - The injection is typically administered intradermally or subcutaneously around the lesion or in the periareolar region for breast cancer.[\[1\]](#)[\[16\]](#) Use a fine-gauge needle for the injection.[\[1\]](#)
 - For melanoma, injections are made intradermally around the tumor or excision site.[\[16\]](#)
 - The injection site should be cleansed prior to administration.[\[18\]](#)
- Imaging:
 - Begin sequential or continuous imaging immediately after injection for 30 to 60 minutes.[\[1\]](#)
 - The field of view should include the injection site and the expected lymphatic drainage basin.
 - Acquire anterior and modified oblique views of the axilla (MOVA).[\[9\]](#)
 - Transmission images using a Cobalt-57 source can be used to outline the body.[\[1\]](#)
- Post-Imaging:
 - The identified sentinel lymph node(s) are marked on the patient's skin to guide the surgeon.

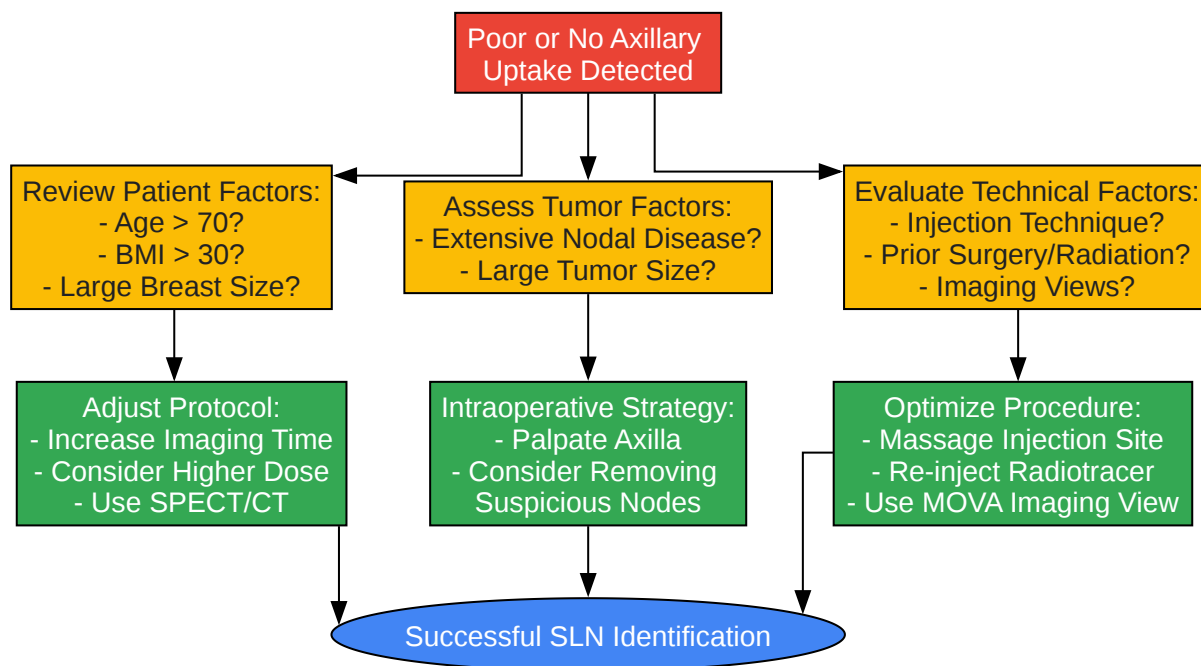
Data Presentation

Table 1: Factors Associated with Nonvisualization of Axillary Sentinel Lymph Nodes

Factor	Finding	Reference
Patient Age	A significantly higher percentage of women older than 50, and especially ≥ 70 years, had nonvisualization of the SLN.	[5]
Body Mass Index (BMI)	A BMI $> 30 \text{ kg/m}^2$ was more prevalent in the group with nonvisualized SLNs.	[5][8]
Tumor Size	Larger primary tumor size was associated with a higher rate of SLN nonvisualization.	[10]
Number of Positive Nodes	An increased number of metastatic axillary lymph nodes is associated with nonvisualization.	[6][10][11]
Previous Surgery/Radiation	Prior surgical procedures on the breast or axilla are a risk factor for failed lymphoscintigraphy.	[12]

Visualizations

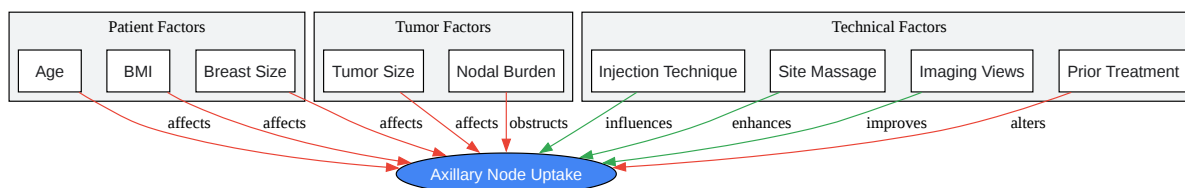
Troubleshooting Workflow for Poor Axillary Node Uptake



[Click to download full resolution via product page](#)

Caption: A flowchart for troubleshooting poor or no **Lymphoscan** uptake.

Logical Relationship of Factors Affecting Lymphoscan Uptake



[Click to download full resolution via product page](#)

Caption: Factors influencing axillary lymph node uptake of **Lymphoscan**.

Need Custom Synthesis?

BenchChem offers custom synthesis for rare earth carbides and specific isotopic labeling.

Email: info@benchchem.com or [Request Quote Online](#).

References

- 1. Lymphoscintigraphy - StatPearls - NCBI Bookshelf [ncbi.nlm.nih.gov]
- 2. my.clevelandclinic.org [my.clevelandclinic.org]
- 3. Troubleshooting Sentinel Lymph Node Biopsy in Breast Cancer Surgery - PMC [pmc.ncbi.nlm.nih.gov]
- 4. Fallacies of preoperative lymphoscintigraphy in detecting sentinel node in breast cancer - PMC [pmc.ncbi.nlm.nih.gov]
- 5. Does failure to visualize a sentinel node on preoperative lymphoscintigraphy predict a greater likelihood of axillary lymph node positivity? - PubMed [pubmed.ncbi.nlm.nih.gov]
- 6. Nonvisualization of sentinel node by lymphoscintigraphy in advanced breast cancer - PMC [pmc.ncbi.nlm.nih.gov]
- 7. researchgate.net [researchgate.net]
- 8. Risk factors for nonvisualization of the sentinel lymph node on lymphoscintigraphy in breast cancer patients - PMC [pmc.ncbi.nlm.nih.gov]
- 9. Factors affecting sentinel node localization during preoperative breast lymphoscintigraphy - PubMed [pubmed.ncbi.nlm.nih.gov]
- 10. Non-visualization of axillary pathological lymph nodes in breast cancer patients on SPECT/CT and during operation - PMC [pmc.ncbi.nlm.nih.gov]
- 11. jnm.snmjournals.org [jnm.snmjournals.org]
- 12. Joint practice guidelines for radionuclide lymphoscintigraphy for sentinel node localization in oral/oropharyngeal squamous cell carcinoma - PMC [pmc.ncbi.nlm.nih.gov]
- 13. Preoperative Lymphoscintigraphy for Breast Cancer Does Not Improve the Ability to Identify Axillary Sentinel Lymph Nodes - PMC [pmc.ncbi.nlm.nih.gov]

- 14. The failure of a sentinel node biopsy due to an absence of nodal uptake of nuclear isotope in consecutive melanomas in a single patient – a physiological aberration - PMC [pmc.ncbi.nlm.nih.gov]
- 15. scispace.com [scispace.com]
- 16. radiology.wisc.edu [radiology.wisc.edu]
- 17. Procedural Recommendations for Lymphoscintigraphy in the Diagnosis of Peripheral Lymphedema: the Genoa Protocol - PMC [pmc.ncbi.nlm.nih.gov]
- 18. Best practices for injection - WHO Best Practices for Injections and Related Procedures Toolkit - NCBI Bookshelf [ncbi.nlm.nih.gov]
- To cite this document: BenchChem. [Technical Support Center: Troubleshooting Lymphoscan Axillary Node Uptake]. BenchChem, [2025]. [Online PDF]. Available at: [https://www.benchchem.com/product/b224265#troubleshooting-poor-or-no-lymphoscan-uptake-in-axillary-nodes]

Disclaimer & Data Validity:

The information provided in this document is for Research Use Only (RUO) and is strictly not intended for diagnostic or therapeutic procedures. While BenchChem strives to provide accurate protocols, we make no warranties, express or implied, regarding the fitness of this product for every specific experimental setup.

Technical Support: The protocols provided are for reference purposes. Unsure if this reagent suits your experiment? [[Contact our Ph.D. Support Team for a compatibility check](#)]

Need Industrial/Bulk Grade? [Request Custom Synthesis Quote](#)

BenchChem

Our mission is to be the trusted global source of essential and advanced chemicals, empowering scientists and researchers to drive progress in science and industry.

Contact

Address: 3281 E Guasti Rd
Ontario, CA 91761, United States
Phone: (601) 213-4426
Email: info@benchchem.com