

Technical Support Center: Troubleshooting Common Artifacts in FDG-PET/CT Imaging

Author: BenchChem Technical Support Team. **Date:** December 2025

Compound of Interest

Compound Name: FD-1080

Cat. No.: B15553411

[Get Quote](#)

This technical support center provides troubleshooting guides and frequently asked questions (FAQs) to help researchers, scientists, and drug development professionals identify and resolve common artifacts encountered during 18F-Fluorodeoxyglucose (FDG) Positron Emission Tomography/Computed Tomography (PET/CT) imaging experiments.

Frequently Asked Questions (FAQs)

Q1: What are the most common categories of artifacts in FDG-PET/CT imaging?

A1: Artifacts in FDG-PET/CT imaging can be broadly categorized into three main groups: patient-related, radiotracer-related, and instrument-related artifacts.^{[1][2]} Patient-related artifacts include those caused by motion (respiratory and voluntary), metallic implants, and patient size. Radiotracer-related artifacts often stem from issues with the injection process, such as extravasation. Instrument-related artifacts can be due to the technical limitations of the scanner, like truncation artifacts where the CT field of view (FOV) is smaller than the PET FOV.^{[2][3]}

Q2: How does patient motion affect the quality of FDG-PET/CT images?

A2: Patient motion during a scan can lead to several problems, including blurring of the images, which reduces the accuracy of tracer uptake measurements, known as Standardized Uptake Values (SUVs).^[4] Motion can also cause a mismatch between the PET and CT data, leading to inaccurate attenuation correction and potentially misplacing anatomical structures.^[5]

[6] Respiratory motion is a common issue, particularly affecting the thorax and upper abdomen.

[4][7]

Q3: What is a metal artifact and how does it impact the PET image?

A3: Metal artifacts are caused by high-density materials like dental fillings, prosthetic implants, or chemotherapy ports. These materials can cause severe streaking and photon starvation on the CT scan.[4][8] When this erroneous CT data is used for PET attenuation correction, it can lead to significant over- and under-estimation of tracer activity in the tissues surrounding the implant, which does not reflect the true biological distribution of FDG.[4][9]

Q4: What is radiotracer extravasation and how can it be identified?

A4: Radiotracer extravasation occurs when the FDG dose is accidentally injected into the soft tissue instead of the vein. This can be identified by a very high, localized FDG uptake at the injection site on the PET scan, which does not correspond to any anatomical structure on the CT.[2] This can affect the quantification of tracer uptake in other parts of the body.[2]

Troubleshooting Guides

Issue 1: Motion Artifacts

Q: My PET/CT images of the thoracic region appear blurry and the SUV values seem lower than expected. What could be the cause and how can I fix it?

A: This is likely due to respiratory motion. The movement of the diaphragm during breathing causes a mismatch between the PET and CT scans, leading to blurring and inaccurate quantification.[5][7]

Solutions:

- **Respiratory Gating:** This is the most effective technique to compensate for breathing motion. The scanner monitors the patient's breathing cycle and acquires data in different "bins" corresponding to different phases of respiration. These gated images can then be reconstructed to reduce motion blurring.[4]
- **Patient Instructions:** Instruct the patient to breathe shallowly and consistently during the scan.[2]

- Image Registration: Post-acquisition software can be used to co-register the PET and CT images to correct for motion.[\[4\]](#)

Issue 2: Metal-Induced Artifacts

Q: I am observing areas of artificially high and low FDG uptake around a patient's hip prosthesis. How can I correct for this?

A: These are characteristic metal artifacts. The high density of the prosthesis corrupts the CT data used for attenuation correction, leading to inaccurate PET values.[\[4\]](#)[\[9\]](#)

Solutions:

- Metal Artifact Reduction (MAR) Algorithms: Most modern PET/CT scanners have software algorithms designed to correct for metal artifacts in the CT images before they are used for PET attenuation correction.[\[4\]](#)[\[10\]](#)
- Review Non-Attenuation-Corrected (NAC) Images: Always review the NAC PET images. While not quantitatively accurate, they are not affected by CT-based artifacts and can help determine if an area of high uptake is a true biological finding or an artifact.[\[4\]](#)
- Modify CT Acquisition Parameters: In some cases, adjusting CT parameters (e.g., using a higher kVp) can help reduce the severity of metal artifacts.[\[4\]](#)

Issue 3: Truncation Artifacts

Q: The edges of my PET images, especially in larger patients or when the arms are down, show areas of artificially high uptake. What is causing this?

A: This is likely a truncation artifact. It occurs when parts of the body are outside the CT field of view but still within the PET field of view.[\[2\]](#)[\[3\]](#) The lack of CT data for these areas leads to incorrect attenuation correction and artificially high SUV values at the edges of the image.[\[8\]](#)

Solutions:

- Patient Positioning: Whenever possible, position the patient so that their entire body is within the CT FOV. For body scans, this often means imaging with the patient's arms raised above their head.[\[3\]](#)[\[10\]](#)

- Use Extended FOV Reconstruction: Some scanners offer reconstruction algorithms that can help correct for truncation artifacts.[\[10\]](#)
- Utilize Newer Scanners: Modern PET/CT scanners often have a larger CT FOV, which helps to minimize truncation artifacts.[\[3\]](#)

Quantitative Data Summary

The following tables summarize the quantitative impact of artifact correction techniques on Standardized Uptake Values (SUVs).

Table 1: Impact of Metal Artifact Reduction (MAR) on SUVmean

Artifact Type	Reconstruction Method	Mean SUVmean	Percentage Change from WFBP
Bright Band Artifact	WFBP (Standard)	0.99 ± 0.40	-
MARIS		0.96 ± 0.39	-3.0%
iMAR		0.88 ± 0.35	-11.1% [10]
Dark Band Artifact	WFBP (Standard)	0.75 ± 0.10	-
iMAR		1.00 ± 0.01	+33.3% [10]

WFBP: Weighted Filtered Back Projection, MARIS: Metal Artifact Reduction in Image Space, iMAR: iterative Metal Artifact Reduction.

Table 2: Impact of Respiratory Gating on SUVmax

Study	Number of Lesions/Patients	Mean Increase in SUVmax with Gating
Werner et al.	18 patients	22.4% [11]
Garcia Vicente et al.	42 lesions in 28 patients	83.3% [11]
Nehmeh et al.	4 patients	Up to 16% [11]
Suenaga et al.	Not specified	22% [12]
This study's compilation	89 lesions	19.81% [12]

Experimental Protocols

Protocol 1: Respiratory Gating for Motion Artifact Reduction

This protocol aims to minimize motion artifacts from respiration.

- Patient Preparation: Follow the standard protocol for FDG administration and uptake period.
- Positioning: Position the patient on the scanner bed. Place the respiratory tracking system (e.g., a pressure-sensitive belt or an infrared camera with a marker block) on the abdomen. [\[4\]](#)[\[13\]](#)
- Acquire CT Scan: Perform a low-dose helical CT scan for attenuation correction and anatomical localization. This can be a 4D CT where images are acquired at different phases of the breathing cycle.[\[13\]](#)
- Acquire 4D PET Scan:
 - Start the PET acquisition in list mode, which records each event with its timing and location information.
 - Simultaneously, the respiratory tracking system records the breathing waveform and sends trigger signals to the PET scanner.[\[4\]](#)

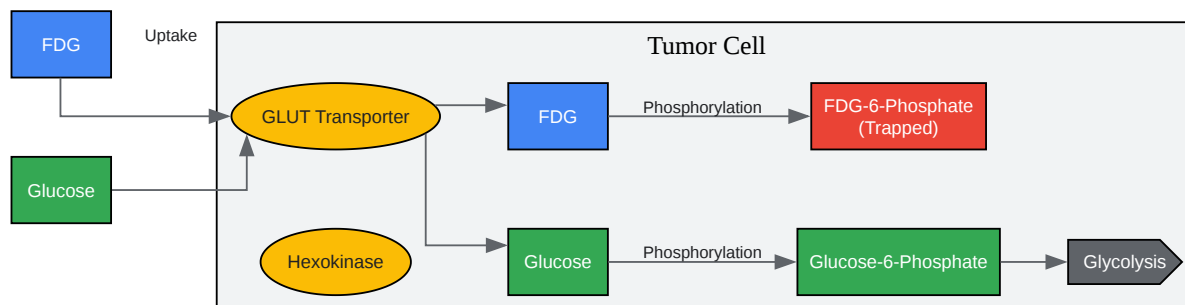
- **Data Binning:** The list-mode data is retrospectively sorted into a number of bins (typically 4-10) based on the phase of the respiratory cycle.[\[4\]](#)
- **Image Reconstruction:** Reconstruct the PET data from each bin separately. A motion-averaged image can also be created by combining the data from all bins. The CT data is matched to the corresponding respiratory phase for accurate attenuation correction of each gated PET image.[\[4\]](#)[\[13\]](#)

Protocol 2: Metal Artifact Reduction (MAR)

This protocol describes the general workflow for applying MAR algorithms.

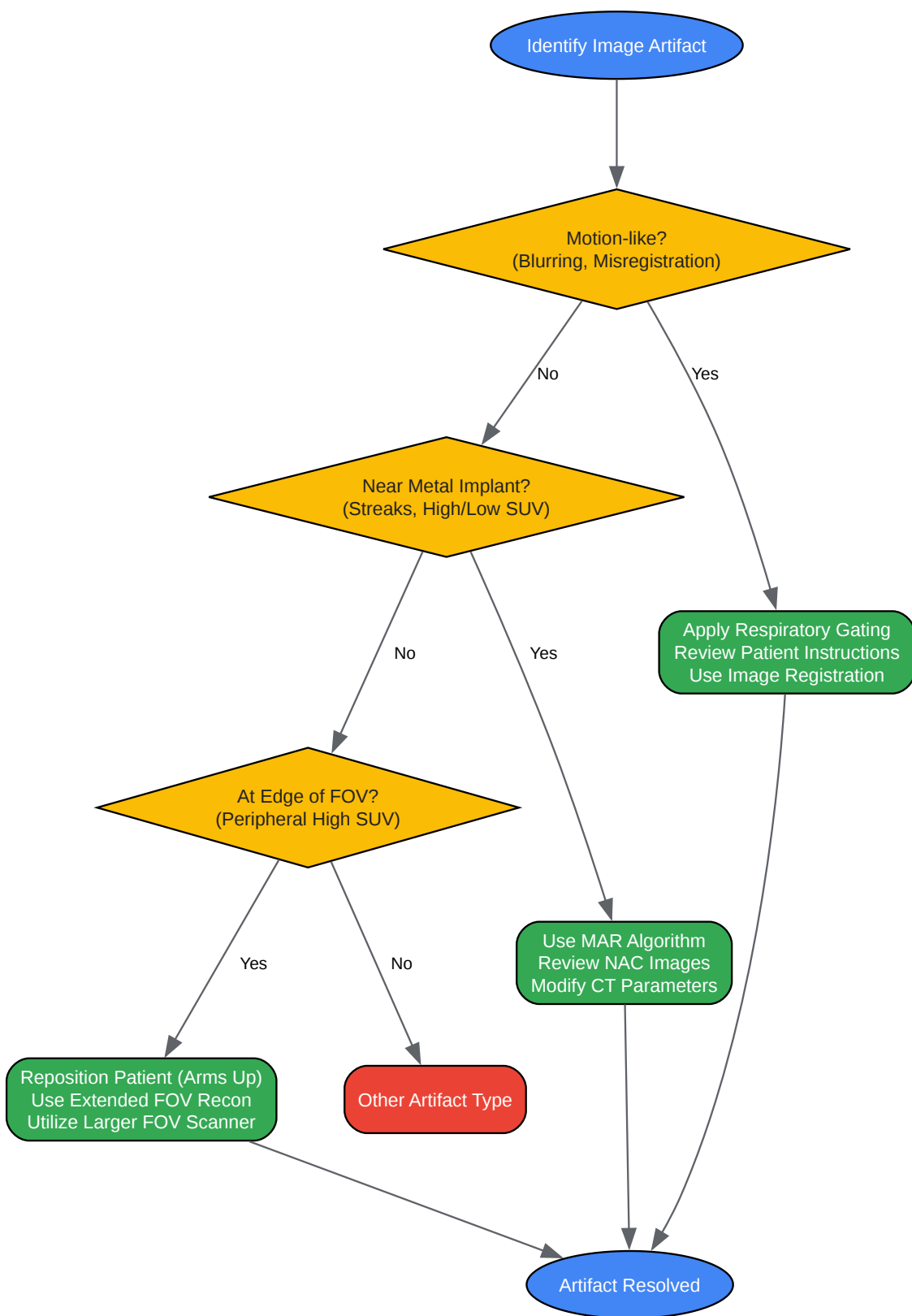
- **Acquire PET/CT Data:** Perform the PET/CT scan as per the standard protocol.
- **Initial CT Reconstruction:** The CT data is initially reconstructed.
- **Apply MAR Algorithm:**
 - The MAR software is applied to the raw CT data or the reconstructed CT images.
 - The algorithm identifies the location of the metallic implant.
 - It then corrects the artifact-corrupted data, often using an iterative process or by interpolating the data in the affected regions.[\[4\]](#)
- **Generate Corrected Attenuation Map:** The corrected CT image is used to generate a more accurate attenuation map for the PET data.[\[4\]](#)
- **Reconstruct PET Data:** The PET data is reconstructed using the corrected attenuation map.[\[4\]](#)
- **Review and Compare:** Always compare the MAR-corrected PET images with the uncorrected and non-attenuation-corrected images to ensure the validity of the findings.[\[4\]](#)

Visualizations



[Click to download full resolution via product page](#)

Caption: Mechanism of FDG uptake and metabolic trapping in tumor cells.



[Click to download full resolution via product page](#)

Need Custom Synthesis?

BenchChem offers custom synthesis for rare earth carbides and specific isotopic labeling.

Email: info@benchchem.com or [Request Quote Online](#).

References

- 1. researchgate.net [researchgate.net]
- 2. cme.lww.com [cme.lww.com]
- 3. jnm.snmjournals.org [jnm.snmjournals.org]
- 4. benchchem.com [benchchem.com]
- 5. researchgate.net [researchgate.net]
- 6. Quantitative Effect of Metal Artefact Reduction on CT-based attenuation correction in FDG PET/CT in patients with hip prosthesis - PMC [pmc.ncbi.nlm.nih.gov]
- 7. tech.snmjournals.org [tech.snmjournals.org]
- 8. jnm.snmjournals.org [jnm.snmjournals.org]
- 9. m.youtube.com [m.youtube.com]
- 10. Impact of different metal artifact reduction techniques on attenuation correction in 18F-FDG PET/CT examinations - PMC [pmc.ncbi.nlm.nih.gov]
- 11. Respiratory-Gated PET/CT versus Delayed Images for the Quantitative Evaluation of Lower Pulmonary and Hepatic Lesions - PMC [pmc.ncbi.nlm.nih.gov]
- 12. Respiratory 4D-Gating F-18 FDG PET/CT Scan for Liver Malignancies: Feasibility in Liver Cancer Patient and Tumor Quantitative Analysis - PMC [pmc.ncbi.nlm.nih.gov]
- 13. Impact of Respiratory-gated 4D PET/CT Scan for Motion Correction in Characterizing Lesions Adjacent to the Diaphragm – A Cross-sectional Study at a Tertiary Care Institute - PMC [pmc.ncbi.nlm.nih.gov]
- To cite this document: BenchChem. [Technical Support Center: Troubleshooting Common Artifacts in FDG-PET/CT Imaging]. BenchChem, [2025]. [Online PDF]. Available at: [https://www.benchchem.com/product/b15553411#common-artifacts-in-fd-1080-imaging-and-their-solutions]

Disclaimer & Data Validity:

The information provided in this document is for Research Use Only (RUO) and is strictly not intended for diagnostic or therapeutic procedures. While BenchChem strives to provide accurate protocols, we make no warranties, express or implied, regarding the fitness of this product for every specific experimental setup.

Technical Support: The protocols provided are for reference purposes. Unsure if this reagent suits your experiment? [[Contact our Ph.D. Support Team for a compatibility check](#)]

Need Industrial/Bulk Grade? [Request Custom Synthesis Quote](#)

BenchChem

Our mission is to be the trusted global source of essential and advanced chemicals, empowering scientists and researchers to drive progress in science and industry.

Contact

Address: 3281 E Guasti Rd
Ontario, CA 91761, United States
Phone: (601) 213-4426
Email: info@benchchem.com