

# Technical Support Center: Troubleshooting Artifacts in Pentixafor PET Imaging

**Author:** BenchChem Technical Support Team. **Date:** December 2025

## Compound of Interest

Compound Name: *Pentixafor*

Cat. No.: *B1454180*

[Get Quote](#)

This technical support center provides researchers, scientists, and drug development professionals with a comprehensive guide to identifying, avoiding, and correcting common artifacts encountered during [68Ga]Ga-**Pentixafor** PET imaging.

## Frequently Asked Questions (FAQs)

Q1: What are the most common sources of artifacts in **Pentixafor** PET imaging?

Artifacts in **Pentixafor** PET imaging can be broadly categorized into three groups:

- **Patient-Related Artifacts:** These are caused by patient movement (both voluntary and involuntary, such as breathing), and the presence of metallic implants.
- **Technical Artifacts:** These arise from the imaging equipment and data processing, including issues with CT-based attenuation correction (e.g., from contrast agents) and image reconstruction parameters.
- **Physiological Pitfalls:** These relate to the normal biodistribution of **Pentixafor**, where high physiological uptake in certain organs can be misinterpreted as pathological findings.

Q2: How can patient motion affect my **Pentixafor** PET images?

Patient motion during a PET/CT scan can lead to misregistration between the PET and CT data.<sup>[1][2]</sup> This can result in inaccurate localization of tracer uptake and blurring of the images, potentially obscuring small lesions or creating the appearance of lesions where none exist.<sup>[1]</sup>

Respiratory motion is a common issue, particularly affecting the upper abdomen and lower chest.[3]

Q3: Can metallic implants, like dental fillings or hip prostheses, interfere with **Pentixafor** PET scans?

Yes. Metallic implants cause significant artifacts on CT scans, appearing as bright and dark streaks.[4] Since the CT data is used to correct for photon attenuation in the PET data, these CT artifacts can propagate into the final PET image.[4][5] This can lead to either falsely high or falsely low tracer uptake in the areas surrounding the implant, potentially leading to an incorrect interpretation of the scan.[4][5]

Q4: What is the normal biodistribution of [68Ga]Ga-**Pentixafor**, and how can I avoid misinterpreting it?

[68Ga]Ga-**Pentixafor** shows physiological uptake in several organs, which is important to recognize to avoid misinterpretation. The tracer is primarily cleared by the kidneys, leading to intense activity in the kidneys and bladder.[6][7] Significant physiological uptake is also commonly seen in the spleen, adrenal glands, nasopharynx, palatine tonsils, and thymus.[6][8] In pediatric patients, higher uptake in the bone and thymus is normal.[6] Understanding this normal distribution is key to correctly identifying pathological CXCR4 expression.

## Troubleshooting Guides

### Issue 1: Blurry Images and Misaligned PET/CT Data

Cause: Patient motion (voluntary or involuntary, e.g., respiratory).[1][9]

How to Identify:

- Visual inspection of fused PET/CT images shows a mismatch between anatomical structures on the CT and the corresponding areas of PET uptake.
- The edges of organs and lesions on the PET image appear blurred or smeared.
- Maximum Intensity Projection (MIP) images may reveal discontinuous structures or "step" artifacts.

#### Solutions and Avoidance Strategies:

- **Patient Comfort and Communication:** Ensure the patient is comfortable before starting the scan to minimize voluntary movement. Clear instructions to the patient about the importance of remaining still are crucial.[2]
- **Immobilization Devices:** Use of headrests, straps, and other immobilization devices can help reduce patient motion.
- **Motion Correction Techniques:**
  - **Gating:** Respiratory and cardiac gating techniques acquire data in sync with the patient's breathing or heartbeat, respectively. Dual cardiac/respiratory gating has been shown to provide the strongest CXCR4 PET signal and highest lesion detectability in coronary artery imaging.[10]
  - **Data-Driven Methods:** These techniques retrospectively analyze the PET data itself to detect and correct for motion.[9]

## Issue 2: Areas of Falsely High or Low Uptake Around Metallic Implants

Cause: CT artifacts from metallic objects propagating into the attenuation correction map.[4][5]

#### How to Identify:

- Streaking artifacts are visible on the CT image originating from a metallic implant.
- The PET image shows corresponding areas of artificially high or low uptake that follow the pattern of the CT artifact and do not correspond to plausible biology.[5]
- Reviewing the non-attenuation-corrected (NAC) PET images can help confirm if a "hot spot" is due to an artifact, as the artifact will be absent or less prominent on the NAC images.[11]

#### Solutions and Avoidance Strategies:

- **Metal Artifact Reduction (MAR) Algorithms:** Many modern CT scanners have built-in MAR software that can be applied during image reconstruction to reduce the severity of metal artifacts.[5][12] Using the MAR-corrected CT for attenuation correction can significantly improve the accuracy of the PET data.[5]
- **Alternative Attenuation Correction:** In some cases, if MAR is not available or effective, it may be necessary to manually correct the attenuation map or use alternative methods, though this is less common in clinical practice.

### Issue 3: Unexpected "Hot Spots" in Healthy Tissues

Cause: Misinterpretation of normal physiological uptake of [68Ga]Ga-**Pentixafor**. [6][8]

How to Identify:

- High tracer uptake is observed in organs known for physiological **Pentixafor** accumulation, such as the spleen, kidneys, bladder, adrenal glands, and lymphoid tissues of the head and neck.[6]
- The uptake pattern is diffuse and follows the anatomical boundaries of the organ, rather than being a focal, unexpected lesion.

Solutions and Avoidance Strategies:

- **Familiarity with Normal Biodistribution:** It is crucial for interpreting physicians and researchers to be thoroughly familiar with the physiological distribution of [68Ga]Ga-**Pentixafor**.
- **Quantitative Analysis:** Comparing the Standardized Uptake Values (SUV) of the area in question to known physiological ranges can aid in differentiation.
- **Dual-Time-Point Imaging:** Imaging at a later time point (e.g., 60 minutes post-injection) can sometimes improve the target-to-background ratio, as physiological uptake in some tissues may decrease over time relative to pathological uptake.[6] For example, imaging at 60 minutes has been suggested to provide superior contrast compared to 30 minutes.[6]

- **Bladder Activity:** To minimize artifacts from high bladder activity, especially for pelvic imaging, adequate patient hydration and encouraging the patient to void immediately before the scan can be helpful.

## Quantitative Data Summary

Table 1: Physiological Uptake of [68Ga]Ga-**Pentixafor** in Normal Organs

Organ	Mean SUVmax	Notes
Spleen	High	Considerable physiologic uptake is normal. <a href="#">[13]</a>
Kidneys	Intense	Primary route of tracer excretion. <a href="#">[6]</a>
Bladder	Intense	Due to urinary excretion of the tracer. <a href="#">[6]</a> <a href="#">[14]</a>
Adrenal Glands	Obvious	<a href="#">[6]</a>
Nasopharynx	Obvious	<a href="#">[6]</a>
Palatine Tonsils	Obvious	<a href="#">[6]</a>
Thymus	Obvious	Higher in females and pediatric patients. <a href="#">[6]</a>
Bone	Higher in pediatric patients	<a href="#">[6]</a>
Muscle	Higher in males	<a href="#">[6]</a>

Note: SUVmax values can vary depending on the patient, scanner, and reconstruction parameters. This table provides a general guide.

## Experimental Protocols

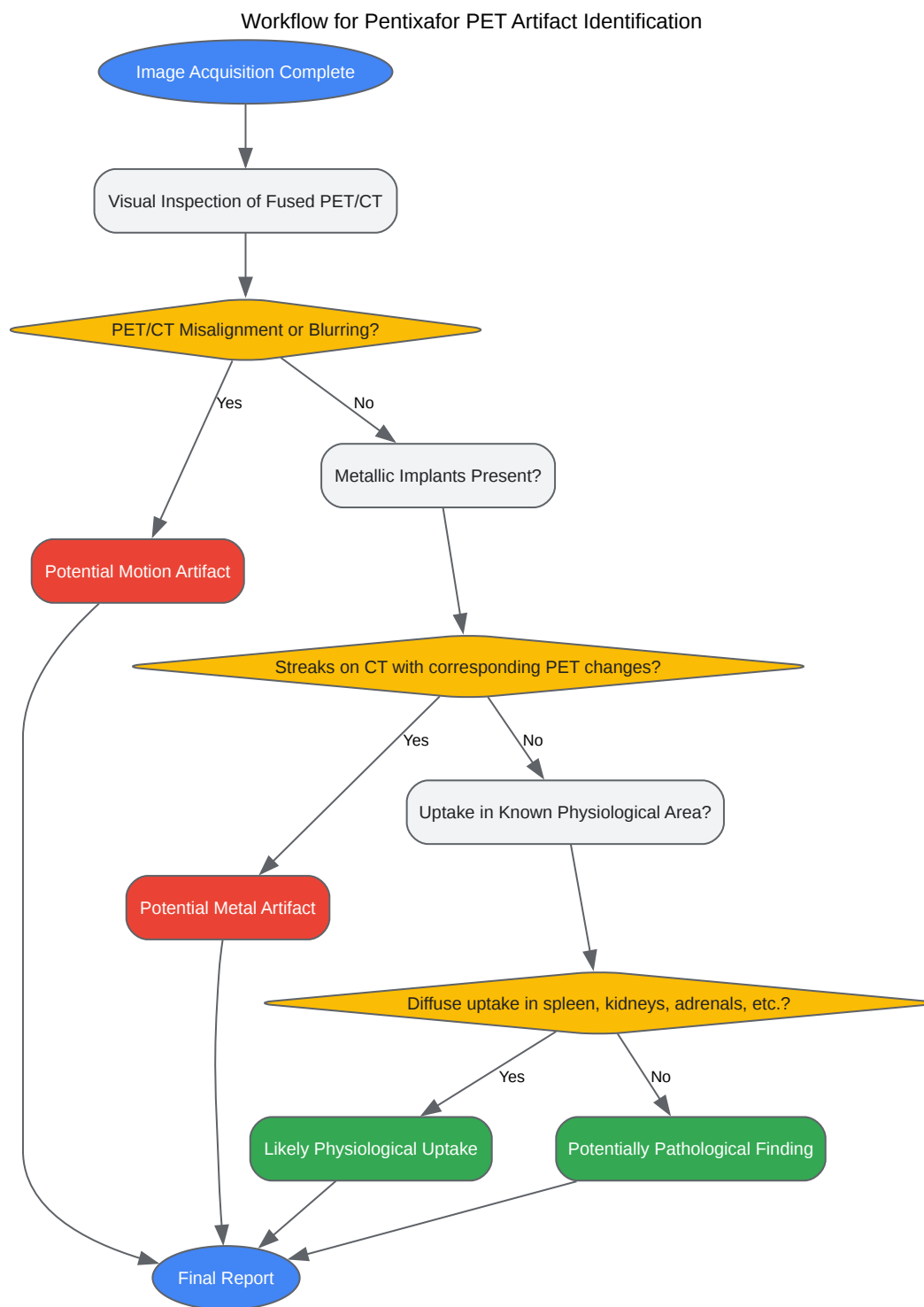
Recommended Protocol for [68Ga]Ga-**Pentixafor** PET/CT Imaging to Minimize Artifacts

- **Patient Preparation:**

- No specific patient preparation such as fasting is required.[\[15\]](#)[\[16\]](#)
- Ensure the patient is well-hydrated.
- Instruct the patient to void immediately before the scan to reduce bladder activity.
- Explain the procedure clearly and emphasize the need to remain still.
- Radiotracer Administration:
  - Administer an intravenous injection of  $150 \pm 50$  MBq of  $[^{68}\text{Ga}]\text{Ga-Pentixafor}$ .[\[7\]](#)
- Uptake Time:
  - An uptake period of  $60 \pm 15$  minutes is commonly used.[\[7\]](#) Good image quality has been reported for scans obtained between 30 and 90 minutes post-injection.[\[7\]](#) The highest target-to-background ratios have been observed at 30 minutes post-injection.[\[7\]](#)
- Image Acquisition:
  - CT Scan:
    - Perform a low-dose CT scan for attenuation correction and anatomical localization.[\[13\]](#)  
[\[15\]](#)
    - Position the patient with arms up if possible to avoid beam hardening artifacts.
    - If metallic implants are present, use a Metal Artifact Reduction (MAR) algorithm if available.
  - PET Scan:
    - Acquire PET data in 3D mode.
    - Use motion correction techniques (e.g., respiratory gating) if available, especially for thoracic and abdominal imaging.[\[10\]](#)
- Image Reconstruction:

- Use an iterative reconstruction algorithm such as Ordered Subset Expectation Maximization (OSEM).[\[14\]](#)[\[17\]](#)
- Apply corrections for attenuation (using the (MAR-corrected) CT data), scatter, and random coincidences.[\[14\]](#)
- To avoid reconstruction artifacts from very high bladder activity, some studies have omitted scatter correction, although this should be considered carefully based on the specific imaging goals.[\[14\]](#)

## Visualizations

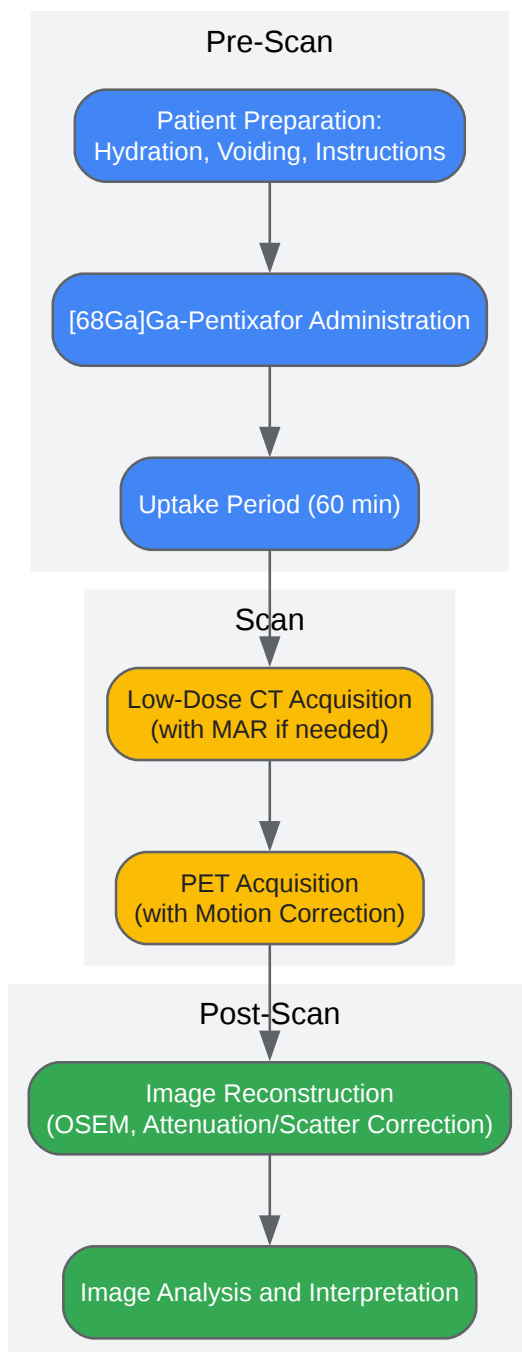


[Click to download full resolution via product page](#)

Caption: A flowchart for identifying common artifacts in **Pentixafor** PET imaging.



## Experimental Workflow for Artifact Avoidance



[Click to download full resolution via product page](#)

Caption: A recommended workflow to minimize artifacts in **Pentixafor** PET imaging.

**Need Custom Synthesis?**

BenchChem offers custom synthesis for rare earth carbides and specific isotopic labeling.

Email: [info@benchchem.com](mailto:info@benchchem.com) or [Request Quote Online](#).

## References

- 1. Frontiers | Normal Variants, Pitfalls, and Artifacts in Ga-68 Prostate Specific Membrane Antigen (PSMA) PET/CT Imaging [frontiersin.org]
- 2. Recognizing and preventing artifacts with SPECT and PET imaging | Radiology Key [radiologykey.com]
- 3. Normal Variants, Pitfalls and Artifacts in Ga-68 DOTATATE PET/CT Imaging - PMC [pmc.ncbi.nlm.nih.gov]
- 4. Metal artifact reduction strategies for improved attenuation correction in hybrid PET/CT imaging - PubMed [pubmed.ncbi.nlm.nih.gov]
- 5. Metal Artifact Reduction of CT Scans to Improve PET/CT - PubMed [pubmed.ncbi.nlm.nih.gov]
- 6. Physiological biodistribution of 68Ga-Pentixafor: PET/CT evaluation and implications for CXCR4 imaging - PubMed [pubmed.ncbi.nlm.nih.gov]
- 7. Advances in PET imaging of the CXCR4 Receptor: [68Ga]Ga-PentixaFor - PMC [pmc.ncbi.nlm.nih.gov]
- 8. researchgate.net [researchgate.net]
- 9. Motion Artifacts and Correction Techniques in PET/CT | Radiology Key [radiologykey.com]
- 10. Imaging of chemokine receptor CXCR4 expression in culprit and nonculprit coronary atherosclerotic plaque using motion-corrected [68Ga]pentixafor PET/CT - PubMed [pubmed.ncbi.nlm.nih.gov]
- 11. jnm.snmjournals.org [jnm.snmjournals.org]
- 12. Quantitative Effect of Metal Artefact Reduction on CT-based attenuation correction in FDG PET/CT in patients with hip prosthesis - PMC [pmc.ncbi.nlm.nih.gov]
- 13. 68Ga-Pentixafor PET/CT for Imaging of Chemokine Receptor 4 Expression in Waldenström Macroglobulinemia/Lymphoplasmacytic Lymphoma: Comparison to 18F-FDG PET/CT - PMC [pmc.ncbi.nlm.nih.gov]

- 14. [68Ga]pentixafor for CXCR4 imaging in a PC-3 prostate cancer xenograft model – comparison with [18F]FDG PET/CT, MRI and ex vivo receptor expression - PMC [pmc.ncbi.nlm.nih.gov]
- 15. [68Ga]Pentixafor-PET/CT for imaging of chemokine receptor CXCR4 expression in multiple myeloma - Comparison to [18F]FDG and laboratory values - PMC [pmc.ncbi.nlm.nih.gov]
- 16. mdpi.com [mdpi.com]
- 17. Reduced splenic uptake of [68Ga]Ga-Pentixafor following first-line chemotherapy is associated with poor prognosis in patients with newly diagnosed multiple myeloma - PMC [pmc.ncbi.nlm.nih.gov]
- To cite this document: BenchChem. [Technical Support Center: Troubleshooting Artifacts in Pentixafor PET Imaging]. BenchChem, [2025]. [Online PDF]. Available at: [https://www.benchchem.com/product/b1454180#artifacts-in-pentixafor-pet-imaging-and-how-to-avoid-them]

---

#### Disclaimer & Data Validity:

The information provided in this document is for Research Use Only (RUO) and is strictly not intended for diagnostic or therapeutic procedures. While BenchChem strives to provide accurate protocols, we make no warranties, express or implied, regarding the fitness of this product for every specific experimental setup.

**Technical Support:** The protocols provided are for reference purposes. Unsure if this reagent suits your experiment? [[Contact our Ph.D. Support Team for a compatibility check](#)]

**Need Industrial/Bulk Grade?** [Request Custom Synthesis Quote](#)

## BenchChem

Our mission is to be the trusted global source of essential and advanced chemicals, empowering scientists and researchers to drive progress in science and industry.

#### Contact

Address: 3281 E Guasti Rd  
Ontario, CA 91761, United States  
Phone: (601) 213-4426  
Email: [info@benchchem.com](mailto:info@benchchem.com)