

Technical Support Center: Troubleshooting Artifacts in Myocardial Perfusion Imaging (MPI)

Author: BenchChem Technical Support Team. **Date:** December 2025

Compound of Interest

Compound Name: MPI60

Cat. No.: B12383444

[Get Quote](#)

Welcome to the technical support center for Myocardial Perfusion Imaging (MPI). This resource is designed for researchers, scientists, and drug development professionals to help identify and resolve common artifacts encountered during MPI experiments, ensuring the acquisition of high-quality, reliable data.

Frequently Asked Questions (FAQs) & Troubleshooting Guides

This section provides answers to common questions and step-by-step guidance for troubleshooting artifacts in your MPI studies.

Q1: What are the most common artifacts observed in MPI images?

A1: The most frequently encountered artifacts in MPI can be broadly categorized as patient-related, instrumentation-related, and processing-related. The primary artifacts include:

- **Soft Tissue Attenuation:** Caused by the absorption of photons by overlying tissues like the breast or diaphragm, leading to artificially reduced counts in the myocardial wall.
- **Patient Motion:** Movement during image acquisition can cause blurring and misregistration of images, potentially mimicking perfusion defects.

- **Extracardiac Activity:** Uptake of the radiotracer in adjacent organs, such as the liver or gut, can interfere with the visualization of the myocardium.
- **SPECT/CT Misregistration:** Misalignment between the SPECT and CT images in hybrid imaging can lead to incorrect attenuation correction and the creation of artificial defects.
- **Instrumentation Malfunctions:** Issues with the gamma camera, such as non-uniformity or center of rotation errors, can introduce systemic artifacts.

Q2: How can I identify soft tissue attenuation in my images, and what are the steps to correct it?

A2: Soft tissue attenuation typically appears as a fixed perfusion defect in a location corresponding to the attenuating tissue (e.g., anterior wall defect from breast tissue, inferior wall defect from the diaphragm).

Troubleshooting Steps:

- **Review Raw Cine Data:** Visually inspect the rotating raw projection images to identify any overlying soft tissue that may be causing attenuation.
- **Prone Imaging:** Acquire additional images with the patient in the prone position. A perfusion defect that resolves or changes location on prone imaging is likely an artifact.
- **Gated SPECT:** Assess regional wall motion. A fixed defect with normal wall motion is suggestive of an artifact rather than an infarct.
- **Attenuation Correction (AC):** If available, utilize CT-based attenuation correction. Compare the non-corrected (NAC) and AC images. A defect that is resolved or significantly improved on the AC images is likely due to attenuation.^[1]
- **Evaluate Patient Positioning:** Ensure proper patient positioning to minimize attenuation. For female patients, careful positioning of the breasts away from the heart can be beneficial.

Q3: My images appear blurry or show misaligned structures. How do I address potential patient motion?

A3: Patient motion artifacts can manifest as a "hurricane sign" (streaks emanating from the heart) or misaligned walls on reconstructed images.

Troubleshooting Steps:

- **Inspect Raw Cine Data:** Review the raw projection data in a cinematic display to visually detect any patient movement during the scan.
- **Motion Correction Software:** Utilize available software to correct for motion. Be aware that automated correction may sometimes introduce new artifacts, so a visual inspection of the corrected data is crucial.[2] In cases of mild or no motion, it may be preferable to avoid correction.
- **Patient Comfort and Immobilization:** Ensure the patient is comfortable and well-immobilized before starting the acquisition to minimize the likelihood of movement.
- **Repeat Acquisition:** If significant motion is detected and cannot be corrected, the acquisition should be repeated.

Q4: There is high signal intensity from the liver or gut obscuring the inferior wall of the myocardium. What can I do to mitigate this?

A4: Extracardiac activity, particularly from the liver and gastrointestinal tract, can interfere with the assessment of the inferior myocardial wall.

Troubleshooting Steps:

- **Delayed Imaging:** For ^{99m}Tc -based tracers, delaying the imaging for 30-60 minutes after injection can allow for greater clearance from the liver and gut.
- **Fatty Meal:** For ^{99m}Tc -sestamibi, administering a fatty meal after tracer injection can promote gallbladder contraction and clearance of hepatobiliary activity.
- **Prone Imaging:** As with attenuation artifacts, prone imaging can help to separate the heart from the subdiaphragmatic activity.

- **Review Raw Data:** Carefully examine the raw data to understand the proximity and intensity of the extracardiac activity relative to the heart.

Quantitative Data on MPI Artifacts

The following tables summarize common artifacts and provide quantitative data on their prevalence and the effectiveness of correction techniques.

Table 1: Summary of Common MPI Artifacts and Solutions

Artifact	Cause	Appearance	Troubleshooting & Correction
Soft Tissue Attenuation	Photon absorption by breast, diaphragm, or lateral chest wall.	Fixed perfusion defects, most commonly in the anterior or inferior walls.	Prone imaging, gated SPECT to assess wall motion, CT-based attenuation correction.
Patient Motion	Voluntary or involuntary patient movement during acquisition.	Blurring of myocardial walls, "hurricane sign," misregistration of stress/rest images.	Review of raw cine data, motion correction software, patient immobilization, repeat acquisition.
Extracardiac Activity	Radiotracer uptake in the liver, gallbladder, or bowel.	High signal intensity adjacent to the heart, potentially obscuring the inferior wall or creating scatter artifacts.	Delayed imaging, fatty meal (for 99mTc-sestamibi), prone imaging.
SPECT/CT Misregistration	Patient movement between SPECT and CT acquisition.	Incorrect attenuation correction leading to artificial perfusion defects.	Visual inspection of fused SPECT/CT images, software-based reregistration.
Left Bundle Branch Block (LBBB)	Abnormal septal contraction leading to reduced blood flow.	Reversible or fixed perfusion defect in the interventricular septum.	Pharmacologic stress (vasodilator) is preferred over exercise stress to minimize the artifact.

Table 2: Prevalence of Artifacts and Efficacy of Correction Techniques

Artifact/Correction	Finding	Reported Values
Subdiaphragmatic Activity	Prevalence in SPECT imaging	Interferes with inferior wall evaluation in 10-50% of cases. [3]
SPECT/CT Misregistration	Incidence of misalignment >1 pixel	73% of studies.[4][5]
SPECT/CT Misregistration	Incidence of misalignment >2 pixels	23% of studies.[5]
Attenuation Correction (AC)	Impact on specificity for Right Coronary Artery (RCA) disease	Increased from 77.9% to 98.7%. [1]
Motion Correction (Respiratory)	Impact on diagnostic performance for CAD (AUC) in patients with >15mm motion	Improved from 0.682 (no correction) to 0.731 (with correction).[2]

Experimental Protocols

Myocardial Perfusion Imaging (MPI) Acquisition Protocol (Example using 99mTc-based tracer)

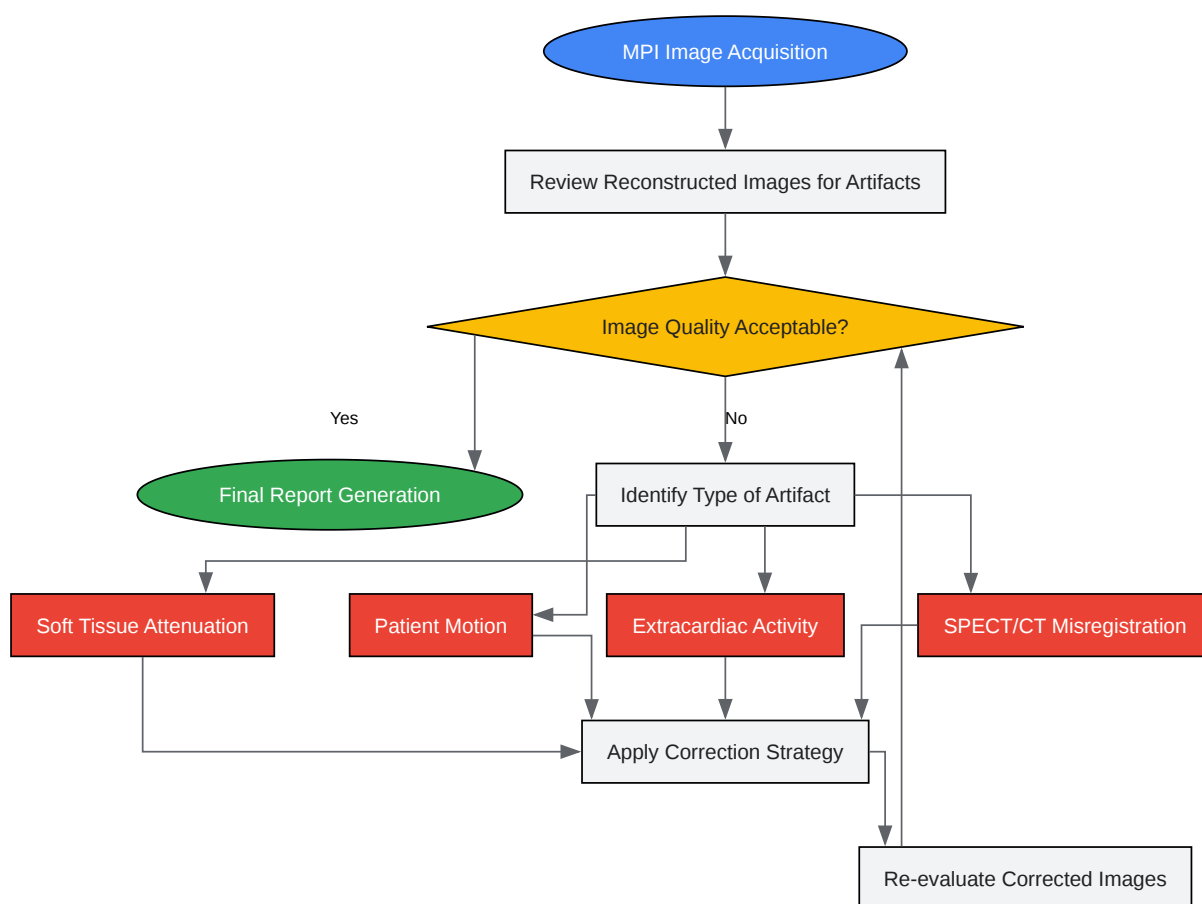
- Patient Preparation:
 - Patients should fast for at least 4 hours prior to the study.
 - Caffeine-containing products should be avoided for at least 12-24 hours.
 - Certain cardiac medications may be withheld as per institutional protocol.
- Rest Imaging:
 - An intravenous line is inserted.
 - A dose of 99mTc-sestamibi or 99mTc-tetrofosmin (typically 370-1110 MBq or 10-30 mCi) is injected at rest.
 - Image acquisition begins 30-60 minutes post-injection to allow for hepatobiliary clearance.

- Stress Testing:
 - Can be performed using either exercise (treadmill or bicycle) or pharmacologic agents (e.g., adenosine, dipyridamole, or regadenoson).
 - The goal of exercise stress is to achieve at least 85% of the age-predicted maximum heart rate.
 - Pharmacologic stress involves the infusion of a vasodilator to maximize coronary blood flow.
- Stress Imaging:
 - At peak stress, a higher dose of the ^{99m}Tc-based tracer (typically 740-1480 MBq or 20-40 mCi) is injected.
 - Image acquisition begins 15-60 minutes post-injection.
- SPECT Image Acquisition:
 - A gamma camera equipped with a low-energy, high-resolution collimator is used.
 - Data is typically acquired over a 180° arc (from 45° right anterior oblique to 45° left posterior oblique).
 - The acquisition is synchronized with the patient's ECG (gated SPECT) to assess myocardial wall motion and thickening.
 - For SPECT/CT, a low-dose CT scan is acquired for attenuation correction.
- Image Processing and Reconstruction:
 - Raw data is reconstructed using an iterative algorithm (e.g., Ordered Subsets Expectation Maximization - OSEM).
 - Attenuation and scatter correction are applied.

- The reconstructed images are reoriented into the standard short-axis, vertical long-axis, and horizontal long-axis views of the heart.

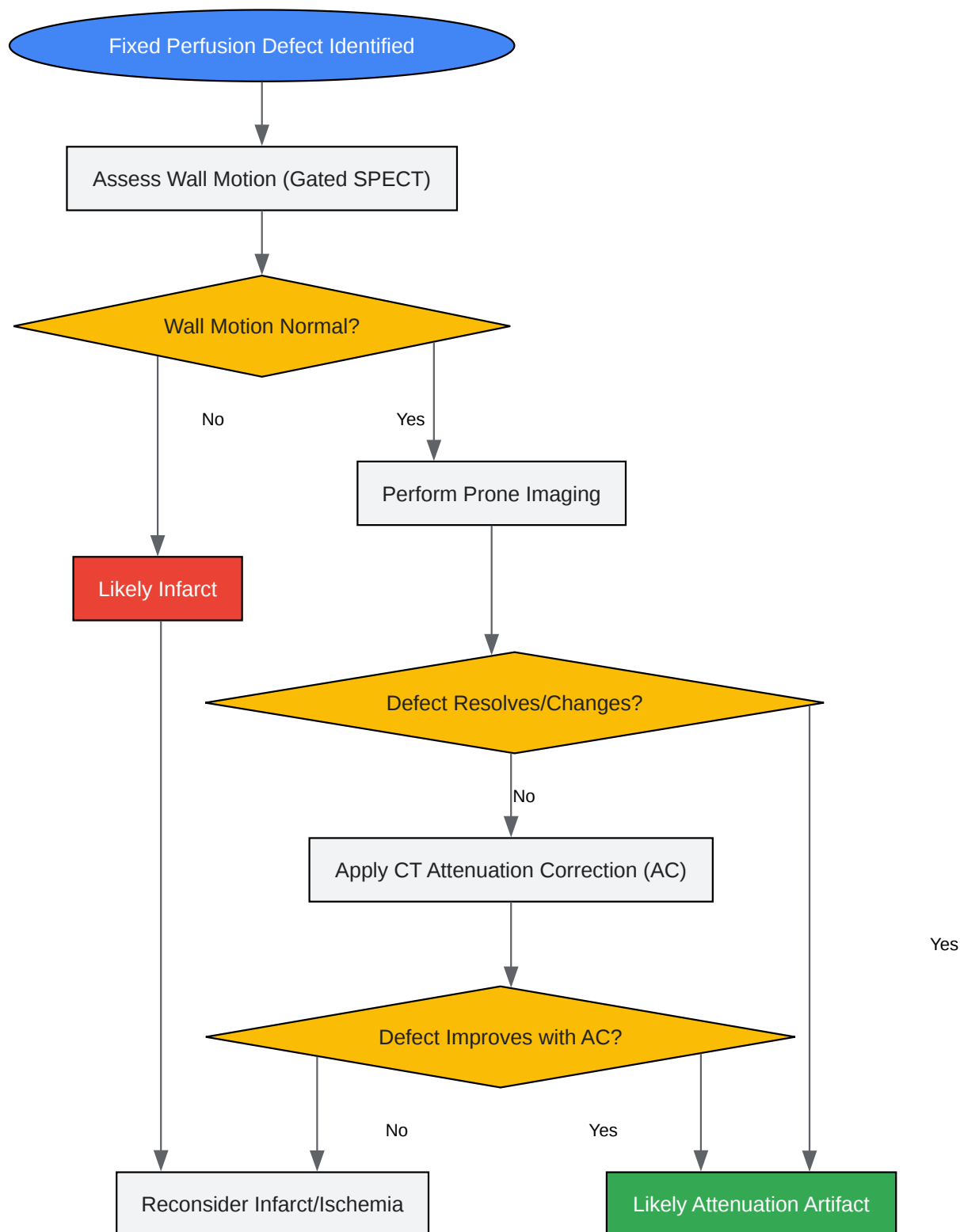
Visualizations

Diagrams of Workflows and Logical Relationships



[Click to download full resolution via product page](#)

General workflow for identifying and correcting artifacts in MPI.



[Click to download full resolution via product page](#)

Decision-making workflow for suspected attenuation artifacts.

Need Custom Synthesis?

BenchChem offers custom synthesis for rare earth carbides and specific isotopic labeling.

Email: info@benchchem.com or [Request Quote Online](#).

References

- 1. Clinical Utility of CT-based Attenuation-correction in Myocardial Perfusion SPECT Imaging - PMC [[pmc.ncbi.nlm.nih.gov](https://pubmed.ncbi.nlm.nih.gov/)]
- 2. jnm.snmjournals.org [jnm.snmjournals.org]
- 3. Subdiaphragmatic activity-related artifacts in myocardial perfusion scintigraphy - PMC [[pmc.ncbi.nlm.nih.gov](https://pubmed.ncbi.nlm.nih.gov/)]
- 4. irjnm.tums.ac.ir [irjnm.tums.ac.ir]
- 5. jnm.snmjournals.org [jnm.snmjournals.org]
- To cite this document: BenchChem. [Technical Support Center: Troubleshooting Artifacts in Myocardial Perfusion Imaging (MPI)]. BenchChem, [2025]. [Online PDF]. Available at: [<https://www.benchchem.com/product/b12383444#common-artifacts-in-mpi60-images-and-how-to-fix-them>]

Disclaimer & Data Validity:

The information provided in this document is for Research Use Only (RUO) and is strictly not intended for diagnostic or therapeutic procedures. While BenchChem strives to provide accurate protocols, we make no warranties, express or implied, regarding the fitness of this product for every specific experimental setup.

Technical Support: The protocols provided are for reference purposes. Unsure if this reagent suits your experiment? [[Contact our Ph.D. Support Team for a compatibility check](#)]

Need Industrial/Bulk Grade? [Request Custom Synthesis Quote](#)

BenchChem

Our mission is to be the trusted global source of essential and advanced chemicals, empowering scientists and researchers to drive progress in science and industry.

Contact

Address: 3281 E Guasti Rd

Ontario, CA 91761, United States

Phone: (601) 213-4426

Email: info@benchchem.com