

Technical Support Center: Troubleshooting [18F]FETA PET Imaging Artifacts

Author: BenchChem Technical Support Team. **Date:** December 2025

Compound of Interest

Compound Name: Etanidazole

Cat. No.: B1684559

[Get Quote](#)

Welcome to the technical support center for O-(2-[18F]fluoroethyl)-L-tyrosine ([18F]FETA) PET imaging. This resource is designed for researchers, scientists, and drug development professionals to provide guidance on troubleshooting common artifacts and issues encountered during [18F]FETA PET experiments.

Frequently Asked Questions (FAQs)

Q1: What is the primary clinical application of [18F]FETA PET imaging?

A1: [18F]FETA is an amino acid radiotracer primarily used for brain tumor imaging with positron emission tomography (PET).^{[1][2]} It is particularly valuable for the initial diagnosis, grading, and delineation of tumor extent for biopsy and surgical planning.^[1] Furthermore, it aids in differentiating tumor recurrence from treatment-related changes and in monitoring therapy response.^[2]

Q2: How does the uptake mechanism of [18F]FETA differ from [18F]FDG?

A2: [18F]FETA is an artificial amino acid analogue whose uptake is mediated by amino acid transporters, particularly the L-type amino acid transport system, which is upregulated in tumor cells.^[1] Unlike [18F]FDG, its uptake is independent of the blood-brain barrier's integrity. This results in lower background signal in the normal brain parenchyma compared to the high glucose metabolism seen with [18F]FDG, leading to better tumor-to-background contrast.

Q3: Are there specific patient preparation requirements for an [18F]FETA PET scan?

A3: While specific institutional protocols may vary, general patient preparation for [18F]FETA PET aims to minimize physiological uptake variations. Unlike [18F]FDG PET, which requires a period of fasting and blood glucose level monitoring due to the tracer being a glucose analog, specific dietary restrictions for [18F]FETA are less stringent. However, to ensure standardization, especially in longitudinal studies, it is recommended that patients fast for at least 4-6 hours prior to the scan. Patients should be well-hydrated and should void immediately before the scan to reduce bladder activity. Strenuous physical activity should be avoided for at least 24 hours before the scan to prevent non-specific muscle uptake.

Q4: What are the common causes of artifacts in PET/CT imaging in general?

A4: Artifacts in PET/CT imaging can arise from patient-related factors, technical issues, or the scanner itself. Common causes include patient motion, metallic implants, truncation of the CT field of view, and misregistration between the PET and CT images. These can lead to inaccurate attenuation correction and erroneous measurements of tracer uptake.

Troubleshooting Guide: Image Quality and Artifacts

This guide addresses specific issues that users may encounter during [18F]FETA PET imaging, focusing on image quality and the interpretation of potential artifacts.

Issue 1: High Background Signal in the Brain

Question: My [18F]FETA PET scan of the brain shows a generally high background signal, making it difficult to delineate the tumor. What could be the cause?

Answer:

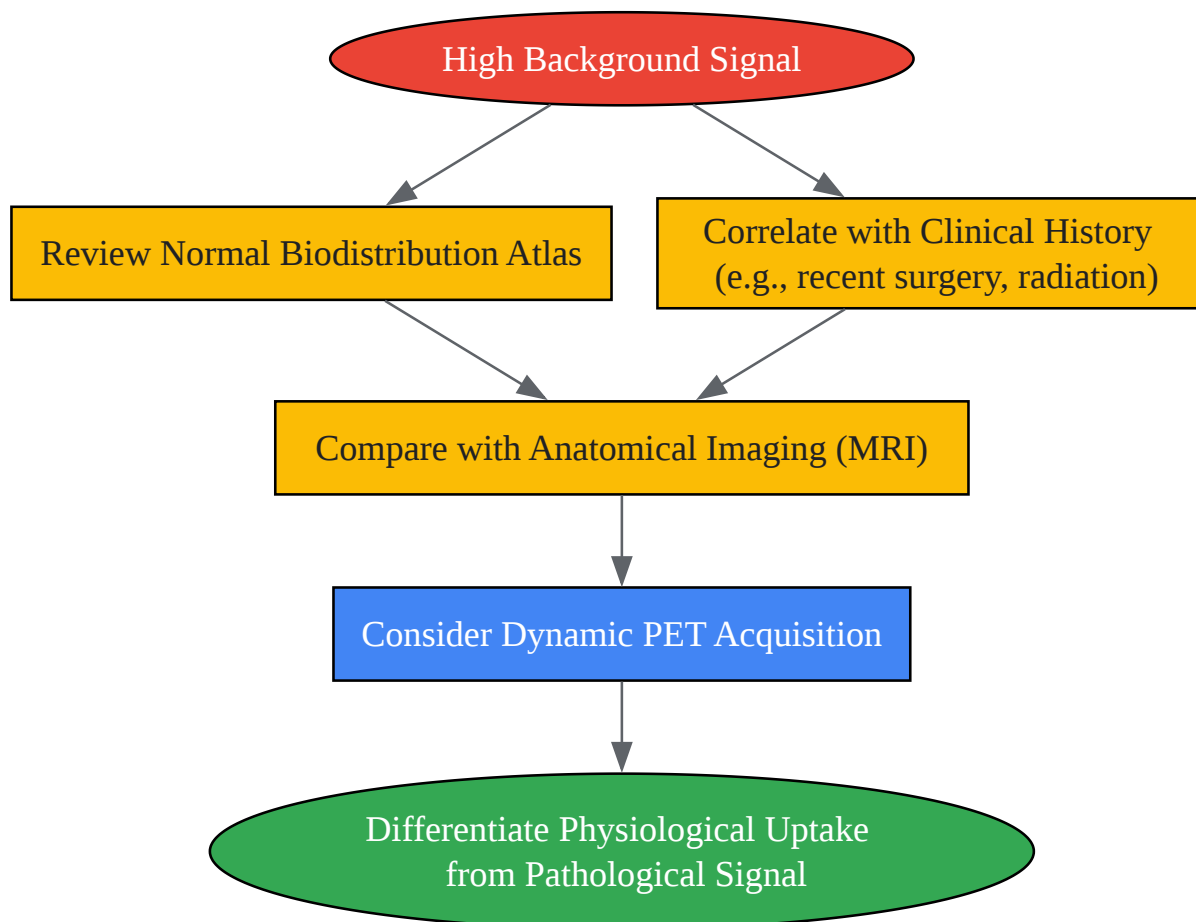
While [18F]FETA typically provides a good tumor-to-background ratio, several factors can contribute to elevated background uptake:

- **Normal Physiological Uptake:** It is important to recognize that certain normal brain structures exhibit physiological [18F]FETA uptake. These include the venous sinuses, cranial muscles, caudate nucleus, pineal gland, putamen, and thalamus.
- **Inflammatory Processes:** Non-neoplastic inflammatory conditions can lead to increased amino acid uptake, although this is less common with [18F]FETA compared to other amino

acid tracers.

- Recent Surgery or Radiotherapy: Post-treatment inflammatory changes can result in increased tracer accumulation, potentially mimicking tumor recurrence.

Troubleshooting Workflow:



[Click to download full resolution via product page](#)

Caption: Troubleshooting High Background Signal in [18F]FETA PET.

Issue 2: Focal Uptake in a Non-Tumorous Region

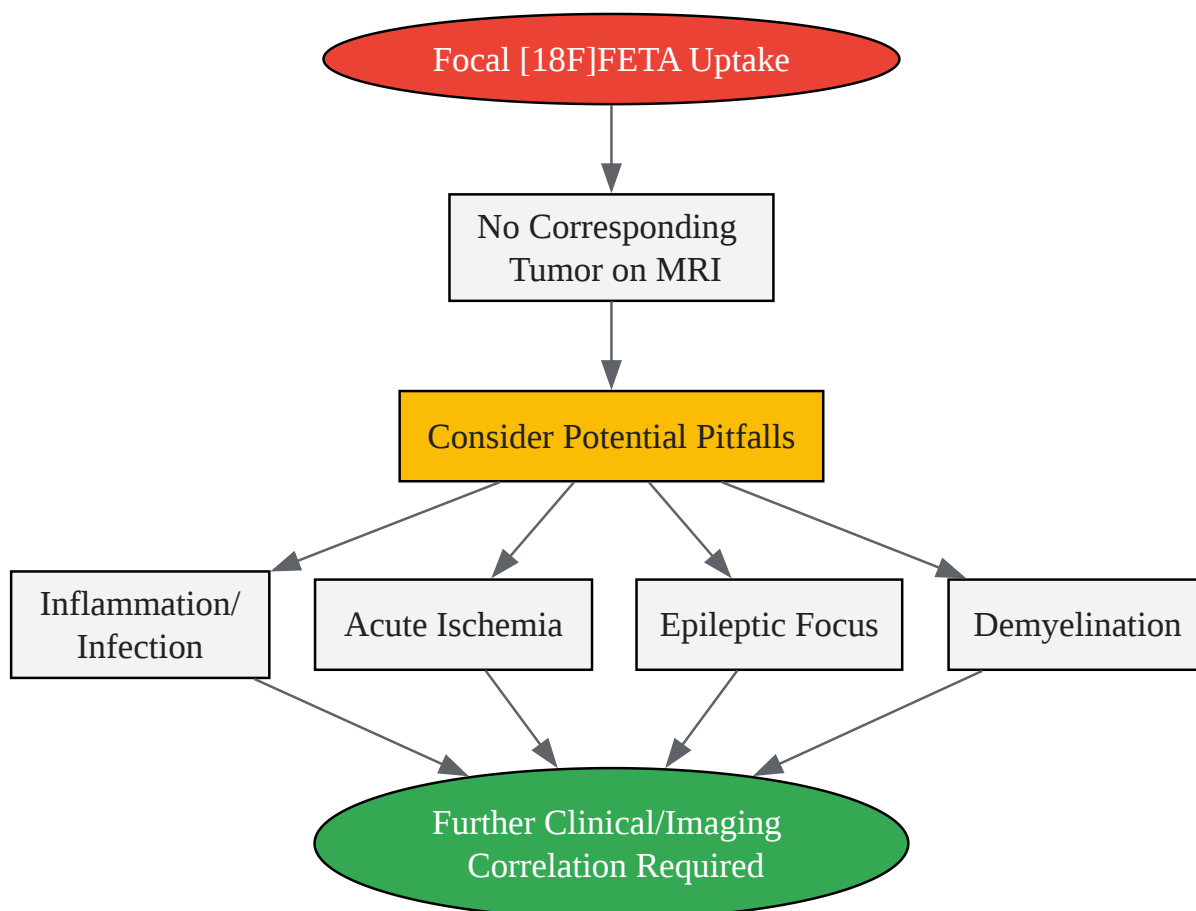
Question: I am observing a focal area of high [18F]FETA uptake in a brain region where no tumor is expected based on MRI. Could this be an artifact?

Answer:

Yes, focal uptake of [18F]FETA in non-tumorous regions can occur and represents a potential pitfall in image interpretation. Causes can include:

- Inflammation or Infection: Brain abscesses or areas of active inflammation can show increased amino acid metabolism.
- Acute Ischemia: In some cases, acute ischemic events can lead to focal tracer uptake.
- Epileptic Foci: Increased metabolic activity in an epileptic focus can result in elevated [18F]FETA accumulation.
- Demyelination: Active demyelinating lesions, such as those in multiple sclerosis, have been reported to show increased uptake in rare cases.

Logical Relationship for Differential Diagnosis:



[Click to download full resolution via product page](#)

Caption: Differential Diagnosis of Focal [18F]FETA Uptake.

Issue 3: Low or No Tumor Uptake

Question: My patient has a confirmed glioma on MRI, but the [18F]FETA PET scan shows low or no uptake. Is this possible?

Answer:

Yes, this is a known phenomenon. Approximately 30% of low-grade gliomas and 5% of high-grade gliomas may not exhibit significant [18F]FETA uptake at the time of initial diagnosis. Additionally, certain tumor subtypes, such as some oligodendrogliomas, may show variable uptake.

Factors Influencing Tumor Uptake:

- **Tumor Grade and Type:** Lower-grade gliomas generally show lower amino acid uptake compared to high-grade gliomas.
- **IDH Mutation Status:** Isocitrate dehydrogenase (IDH)-mutant tumors may exhibit different uptake characteristics compared to IDH-wildtype tumors.
- **Treatment Effects:** Prior treatment, especially with anti-angiogenic agents, can alter tumor metabolism and reduce tracer uptake, a phenomenon known as pseudoresponse.

Quantitative Data Summary

The following tables provide reference values for [18F]FETA uptake in normal brain structures and gliomas. These values can help in differentiating physiological uptake from pathological conditions and in identifying potential artifacts.

Table 1: [18F]FETA PET Reference Values in Normal Brain and Head Structures

Anatomic Structure	Mean SUVmax (\pm SD)	Mean TBR (\pm SD)
Venous Structures		
Superior Sagittal Sinus	2.40 \pm 0.41	2.03 \pm 0.46
Gray Matter Structures		
Caudate Nucleus	1.59 \pm 0.37	1.42 \pm 0.17
Pineal Gland	1.59 \pm 0.37	1.42 \pm 0.17
Putamen	1.59 \pm 0.37	1.42 \pm 0.17
Thalamus	1.59 \pm 0.37	1.42 \pm 0.17
Other Structures		
Cranial Muscles	2.40 \pm 0.41	2.03 \pm 0.46

Data adapted from a study on 70 patients. SUVmax: Maximum Standardized Uptake Value; TBR: Target-to-Background Ratio; SD: Standard Deviation.

Table 2: [18F]FETA PET Parameters in High-Grade and Low-Grade Gliomas

Parameter	High-Grade Glioma (n=41)	Low-Grade Glioma (n=24)
SUVmax (mean \pm SD)	3.53 \pm 1.8	1.97 \pm 1.5
TBR (mean \pm SD)	2.98 \pm 1.1	2.23 \pm 0.9

Data adapted from the same study of 70 patients. Note that there can be an overlap in uptake values between high-grade and low-grade gliomas.

Experimental Protocols

Protocol 1: Quality Control of [18F]FETA Radiopharmaceutical

Ensuring the quality of the [18F]FETA radiopharmaceutical is critical for accurate and reliable imaging results. The following are key quality control parameters:

Quality Control Test	Specification
Appearance	Clear, colorless solution, free of visible particles
pH	4.5 - 7.5
Radiochemical Purity	≥ 95%
Radionuclidic Identity	Half-life of 105-115 minutes
Radionuclidic Purity	≥ 99.9%
Bacterial Endotoxins	< 175/V EU/mL (V = maximum recommended dose in mL)
Sterility	Sterile

Methodology for Radiochemical Purity Testing:

High-Performance Liquid Chromatography (HPLC) is the standard method for determining the radiochemical purity of [18F]FETA.

- Column: A reverse-phase C18 column is typically used.
- Mobile Phase: A mixture of acetonitrile and water or a buffer solution.
- Detection: A radioactivity detector in series with a UV detector.
- Procedure: A small aliquot of the final [18F]FETA product is injected into the HPLC system. The retention time of the main radioactive peak should correspond to that of a non-radioactive FETA standard. The radiochemical purity is calculated as the percentage of the total radioactivity that elutes as [18F]FETA.

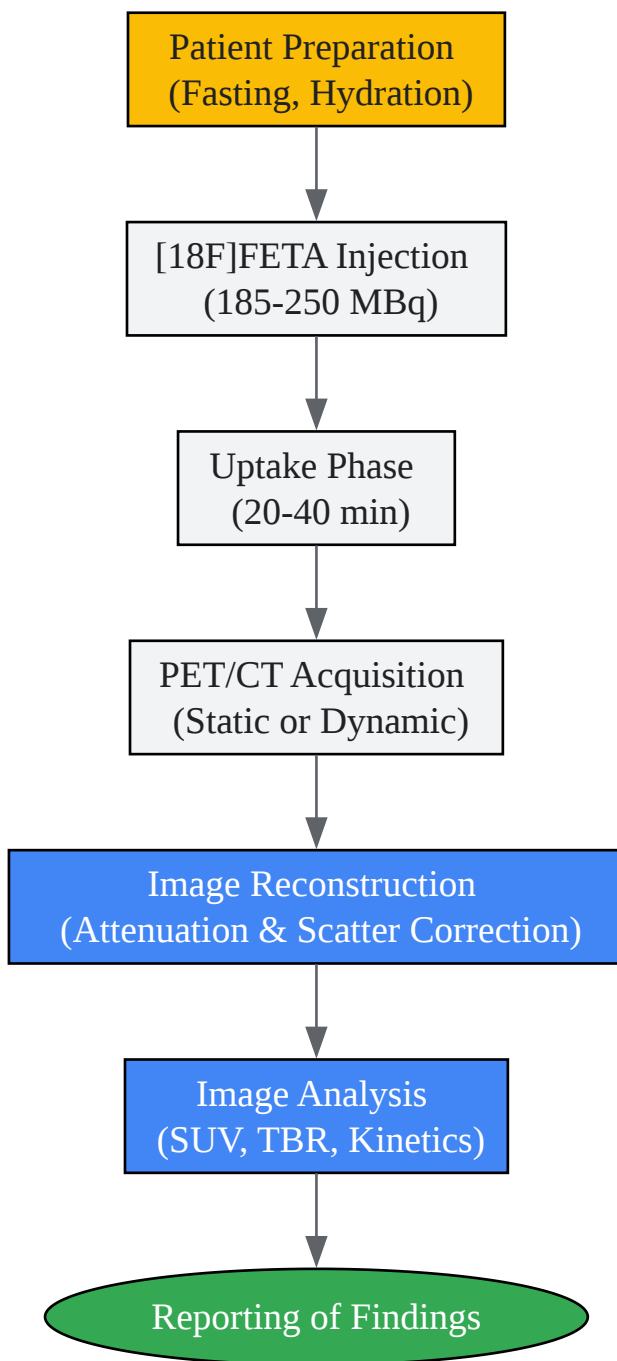
Protocol 2: [18F]FETA PET/CT Imaging of the Brain

This protocol provides a standardized procedure for acquiring high-quality [18F]FETA PET images of the brain.

- Patient Preparation:

- Fast for a minimum of 4 hours prior to tracer injection.
- Ensure the patient is well-hydrated.
- Review the patient's current medications. While specific drug interferences with [18F]FETA are not well-documented, it is good practice to note all medications.
- The patient should rest in a quiet, dimly lit room for 10-15 minutes before and after tracer injection to minimize physiological brain activation.
- Tracer Administration:
 - Administer approximately 185-250 MBq (5-7 mCi) of [18F]FETA intravenously as a bolus injection.
 - The exact dose may be adjusted based on patient weight and scanner characteristics.
- Image Acquisition:
 - Static Acquisition: A static emission scan is typically acquired from 20 to 40 minutes post-injection.
 - Dynamic Acquisition: For a more detailed assessment of tracer kinetics, a dynamic scan can be performed from the time of injection up to 50-60 minutes post-injection. This can help in differentiating high-grade from low-grade gliomas based on the time-activity curves.
 - A low-dose CT scan is acquired for attenuation correction and anatomical localization.
- Image Reconstruction and Analysis:
 - Images should be reconstructed using an iterative algorithm (e.g., OSEM).
 - Attenuation and scatter correction should be applied.
 - For quantitative analysis, regions of interest (ROIs) or volumes of interest (VOIs) are drawn on the tumor and on a reference region in the contralateral healthy brain tissue to calculate SUV and TBR values.

Experimental Workflow for [18F]FETA PET Imaging:



[Click to download full resolution via product page](#)

Caption: Standardized Workflow for [18F]FETA PET Brain Imaging.

Need Custom Synthesis?

BenchChem offers custom synthesis for rare earth carbides and specific isotopic labeling.

Email: info@benchchem.com or [Request Quote Online](#).

References

- 1. epos.myesr.org [epos.myesr.org]
- 2. Contribution of [18F]FET PET in the Management of Gliomas, from Diagnosis to Follow-Up: A Review - PMC [pmc.ncbi.nlm.nih.gov]
- To cite this document: BenchChem. [Technical Support Center: Troubleshooting [18F]FETA PET Imaging Artifacts]. BenchChem, [2025]. [Online PDF]. Available at: [https://www.benchchem.com/product/b1684559#troubleshooting-18f-feta-pet-imaging-artifacts]

Disclaimer & Data Validity:

The information provided in this document is for Research Use Only (RUO) and is strictly not intended for diagnostic or therapeutic procedures. While BenchChem strives to provide accurate protocols, we make no warranties, express or implied, regarding the fitness of this product for every specific experimental setup.

Technical Support: The protocols provided are for reference purposes. Unsure if this reagent suits your experiment? [[Contact our Ph.D. Support Team for a compatibility check](#)]

Need Industrial/Bulk Grade? [Request Custom Synthesis Quote](#)

BenchChem

Our mission is to be the trusted global source of essential and advanced chemicals, empowering scientists and researchers to drive progress in science and industry.

Contact

Address: 3281 E Guasti Rd
Ontario, CA 91761, United States
Phone: (601) 213-4426
Email: info@benchchem.com

