

Technical Support Center: Transvaginal Ultrasound for Adenomyosis Diagnosis

Author: BenchChem Technical Support Team. **Date:** December 2025

Compound of Interest

Compound Name: FR 76830

Cat. No.: B1674034

[Get Quote](#)

This technical support center provides troubleshooting guides and frequently asked questions (FAQs) to help researchers, scientists, and drug development professionals improve the accuracy of transvaginal ultrasound (TVS) for diagnosing adenomyosis.

Frequently Asked Questions (FAQs)

Q1: What are the primary sonographic features of adenomyosis on 2D transvaginal ultrasound?

A1: The diagnosis of adenomyosis via TVS relies on identifying specific morphological changes in the myometrium. The most recognized features include:

- **Heterogeneous Myometrium:** An irregular and non-uniform echotexture within the uterine muscle. This is one of the most common but less specific signs.[\[1\]](#)[\[2\]](#)
- **Myometrial Cysts:** Small anechoic (fluid-filled) spaces or lacunae within the myometrium.[\[3\]](#)
[\[4\]](#) These are considered a highly specific feature.[\[5\]](#)
- **Globular Uterus:** A diffusely enlarged, rounded, and bulky uterus, as opposed to the typical pear shape.[\[6\]](#)
- **Asymmetrical Myometrial Thickening:** The posterior wall of the myometrium is often thicker than the anterior wall.[\[1\]](#)

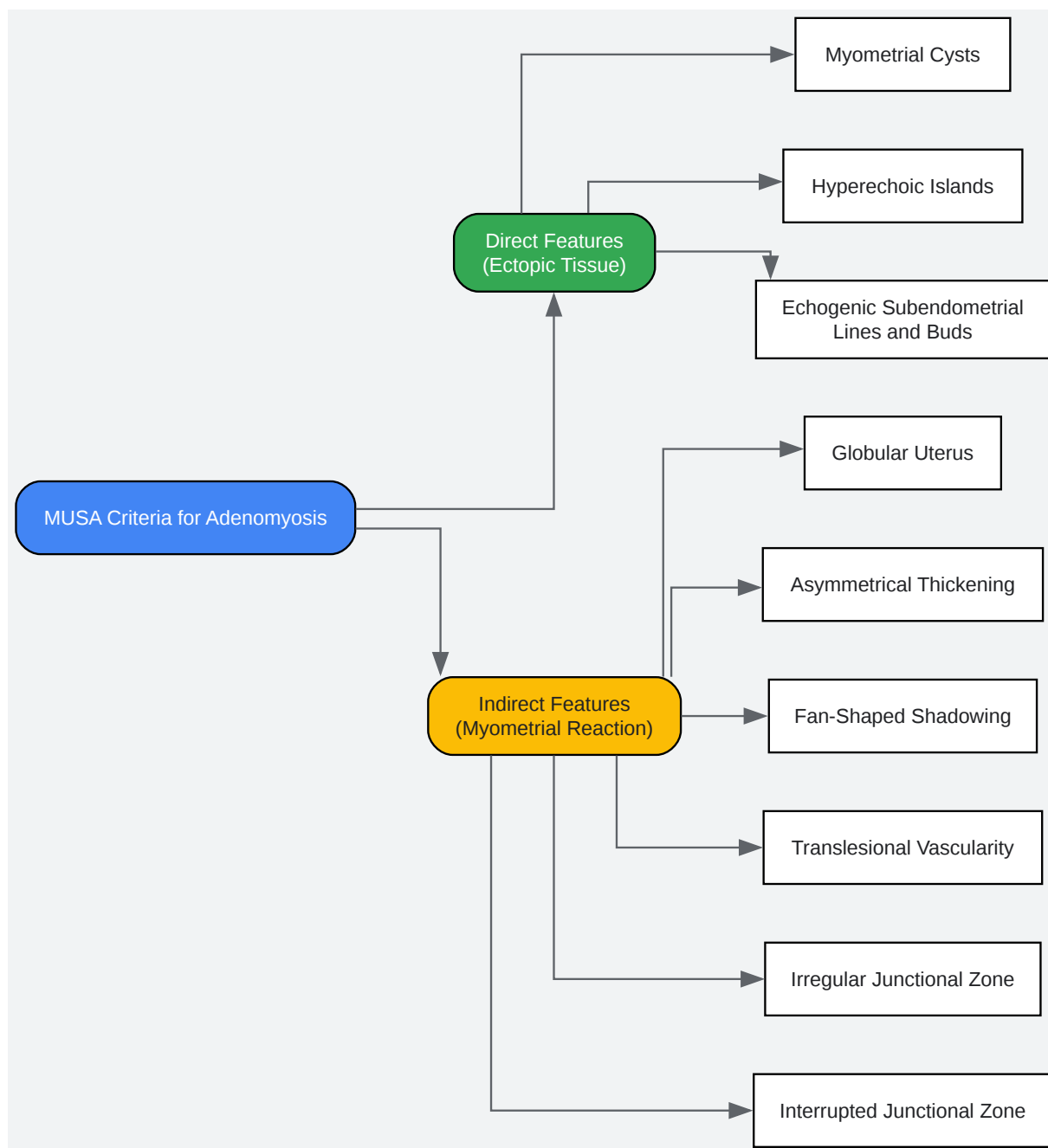
- Subendometrial Echogenic Linear Striations: Bright lines or "streaks" that radiate from the endometrium into the myometrium, sometimes creating a "venetian blind" or "rain shower" shadowing effect.[\[2\]](#)[\[7\]](#)
- Ill-defined Endometrial-Myometrial Junction (Junctional Zone): A poorly demarcated border between the endometrium and the myometrium.[\[3\]](#)[\[8\]](#)
- Fan-Shaped Shadowing: Acoustic shadowing that is not associated with a distinct fibroid.[\[7\]](#)

Q2: What are the MUSA (Morphological Uterus Sonographic Assessment) criteria and how do they improve diagnostic accuracy?

A2: The MUSA group established a consensus to standardize the terminology and diagnostic criteria for adenomyosis on ultrasound.[\[9\]](#)[\[10\]](#) This standardization helps to improve diagnostic reproducibility and accuracy.[\[11\]](#) The criteria are categorized into direct and indirect features: [\[12\]](#)[\[13\]](#)

- Direct Features: These signs indicate the actual presence of ectopic endometrial tissue. A diagnosis of adenomyosis can be made if at least one direct feature is present.[\[13\]](#)
 - Myometrial Cysts
 - Hyperechoic Islands (representing nests of endometrial tissue)
 - Echogenic Subendometrial Lines and Buds
- Indirect Features: These signs reflect the myometrium's reaction to the presence of ectopic endometrial tissue.
 - Globular Uterus
 - Asymmetrical Thickening
 - Fan-Shaped Shadowing
 - Irregular Junctional Zone
 - Interrupted Junctional Zone

- Translesional Vascularity (blood vessels crossing the lesion, seen with color Doppler)[10]
[14]



[Click to download full resolution via product page](#)

MUSA Criteria for Adenomyosis Diagnosis

Q3: How does 3D transvaginal ultrasound improve upon 2D ultrasound for adenomyosis diagnosis?

A3: 3D TVS offers several advantages by providing a coronal view of the uterus, which is not possible with 2D TVS. This view is particularly valuable for assessing the endometrial-myometrial junctional zone (JZ).[5][15] The key benefits of 3D TVS include:

- **Improved JZ Evaluation:** 3D TVS allows for a more detailed assessment and precise measurement of JZ thickness, regularity, and potential disruption.[5][16] An ill-defined JZ is a significant feature of adenomyosis.[16]
- **Enhanced Spatial Understanding:** It provides a better understanding of the location and extent of focal or diffuse adenomyosis.[15]
- **High Diagnostic Accuracy:** Studies have shown that 3D TVS has a high overall accuracy for diagnosing adenomyosis, comparable to MRI.[5][17]

Troubleshooting Guides

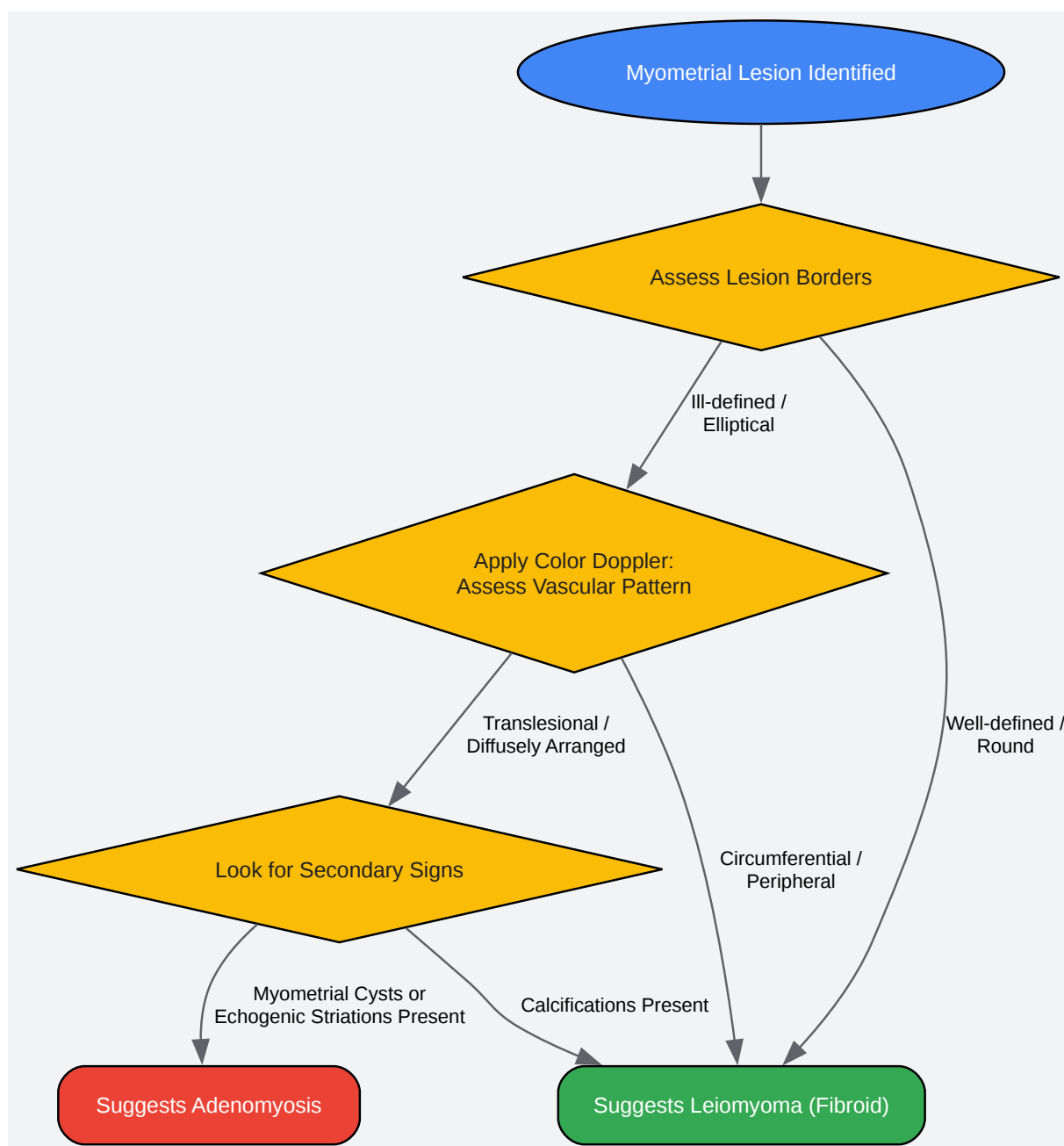
Problem 1: Difficulty differentiating adenomyosis from uterine leiomyomas (fibroids).

Cause: Both adenomyosis and fibroids are common, can coexist, and may present with similar sonographic features, such as uterine enlargement and heterogeneous myometrial texture.[6]

Solution: Focus on key distinguishing features:

- **Borders:** Adenomyosis, particularly focal adenomyosis (adenomyoma), typically has ill-defined borders and is elliptical in shape, blending into the surrounding myometrium. Fibroids are usually well-circumscribed, round masses with a distinct pseudocapsule.[7]
- **Vascularity (with Color Doppler):** Adenomyomas often show diffuse, translesional vascularity, where vessels run through the lesion. Fibroids tend to have circumferential or peripheral flow around the mass.[5][18]
- **Shadowing:** Adenomyosis is associated with streaky, fan-shaped, or "venetian blind" shadowing. Fibroids typically cause more distinct posterior acoustic shadowing.[5]

- Secondary Signs: The presence of myometrial cysts and subendometrial echogenic striations are highly indicative of adenomyosis, whereas fibroids may show calcifications, which are not a feature of adenomyosis.[5]



[Click to download full resolution via product page](#)

Workflow for Differentiating Adenomyosis from Leiomyoma

Problem 2: Poor image quality obscuring key diagnostic features.

Cause: Suboptimal image quality can be due to incorrect machine settings, patient-related factors (e.g., bowel gas), or poor operator technique.

Solution: Implement systematic image optimization techniques:

- Machine Settings:
 - Frequency: Use the highest possible transducer frequency that still allows for adequate penetration to visualize the entire uterus. Higher frequencies improve resolution.[\[19\]](#)
 - Gain: Adjust the overall gain to achieve a balanced image brightness. Excessive gain can introduce noise and obscure subtle texture changes.[\[20\]](#)
 - Focus: Place the focal zone at the depth of the myometrium or the specific region of interest to maximize lateral resolution.[\[20\]](#)
 - Harmonics: Utilize tissue harmonic imaging to reduce artifacts and improve image clarity, especially in challenging cases.[\[19\]](#)
- Operator Technique:
 - Transducer Pressure: Apply gentle but firm pressure to displace overlying bowel gas and bring the uterus closer to the probe.[\[20\]](#)
 - Patient Positioning: A partially filled bladder may be helpful in some transabdominal views to create an acoustic window, though transvaginal is the primary method.[\[19\]](#) For TVS, ensure the patient is comfortable to minimize movement.[\[21\]](#)
 - Dynamic Assessment: Use cine loops (video clips) to better appreciate subtle findings like "venetian blind" shadowing, which may not be obvious on a static image.[\[4\]](#)[\[7\]](#)

Problem 3: High inter-observer variability in interpreting sonographic signs.

Cause: The subjective nature of many ultrasound features (e.g., "heterogeneous," "ill-defined") can lead to inconsistent interpretation between different operators.[\[9\]](#)[\[22\]](#)

Solution: Standardize the examination and reporting process.

- **Adopt MUSA Criteria:** Systematically evaluate and report the presence or absence of all MUSA criteria for each scan.^[9] This provides a structured framework that reduces ambiguity.
- **Quantitative Measurements:** Whenever possible, use objective measurements. For example, measure the anterior and posterior myometrial walls to formally assess for asymmetrical thickening (a difference >5mm is considered asymmetrical).^[9]
- **3D Ultrasound for JZ:** Utilize 3D TVS to evaluate the junctional zone, as it allows for more reproducible assessment compared to the often-subjective evaluation on 2D images.^[16]
- **Training and Peer Review:** Regular training on standardized criteria and peer review of challenging cases can help calibrate interpretation among researchers.^[23]

Experimental Protocols

Protocol: Systematic Transvaginal Ultrasound Evaluation for Adenomyosis

- **Patient Preparation:** The examination is ideally performed with an empty bladder to optimize visualization. Explain the procedure to the patient to ensure comfort and cooperation.^[21]
- **Transducer Selection and Preparation:** Use a high-frequency (5-9 MHz) transvaginal transducer. Cover the transducer with a sterile probe cover and apply lubricating gel.^[8]
- **Initial Uterine Survey (Sagittal View):**
 - Insert the probe into the vagina and obtain a midline sagittal view of the uterus.
 - Assess uterine version (anteverted/retroverted).
 - Measure the length, anteroposterior (AP) diameter, and endometrial thickness.
 - Sweep the probe from one side of the uterus to the other (cornu to cornu) to evaluate the entire myometrium for overall echotexture (homogeneous vs. heterogeneous).^[24]
- **Detailed Myometrial and JZ Evaluation (Sagittal View):**

- Examine the anterior and posterior myometrial walls, measuring their thickness to assess for asymmetry.[9]
- Scrutinize the myometrium for specific MUSA features: myometrial cysts, hyperechoic islands, and fan-shaped shadowing.
- Evaluate the subendometrial region for echogenic linear striations/buds and the clarity of the endometrial-myometrial junction.[2]
- Transverse View Evaluation:
 - Rotate the probe 90 degrees counter-clockwise to obtain a transverse view.
 - Measure the transverse diameter of the uterus.
 - Sweep the probe from the cervix to the fundus, re-evaluating the myometrium for any focal or diffuse abnormalities missed in the sagittal plane.[24] Assess for a globular uterine shape.
- Color Doppler Assessment:
 - Apply color or power Doppler to any identified lesion or area of abnormal echotexture.
 - Assess for the presence and pattern of vascularity (translesional vs. circumferential) to help differentiate adenomyosis from leiomyomas.[16]
- 3D Ultrasound Acquisition (Optional but Recommended):
 - Return to a midline sagittal view of the uterus.
 - Activate the 3D acquisition mode and perform a volume sweep, ensuring the entire uterus is captured.
 - Reconstruct the volume to obtain a coronal view.
 - Analyze the coronal plane to assess the morphology of the endometrial cavity and the integrity and thickness of the junctional zone.[5][15]

- Adnexal and Cul-de-Sac Evaluation:
 - Complete the examination by evaluating both ovaries and the adnexa to rule out coexisting pathologies like endometriosis.
- Documentation:
 - Record all measurements.
 - Systematically document the presence or absence of each of the MUSA criteria.
 - Capture representative static images and cine clips of all findings.

Quantitative Data Summary

Table 1: Diagnostic Accuracy of 2D TVS Features for Adenomyosis

2D TVS Feature	Pooled Sensitivity (%)	Pooled Specificity (%)	Source(s)
All Combined Features	83.8	63.9	[25] [26]
Heterogeneous Myometrium	86.0	>50	[25] [27]
Globular Uterus	—	78.1	[25] [26]
Subendometrial Linear Striations	—	95.5	[2]
Myometrial Cysts	—	86-98	[13]
Ill-defined JZ	—	—	[3]

Table 2: Comparison of Imaging Modalities for Adenomyosis Diagnosis

Imaging Modality	Pooled Sensitivity (%)	Pooled Specificity (%)	Key Advantages	Source(s)
2D TVS	83.8	63.9	Widely available, cost-effective, first-line tool.	[25] [26]
3D TVS	88.9	56.0	Superior evaluation of the junctional zone via coronal view.	[5] [25] [26]
MRI	70-100	86-93	High reliability, excellent for complex cases with co-pathologies.	[28]

Need Custom Synthesis?

BenchChem offers custom synthesis for rare earth carbides and specific isotopic labeling.

Email: info@benchchem.com or [Request Quote Online](#).

References

- 1. dsjuog.com [dsjuog.com]
- 2. Transvaginal sonography in the diagnosis of adenomyosis: which findings are most accurate? - PubMed [pubmed.ncbi.nlm.nih.gov]
- 3. mascothealthcare.com [mascothealthcare.com]
- 4. bmus.org [bmus.org]
- 5. volusonclub.net [volusonclub.net]
- 6. sydneyfibroidclinic.com.au [sydneyfibroidclinic.com.au]
- 7. m.youtube.com [m.youtube.com]
- 8. auntminnie.com [auntminnie.com]

- 9. mdpi.com [mdpi.com]
- 10. Morphological Uterus Sonographic Assessment Criteria for Adenomyosis Diagnostic: A Case Report | Open Access Macedonian Journal of Medical Sciences [oamjms.eu]
- 11. oamjms.eu [oamjms.eu]
- 12. Frontiers | Prediction of adenomyosis according to revised definitions of morphological uterus sonographic assessment features [frontiersin.org]
- 13. mdpi.com [mdpi.com]
- 14. Adenomyosis: An Updated Review on Diagnosis and Classification - PMC [pmc.ncbi.nlm.nih.gov]
- 15. Three-dimensional ultrasound manifestations of adenomyosis - PMC [pmc.ncbi.nlm.nih.gov]
- 16. emedicine.medscape.com [emedicine.medscape.com]
- 17. ejhm.journals.ekb.eg [ejhm.journals.ekb.eg]
- 18. volusonclub.net [volusonclub.net]
- 19. vomark.com [vomark.com]
- 20. Sona [sonagram.com]
- 21. radmagazine.com [radmagazine.com]
- 22. Inter-Rater Agreement for Diagnosing Adenomyosis Using Magnetic Resonance Imaging and Transvaginal Ultrasonography - PMC [pmc.ncbi.nlm.nih.gov]
- 23. Transvaginal ultrasound for diagnosis of adenomyosis: a review - PubMed [pubmed.ncbi.nlm.nih.gov]
- 24. Gynecology/Pelvic Ultrasound Made Easy: Step-By-Step Guide - POCUS 101 [pocus101.com]
- 25. Transvaginal Ultrasound for the Diagnosis of Adenomyosis: Systematic Review and Meta-Analysis - PubMed [pubmed.ncbi.nlm.nih.gov]
- 26. researchgate.net [researchgate.net]
- 27. Accuracy of findings in the diagnosis of uterine adenomyosis on ultrasound - PubMed [pubmed.ncbi.nlm.nih.gov]
- 28. Adenomyosis Workup: Approach Considerations, Laboratory Studies, Imaging Studies [emedicine.medscape.com]
- To cite this document: BenchChem. [Technical Support Center: Transvaginal Ultrasound for Adenomyosis Diagnosis]. BenchChem, [2025]. [Online PDF]. Available at:

[<https://www.benchchem.com/product/b1674034#improving-transvaginal-ultrasound-accuracy-for-adenomyosis-diagnosis>]

Disclaimer & Data Validity:

The information provided in this document is for Research Use Only (RUO) and is strictly not intended for diagnostic or therapeutic procedures. While BenchChem strives to provide accurate protocols, we make no warranties, express or implied, regarding the fitness of this product for every specific experimental setup.

Technical Support: The protocols provided are for reference purposes. Unsure if this reagent suits your experiment? [[Contact our Ph.D. Support Team for a compatibility check](#)]

Need Industrial/Bulk Grade? [Request Custom Synthesis Quote](#)

BenchChem

Our mission is to be the trusted global source of essential and advanced chemicals, empowering scientists and researchers to drive progress in science and industry.

Contact

Address: 3281 E Guasti Rd
Ontario, CA 91761, United States
Phone: (601) 213-4426
Email: info@benchchem.com