

Technical Support Center: Transvaginal Ultrasound Imaging in Obese Patients

Author: BenchChem Technical Support Team. **Date:** December 2025

Compound of Interest

Compound Name: FR 76830

Cat. No.: B1674034

[Get Quote](#)

This technical support center provides troubleshooting guides and frequently asked questions (FAQs) to address the challenges researchers, scientists, and drug development professionals may encounter during transvaginal ultrasound imaging in obese patients.

Frequently Asked Questions (FAQs)

Q1: Why is transvaginal ultrasound imaging challenging in obese patients?

A1: Increased body mass index (BMI) presents several challenges to obtaining high-quality transvaginal ultrasound images. The primary reasons include:

- **Increased Depth of Insonation:** A thicker layer of subcutaneous and visceral adipose tissue increases the distance the ultrasound waves must travel to reach the pelvic organs. This leads to attenuation (weakening) of the ultrasound beam.[\[1\]](#)[\[2\]](#)
- **Absorption and Scattering of Ultrasound Waves:** Adipose tissue absorbs and scatters the ultrasound waves, resulting in a weaker signal returning to the transducer and greater background noise, which degrades image quality.[\[2\]](#)[\[3\]](#)[\[4\]](#)
- **Image Artifacts:** The increased tissue depth and altered sound speed in adipose tissue can lead to various image artifacts, such as backscatter and reverberation, further compromising image clarity.[\[3\]](#)[\[5\]](#)

- Anatomical Challenges: In patients with class III obesity (BMI ≥ 40 kg/m²), accessing the ovaries and other pelvic structures can be technically difficult, leading to incomplete examinations.[\[6\]](#)[\[7\]](#)

Q2: What is the impact of obesity on the diagnostic accuracy of transvaginal ultrasound?

A2: Obesity can significantly decrease the diagnostic accuracy of transvaginal ultrasound. For instance, in gynecological assessments, the diagnostic accuracy for identifying endometrial pathologies may be reduced in obese women.[\[8\]](#) During pregnancy, maternal obesity is associated with a decreased detection rate of fetal anomalies.[\[1\]](#) One study noted a 20% decrease in the detection rate of fetal anomalies in obese patients compared to those with a normal BMI.[\[1\]](#)

Q3: Are there specific procedural challenges during transvaginal ultrasound-guided interventions in obese patients?

A3: Yes, procedures such as transvaginal oocyte retrieval for in-vitro fertilization (IVF) can be more challenging in obese patients. Studies have shown a higher rate of difficult access to the ovaries and a greater likelihood of incomplete follicle aspiration in women with a high BMI.[\[6\]](#)[\[7\]](#) This can also lead to longer procedure times.[\[6\]](#)

Troubleshooting Guide

This guide provides solutions to common problems encountered during transvaginal ultrasound imaging in obese patients.

Problem	Possible Cause	Recommended Solution(s)
Poor Image Quality / Low Resolution	Increased signal attenuation due to adipose tissue.[2][4]	Optimize Transducer Selection and Frequency: Use a lower frequency transducer (e.g., 1-2 MHz) to improve penetration, although this may come at the cost of some resolution.[2][3] Utilize Advanced Imaging Modes: Employ tissue harmonic imaging, compound imaging, and speckle reduction filters to enhance image contrast and clarity.[3]
Inability to Visualize Pelvic Structures	Deeply located organs due to body habitus.	Patient Repositioning: Place the patient in a lateral decubitus or Trendelenburg position to displace the panniculus and bring the pelvic organs closer to the transducer.[3] Apply Gentle Transducer Pressure: Carefully apply pressure with the transducer to reduce the distance to the organ of interest.[9]
Image Artifacts (e.g., shadowing, reverberation)	Sound wave interaction with adipose tissue and bowel gas.	Adjust Machine Settings: Optimize gain, time-gain compensation (TGC), and focal zones to minimize artifacts. Patient Preparation: Ensure the patient has an empty bladder to reduce interference, unless a full bladder is needed as an acoustic window for a

		concomitant transabdominal scan. [10]
Difficult Access to Ovaries/Adnexa	Anatomical displacement by adipose tissue.	Consider Alternative Approaches: In some cases, a transabdominal approach with a low-frequency probe may be necessary to locate the ovaries before proceeding with the transvaginal scan. Utilize Transvaginal Probe Maneuverability: The probe can be placed in the vaginal fornices to achieve different imaging planes and better access to the adnexa. [11]

Quantitative Data Summary

The following tables summarize quantitative data on the impact of obesity on transvaginal ultrasound procedures.

Table 1: Impact of BMI on Transvaginal Oocyte Pickup (OPU) Outcomes

Outcome	BMI <25 kg/m ²	BMI ≥40 kg/m ²	Adjusted Odds Ratio (aOR) [95% CI]
Difficult Access Rate	5.2%	28.9%	7.57 [4.66–12.29]
Incomplete Retrieval Rate	1.3%	18.2%	16.94 [8.24–34.84]
Mean Procedure Duration	13.3 minutes	15.7 minutes	-

Source: Adapted from a retrospective cohort study on OPU outcomes.[\[6\]](#)

Table 2: Detection Rates of Fetal Anomalies by Maternal BMI

Maternal BMI Category	Standard Ultrasonography	Targeted Ultrasonography
Normal	66%	97%
Overweight	49%	91%
Class 1 Obesity	48%	75%
Class 2 Obesity	45%	88%
Class 3 Obesity	22%	72%

Source: Adapted from a retrospective cohort study on fetal anomaly detection.[\[1\]](#)

Experimental Protocols

Protocol 1: Optimized Transvaginal Ultrasound Imaging Protocol for Obese Patients

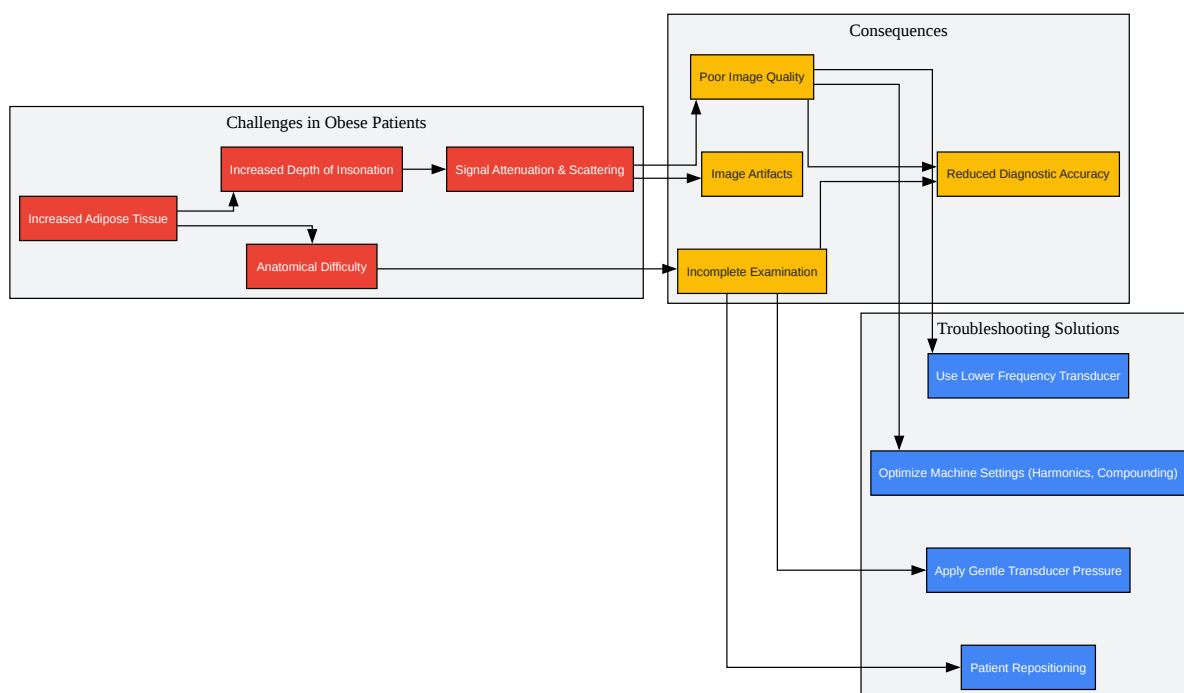
Objective: To obtain diagnostic-quality images of the female pelvic organs in patients with a high BMI.

Methodology:

- Patient Preparation:
 - Explain the procedure to the patient and obtain informed consent.
 - Instruct the patient to empty her bladder immediately before the examination.[\[10\]](#)
 - Position the patient in the dorsal lithotomy position.[\[10\]](#)
- Ultrasound Machine and Transducer Setup:
 - Select a transvaginal transducer. If significant signal attenuation is anticipated, have a lower frequency transabdominal probe (1-2 MHz) available.[\[2\]](#)
 - Prepare the transvaginal probe with a sterile cover and lubricating gel.[\[11\]](#)

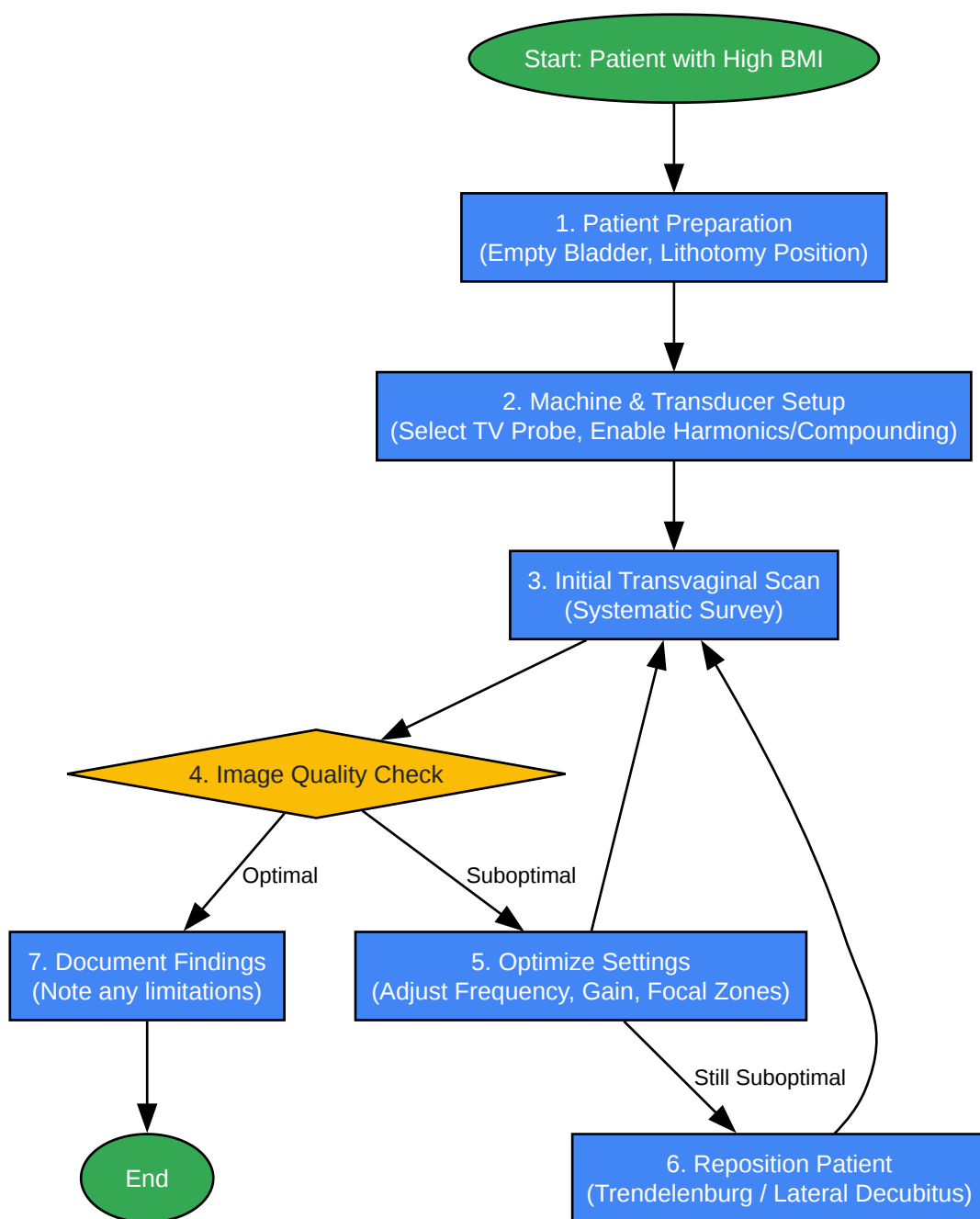
- Optimize initial machine settings:
 - Select the appropriate preset for gynecological or obstetric imaging.
 - Activate tissue harmonic imaging.[\[1\]](#)
 - Ensure compound imaging and speckle reduction filters are enabled.[\[3\]](#)
- Image Acquisition and Optimization:
 - Gently insert the transvaginal transducer.[\[10\]](#)
 - Begin with a systematic survey of the pelvis in both sagittal and transverse planes.[\[11\]](#)
 - If image quality is suboptimal:
 - Adjust Frequency: If available on the transducer, select a lower imaging frequency to improve penetration.
 - Optimize Gain and TGC: Carefully adjust the overall gain and TGC settings to create a uniform image brightness.
 - Adjust Focal Zones: Position the focal zone(s) at or just below the depth of the structure of interest.
 - Patient Repositioning: If visualization is still limited, consider placing the patient in a Trendelenburg or lateral decubitus position.[\[3\]](#)
 - Document all standard anatomical views as per institutional protocol. If any structure is not adequately visualized, this should be clearly documented in the report.[\[12\]](#)

Visualizations



[Click to download full resolution via product page](#)

Caption: Logical relationship between challenges, consequences, and solutions.



[Click to download full resolution via product page](#)

Need Custom Synthesis?

BenchChem offers custom synthesis for rare earth carbides and specific isotopic labeling.

Email: info@benchchem.com or [Request Quote Online](#).

References

- 1. Obstetric Ultrasound Imaging in the Patient with Obesity | Article | GLOWM [glowm.com]
- 2. Technical challenges of imaging & image-guided interventions in obese patients - PMC [pmc.ncbi.nlm.nih.gov]
- 3. contemporaryobgyn.net [contemporaryobgyn.net]
- 4. Could being overweight affect my ultrasound scans? | BabyCentre [babycentre.co.uk]
- 5. Obstetric Ultrasound Imaging and the Obese Patient | Radiology Key [radiologykey.com]
- 6. Impact of class III obesity on outcomes and complications of transvaginal ultrasound-guided oocyte pickup - PMC [pmc.ncbi.nlm.nih.gov]
- 7. Impact of class III obesity on outcomes and complications of transvaginal ultrasound-guided oocyte pickup - PubMed [pubmed.ncbi.nlm.nih.gov]
- 8. Accuracy of transvaginal ultrasonography in diabetic or obese women with postmenopausal bleeding - PubMed [pubmed.ncbi.nlm.nih.gov]
- 9. researchgate.net [researchgate.net]
- 10. Gynecology/Pelvic Ultrasound Made Easy: Step-By-Step Guide - POCUS 101 [pocus101.com]
- 11. Sonography Transvaginal Assessment, Protocols, and Interpretation - StatPearls - NCBI Bookshelf [ncbi.nlm.nih.gov]
- 12. Safe Practice for Scanning Women with a High BMI (468) | Right Decisions [rightdecisions.scot.nhs.uk]
- To cite this document: BenchChem. [Technical Support Center: Transvaginal Ultrasound Imaging in Obese Patients]. BenchChem, [2025]. [Online PDF]. Available at: [https://www.benchchem.com/product/b1674034#challenges-in-transvaginal-ultrasound-imaging-in-obese-patients]

Disclaimer & Data Validity:

The information provided in this document is for Research Use Only (RUO) and is strictly not intended for diagnostic or therapeutic procedures. While BenchChem strives to provide accurate protocols, we make no warranties, express or implied, regarding the fitness of this product for every specific experimental setup.

Technical Support: The protocols provided are for reference purposes. Unsure if this reagent suits your experiment? [[Contact our Ph.D. Support Team for a compatibility check](#)]

Need Industrial/Bulk Grade? [Request Custom Synthesis Quote](#)

BenchChem

Our mission is to be the trusted global source of essential and advanced chemicals, empowering scientists and researchers to drive progress in science and industry.

Contact

Address: 3281 E Guasti Rd
Ontario, CA 91761, United States
Phone: (601) 213-4426
Email: info@benchchem.com