

Technical Support Center: TI-201 Myocardial Perfusion Imaging in Obese Patients

Author: BenchChem Technical Support Team. **Date:** December 2025

Compound of Interest

Compound Name: *Thallous chloride TL-201*

Cat. No.: *B1258455*

[Get Quote](#)

This technical support center provides troubleshooting guidance and frequently asked questions (FAQs) for researchers, scientists, and drug development professionals encountering challenges with Thallium-201 (TI-201) imaging in obese patients. The information provided aims to help resolve common issues and improve the quality of experimental data.

Frequently Asked Questions (FAQs)

Q1: Why are my TI-201 images in obese subjects of poor quality?

Poor image quality in obese patients is primarily due to several factors:

- **Soft-Tissue Attenuation:** Increased adipose tissue between the heart and the gamma camera absorbs and blocks the low-energy photons emitted by TI-201, leading to a reduced signal-to-noise ratio and insufficient count statistics.[\[1\]](#)[\[2\]](#)
- **Photon Scatter:** The deeper the heart is within the patient's body, the greater the likelihood of photons being scattered before reaching the detector, which can degrade image resolution.[\[1\]](#)[\[3\]](#)
- **Increased Distance:** The heart is physically farther from the camera detectors in obese individuals, which reduces the number of detected photons.[\[1\]](#)
- **Patient Motion:** Longer acquisition times, often necessary to acquire sufficient counts, increase the probability of patient movement, which can introduce motion artifacts.[\[4\]](#)

- Physical Limitations of Equipment: The patient's body habitus may exceed the weight limit of the imaging table or the bore size of the scanner, making proper positioning difficult or impossible.[\[1\]](#)[\[5\]](#)

Q2: What are the common artifacts I should look for in TI-201 images of obese patients?

The most common artifacts are attenuation-related and can mimic true perfusion defects:

- Diaphragmatic Attenuation: The diaphragm can cause an apparent reduction in tracer uptake in the inferior wall of the myocardium.[\[3\]](#)[\[4\]](#)
- Breast Attenuation: In female subjects, breast tissue can lead to artifacts in the anterior and anteroseptal walls.[\[1\]](#)[\[4\]](#)
- Lateral Wall Attenuation: In extremely obese patients, increased soft tissue in the lateral chest wall can cause attenuation artifacts in the lateral wall of the myocardium.[\[1\]](#)

Q3: How can I improve the quality of my TI-201 images in this patient population?

Several strategies can be employed to mitigate the challenges of TI-201 imaging in obese patients:

- Optimize Radiopharmaceutical Dose: Adjust the administered activity based on the patient's weight. A common approach is to use a weight-based formula, such as 1.48 MBq (0.04 mCi)/kg for TI-201.[\[1\]](#)[\[2\]](#)
- Increase Acquisition Time: To compensate for the lower count rate due to attenuation, prolonging the image acquisition time is often necessary to obtain adequate count statistics.[\[1\]](#)[\[2\]](#)
- Utilize Attenuation Correction: CT-based attenuation correction has been shown to significantly improve the accuracy of SPECT imaging in obese patients by creating a map of tissue densities to correct for photon attenuation.[\[6\]](#)[\[7\]](#)
- Implement Prone Imaging: Acquiring images with the patient in both the supine and prone positions can help differentiate true perfusion defects from attenuation artifacts, particularly from the diaphragm and breast tissue.[\[1\]](#)[\[8\]](#)

- Consider Advanced Imaging Systems: Newer gamma cameras, such as those with cadmium-zinc-telluride (CZT) detectors, offer higher sensitivity and may provide better image quality, even with lower injected doses.[\[9\]](#)[\[10\]](#)

Troubleshooting Guides

Issue: Low Myocardial Counts and High Image Noise

Potential Cause	Troubleshooting Step
Insufficient injected dose for patient's body mass.	Calculate and administer a weight-based dose of Tl-201. [1] [2]
Significant soft-tissue attenuation.	Increase the image acquisition time per projection. [1] [2]
Suboptimal patient positioning.	Ensure the patient is positioned as close to the detectors as possible.

Issue: Perfusion Defects in the Inferior or Anterior Wall

Potential Cause	Troubleshooting Step
Attenuation artifact from the diaphragm or breast tissue.	Perform an additional acquisition with the patient in the prone position. [1] [8] If available, apply attenuation correction to the reconstructed images. [6] [7]
Patient motion during the scan.	Review the raw data for any signs of patient movement. If motion is detected, consider repeating the acquisition.

Quantitative Data Summary

The following table summarizes key quantitative parameters for Tl-201 imaging in obese patients, compiled from various studies.

Parameter	Recommended Value/Range	Notes
TI-201 Administered Activity	1.48 MBq/kg (0.04 mCi/kg)	Dose should be adjusted upwards for heavier patients. [1] [2]
Acquisition Time (PET)	5 minutes per bed position	For LSO PET/CT in patients ≥ 91 kg, this duration was found to be optimal for lesion detection. [11] [12]
Transmission Scan Time (for AC)	5 seconds per view	A study found that prolonged transmission scanning (10s vs 5s) was not necessary for obese patients. [6]

Experimental Protocols

Protocol 1: TI-201 Stress/Redistribution Imaging with Prone Acquisition

This protocol is designed to differentiate ischemia from attenuation artifacts.

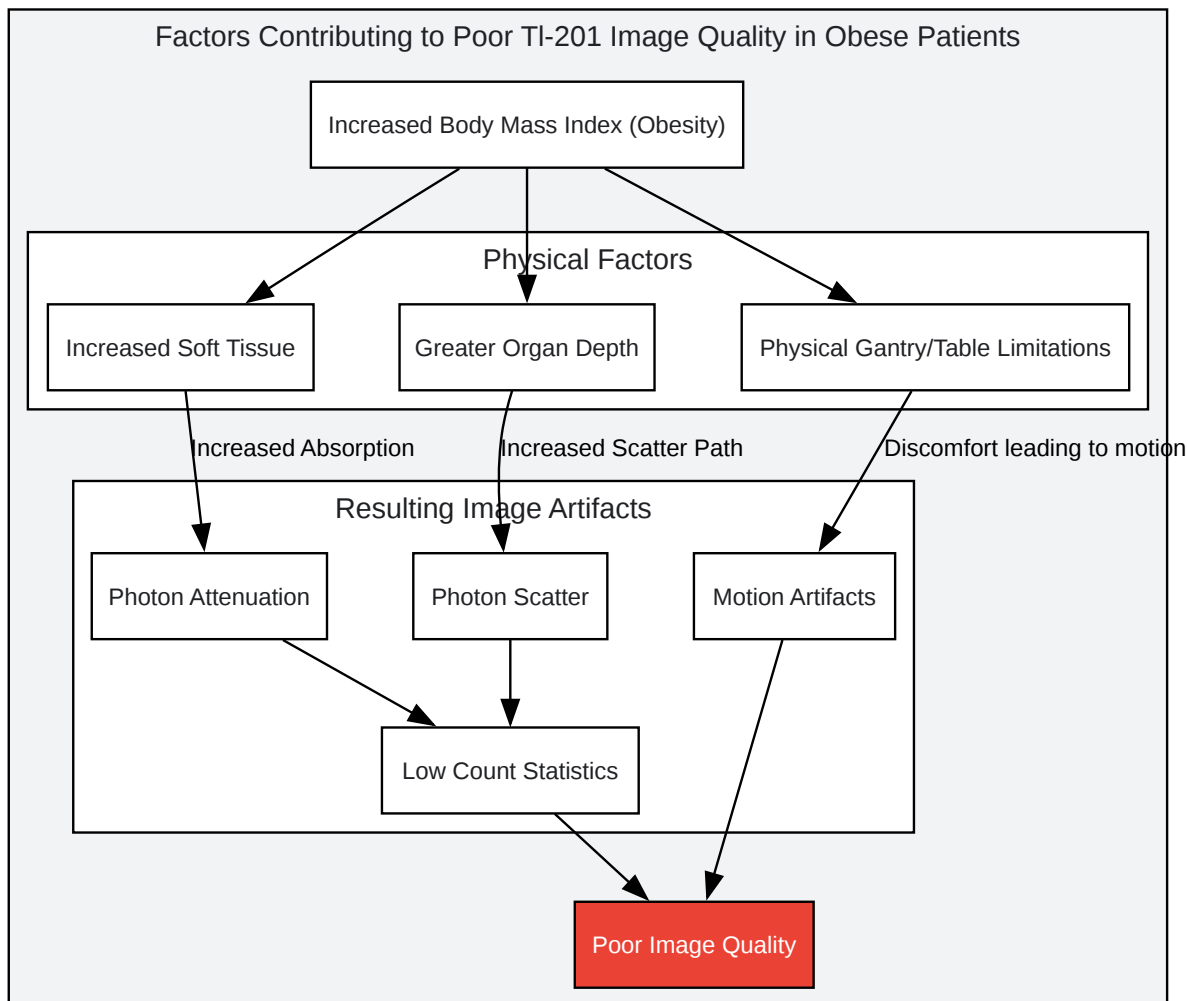
- Patient Preparation: The subject should fast for at least 4 hours prior to the study.
- Stress Induction: Perform exercise or pharmacological stress according to a standard protocol.
- TI-201 Injection: At peak stress, inject a weight-based dose of TI-201 (e.g., 1.48 MBq/kg).
- Supine Stress Imaging: Begin SPECT acquisition 10-15 minutes post-injection with the patient in the supine position.
- Prone Stress Imaging: Immediately following the supine scan, acquire a second set of images with the patient in the prone position.
- Redistribution Imaging: Acquire a final set of images 3-4 hours after the TI-201 injection to assess for redistribution.

Protocol 2: Tl-201 Imaging with CT-Based Attenuation Correction

This protocol improves image accuracy by correcting for photon attenuation.

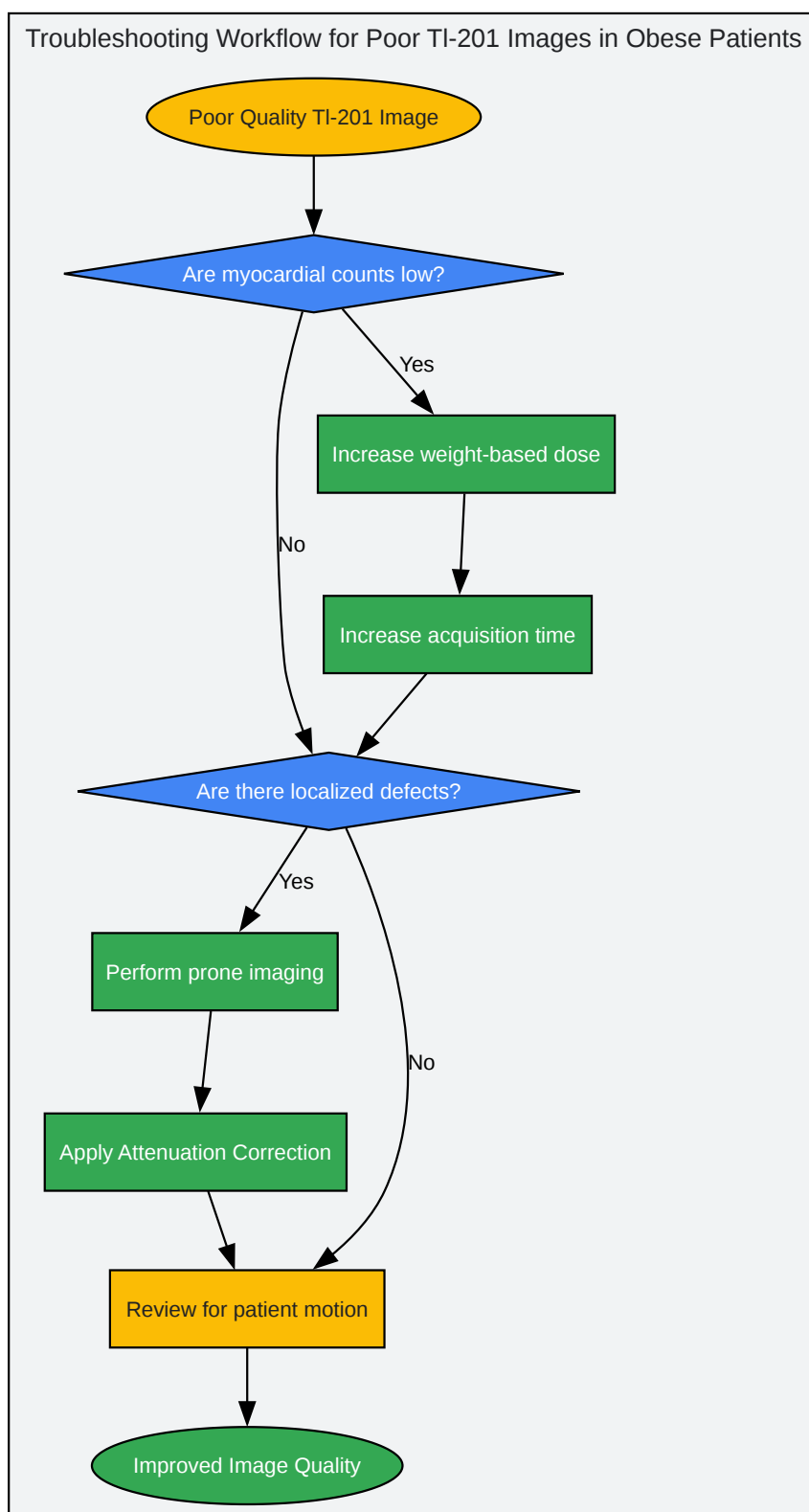
- Patient Preparation: The subject should fast for at least 4 hours.
- Stress and Tl-201 Injection: Induce stress and inject a weight-based dose of Tl-201 as per standard procedure.
- CT Scan: Perform a low-dose CT scan of the chest to generate an attenuation map.
- SPECT Acquisition: Immediately following the CT scan, perform the SPECT emission scan.
- Image Reconstruction: Reconstruct the SPECT data using an iterative algorithm that incorporates the CT-based attenuation correction map.

Visualizations



[Click to download full resolution via product page](#)

Caption: Factors leading to poor TI-201 image quality in obese patients.



[Click to download full resolution via product page](#)

Caption: A logical workflow for troubleshooting poor TI-201 images.

Need Custom Synthesis?

BenchChem offers custom synthesis for rare earth carbides and specific isotopic labeling.

Email: info@benchchem.com or [Request Quote Online](#).

References

- 1. tech.snmjournals.org [tech.snmjournals.org]
- 2. tech.snmjournals.org [tech.snmjournals.org]
- 3. Effect of patient obesity on the accuracy of thallium-201 myocardial perfusion imaging - PubMed [pubmed.ncbi.nlm.nih.gov]
- 4. Diagnostic accuracy of thallium-201 myocardial perfusion imaging - PubMed [pubmed.ncbi.nlm.nih.gov]
- 5. How is patient obesity affecting cardiac imaging? [digirad.com]
- 6. Transmission scanning for attenuation correction of myocardial 201TI images in obese patients - PubMed [pubmed.ncbi.nlm.nih.gov]
- 7. CT attenuation correction improves quantitative risk prediction by cardiac SPECT in obese patients - PubMed [pubmed.ncbi.nlm.nih.gov]
- 8. SPECT attenuation artifacts in normal and overweight persons: insights from a retrospective comparison of Rb-82 positron emission tomography and TI-201 SPECT myocardial perfusion imaging - PubMed [pubmed.ncbi.nlm.nih.gov]
- 9. researchgate.net [researchgate.net]
- 10. Feasibility of ultra low-dose thallium stress-redistribution protocol including prone imaging in obese patients using CZT camera - PubMed [pubmed.ncbi.nlm.nih.gov]
- 11. Optimizing imaging protocols for overweight and obese patients: a lutetium orthosilicate PET/CT study - PubMed [pubmed.ncbi.nlm.nih.gov]
- 12. researchgate.net [researchgate.net]
- To cite this document: BenchChem. [Technical Support Center: TI-201 Myocardial Perfusion Imaging in Obese Patients]. BenchChem, [2025]. [Online PDF]. Available at: [https://www.benchchem.com/product/b1258455#troubleshooting-poor-quality-tl-201-images-in-obese-patients]

Disclaimer & Data Validity:

The information provided in this document is for Research Use Only (RUO) and is strictly not intended for diagnostic or therapeutic procedures. While BenchChem strives to provide accurate protocols, we make no warranties, express or implied, regarding the fitness of this product for every specific experimental setup.

Technical Support: The protocols provided are for reference purposes. Unsure if this reagent suits your experiment? [[Contact our Ph.D. Support Team for a compatibility check](#)]

Need Industrial/Bulk Grade? [Request Custom Synthesis Quote](#)

BenchChem

Our mission is to be the trusted global source of essential and advanced chemicals, empowering scientists and researchers to drive progress in science and industry.

Contact

Address: 3281 E Guasti Rd

Ontario, CA 91761, United States

Phone: (601) 213-4426

Email: info@benchchem.com