

# Technical Support Center: Sestamibi Scan Accuracy and Patient Preparation

**Author:** BenchChem Technical Support Team. **Date:** December 2025

## Compound of Interest

Compound Name: *TECHNETIUM SESTAMIBI*

Cat. No.: *B1142544*

[Get Quote](#)

This guide provides troubleshooting assistance and frequently asked questions for researchers, scientists, and drug development professionals on the critical impact of patient preparation on the accuracy of Technetium-99m (99mTc) Sestamibi scans.

## Frequently Asked Questions (FAQs)

Q1: Why is patient preparation so crucial for Sestamibi scan accuracy?

A1: Patient preparation is critical because physiological conditions can significantly interfere with the biodistribution and clearance of 99mTc-Sestamibi, potentially leading to inaccurate results. For myocardial perfusion imaging (MPI), proper preparation ensures maximal dilation of coronary arteries during stress testing and minimizes non-cardiac tracer uptake. For parathyroid imaging, it helps in differentiating parathyroid adenomas from thyroid tissue.

Q2: What are the standard fasting requirements for a Sestamibi scan?

A2: For myocardial perfusion imaging, patients should typically fast for at least 3 to 4 hours before the scan.<sup>[1][2][3]</sup> This helps to reduce visceral blood flow and subsequent hepatobiliary uptake of the Sestamibi tracer, which can obscure the view of the heart's inferior wall. For parathyroid scintigraphy, special preparation is often not necessary, though protocols can vary between institutions.<sup>[4]</sup>

Q3: What foods, drinks, and medications must be avoided before a myocardial perfusion scan?

A3: Patients should avoid caffeine-containing products (e.g., coffee, tea, soft drinks, chocolate) for at least 12-24 hours before pharmacologic stress imaging with agents like adenosine or dipyridamole, as caffeine can interfere with their hyperemic effects.[1][5][6] Certain cardiac medications may also need to be withheld to allow for an adequate stress response; this should be done in consultation with the referring physician.[1]

Q4: What is the purpose of administering a fatty meal during some Sestamibi scan protocols?

A4: A fatty meal stimulates the release of cholecystokinin, which promotes gallbladder contraction and the excretion of Sestamibi from the liver and gallbladder into the intestines.[7][8][9] This action clears the tracer from the upper abdomen, reducing background activity and significantly improving the image quality of the heart's inferior wall.

Q5: How does patient motion affect scan accuracy?

A5: Patient motion during image acquisition can cause blurring and artifacts, making the interpretation of the scan difficult and potentially leading to misdiagnosis.[4][10] It is crucial that the patient remains as still as possible during the imaging process. This is particularly important for subtraction techniques used in parathyroid imaging, where images taken at different times must be perfectly aligned.[10]

## Troubleshooting Guide

Issue 1: High hepatobiliary (liver and gallbladder) uptake is obscuring the inferior myocardial wall.

- Question: My scan shows intense background activity from the liver, making it difficult to assess the inferior wall of the heart. What can be done?
- Answer: This is a common issue as the liver is the primary route of Sestamibi clearance.[11]
  - Immediate Action: Try delaying the imaging. For rest studies, imaging can be performed 45-60 minutes post-injection to allow for more clearance.[1] For stress studies, the window is typically 15-30 minutes post-injection.[1]
  - Intervention: Administer a fatty meal (e.g., milk, chocolate) or an alternative like diluted lemon juice after the tracer injection but before the scan.[12] This promotes gallbladder

contraction and clears the tracer from the hepatobiliary system.

- Pharmacologic Option: Studies have investigated agents like ursodeoxycholic acid (UDCA) to enhance hepatic clearance, with some showing it can provide better images sooner.[\[13\]](#) However, a single dose may not always be sufficient.[\[14\]](#)
- Acquisition Adjustment: Imaging the patient in the prone (face down) position can sometimes help by separating the heart from the underlying liver and gut activity.[\[1\]](#)

Issue 2: The scan quality is poor, and the myocardium-to-background ratio is low.

- Question: The resulting images lack clear definition between the heart and surrounding tissues. What went wrong?
- Answer: A low myocardium-to-background ratio can result from several factors related to patient preparation.
  - Verify Fasting: Confirm that the patient adhered to the required fasting period (at least 3-4 hours for MPI).[\[1\]](#)[\[2\]](#) A recent meal can increase splanchnic blood flow, leading to higher gut and liver uptake of the tracer.
  - Review Medications/Diet: Ensure the patient avoided caffeine and other interfering substances as per the protocol.[\[1\]](#)[\[5\]](#)
  - Check for Tracer Infiltration: If the tracer was not injected properly into the vein (extravasation), its delivery to the heart will be suboptimal. This may require repeating the injection and scan.[\[15\]](#)

Issue 3: A suspected parathyroid adenoma is not visible on the scan (False Negative).

- Question: The patient has clinical signs of hyperparathyroidism, but the Sestamibi scan is negative. Is the scan inaccurate?
- Answer: Sestamibi scans for parathyroid adenomas are not always positive, and a negative scan does not rule out disease.[\[16\]](#)[\[17\]](#)
  - Gland Characteristics: The scan's sensitivity can be affected by the size of the adenoma and its cellular composition (oxyphil cells show high uptake, while chief cells may not).[\[18\]](#)

- PTH Levels: Scan sensitivity may be lower in patients with lower levels of parathyroid hormone (PTH).[19]
- Imaging Technique: The accuracy depends heavily on the imaging protocol, including the use of early and delayed imaging (lesions are often best seen at 2 hours post-injection) and SPECT/CT for better 3D localization.[20][21] Dual-isotope techniques with iodine subtraction can also improve sensitivity.[22]

## Quantitative Data Summary

The following tables summarize the impact of various patient preparation factors on Sestamibi scan outcomes, based on findings from clinical guidelines and research studies.

Table 1: Impact of Patient Preparation Factors on Myocardial Perfusion Imaging (MPI)  
Accuracy

Factor	Recommended Preparation	Impact of Non-Compliance on Scan Accuracy
Fasting	Minimum 3-4 hours before injection. <a href="#">[1]</a> <a href="#">[2]</a>	Increased hepatobiliary and gut activity, potentially obscuring the inferior myocardial wall and leading to artifacts.
Caffeine	Avoid for at least 12-24 hours before pharmacologic stress. <a href="#">[1]</a> <a href="#">[5]</a>	Attenuates the effect of vasodilator stress agents (adenosine, dipyridamole), leading to a risk of a false-negative result (underestimation of ischemia).
Medications	Withhold specific cardiac drugs (e.g., beta-blockers, nitrates) as advised by a physician. <a href="#">[1]</a>	Can mask the signs of ischemia during a stress test, potentially leading to a false-negative result.
Patient Motion	Patient must remain still during acquisition. <a href="#">[4]</a> <a href="#">[10]</a>	Causes motion artifacts, image blurring, and potential misregistration of attenuation correction maps, reducing diagnostic certainty.

Table 2: Efficacy of Interventions to Reduce Hepatobiliary Clearance

Intervention	Protocol	Observed Effect on Image Quality
Fatty Meal	Administered after tracer injection and before imaging.	Stimulates gallbladder contraction, effectively reducing liver and gallbladder activity and improving visualization of the inferior wall. [8][23]
Diluted Lemon Juice	Administered after tracer injection.	Shown to be a viable alternative to fatty meals for decreasing extra-cardiac activity and increasing the heart-to-liver signal ratio.[12]
Ursodeoxycholic Acid (UDCA)	Administered before tracer injection.	Randomized trials show that UDCA can lead to a significant decrease in liver counts and an improved myocardium-to-liver ratio, resulting in better images sooner.[13]
Delayed Imaging	Increasing the time between injection and scan (e.g., from 30 to 60 minutes).	Allows for natural clearance of the tracer from the liver and gut, improving the target-to-background ratio.[1]

## Experimental Protocols

### Protocol 1: Standard Patient Preparation for <sup>99m</sup>Tc-Sestamibi Myocardial Perfusion Imaging (Stress/Rest)

- Patient Screening & Scheduling:
  - Confirm no contraindications to stress testing.
  - Provide the patient with detailed preparation instructions.

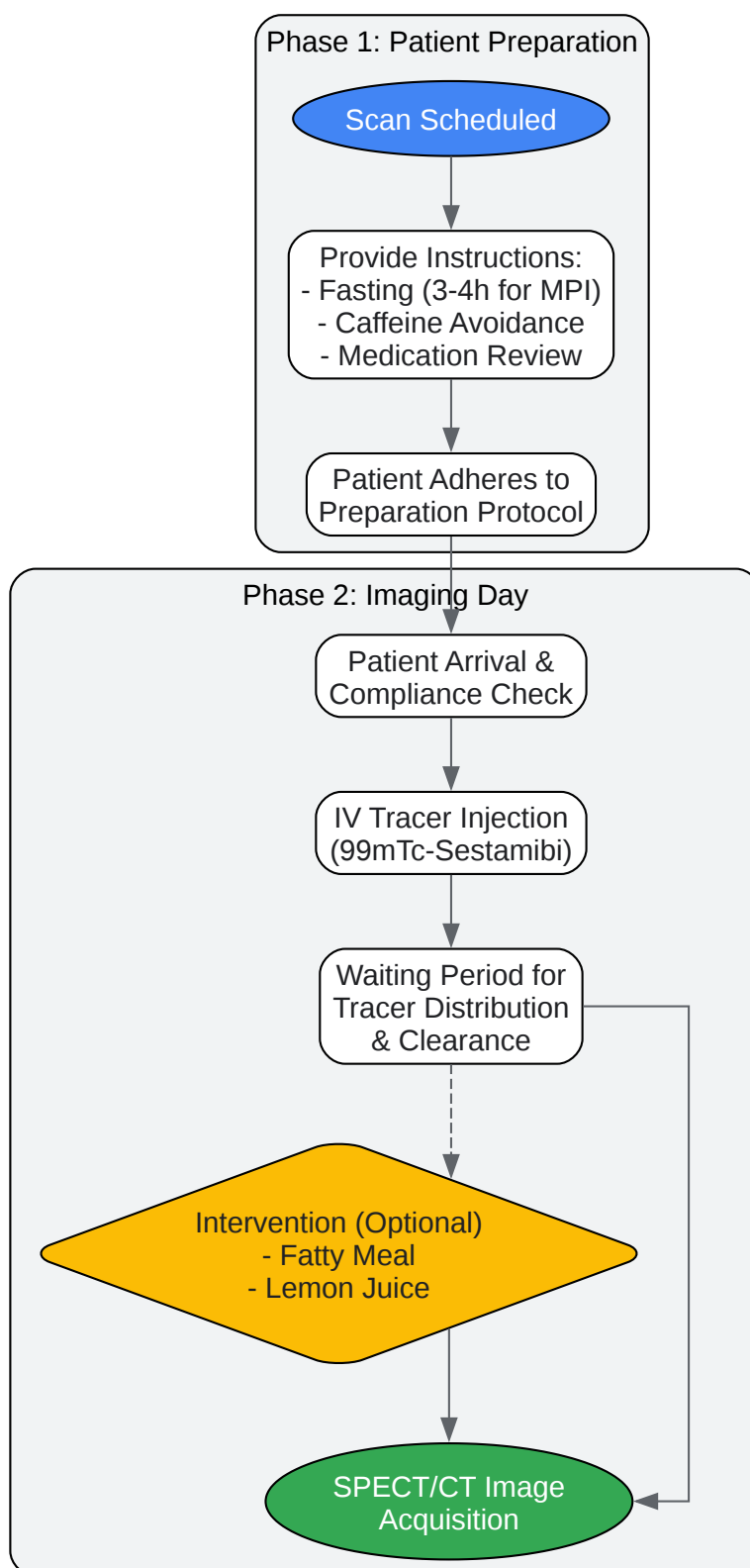
- Pre-Scan Patient Preparation (Minimum 12-24 hours prior):
  - Discontinue all caffeine-containing foods, drinks, and medications.[\[5\]](#)[\[6\]](#)
  - Withhold specific cardiac medications as directed by the referring physician.[\[1\]](#)
  - Instruct the patient to fast for a minimum of 3-4 hours before the appointment.[\[2\]](#)
- Day of Scan - Stress Phase:
  - Verify patient compliance with all preparation instructions.
  - Establish intravenous (IV) access.
  - Perform stress test (exercise or pharmacologic).
  - Inject 99mTc-Sestamibi (typically a higher dose for the stress phase in a 1-day protocol) at peak stress.[\[2\]](#)
  - Encourage at least one additional minute of exercise post-injection if applicable.[\[2\]](#)
  - Wait approximately 15-30 minutes after injection to allow for initial hepatobiliary clearance.[\[1\]](#)
  - Acquire SPECT images of the heart.
- Day of Scan - Rest Phase:
  - Allow a sufficient delay after the stress study (e.g., 3 hours for a 1-day protocol).[\[24\]](#)
  - Inject a second, lower dose of 99mTc-Sestamibi while the patient is at rest.
  - Wait approximately 45-60 minutes post-injection to allow for tracer distribution and clearance.[\[1\]](#)
  - Acquire a second set of SPECT images.

#### Protocol 2: Patient Preparation for 99mTc-Sestamibi Parathyroid Imaging (Dual-Phase)

- Patient Screening:
  - No specific fasting or medication adjustments are typically required.[\[4\]](#)
  - Document any history of thyroid or prior parathyroid surgery.
- Radiopharmaceutical Administration:
  - Establish IV access.
  - Inject 99mTc-Sestamibi (e.g., 740 MBq / 20 mCi).[\[6\]](#)
- Image Acquisition:
  - Early Phase: Acquire planar and/or SPECT/CT images of the neck and mediastinum approximately 10-15 minutes after injection.[\[6\]](#)[\[21\]](#)
  - Delayed Phase: Acquire a second set of planar and/or SPECT/CT images approximately 2 hours post-injection.[\[6\]](#)[\[20\]](#)[\[21\]](#) The parathyroid adenoma typically retains the tracer longer than the surrounding thyroid tissue.
  - Optional Subtraction Imaging: In some protocols, a thyroid-specific agent (like Iodine-123 or 99mTc-pertechnetate) is also administered, and its image is digitally subtracted from the Sestamibi image to isolate parathyroid activity.[\[4\]](#)

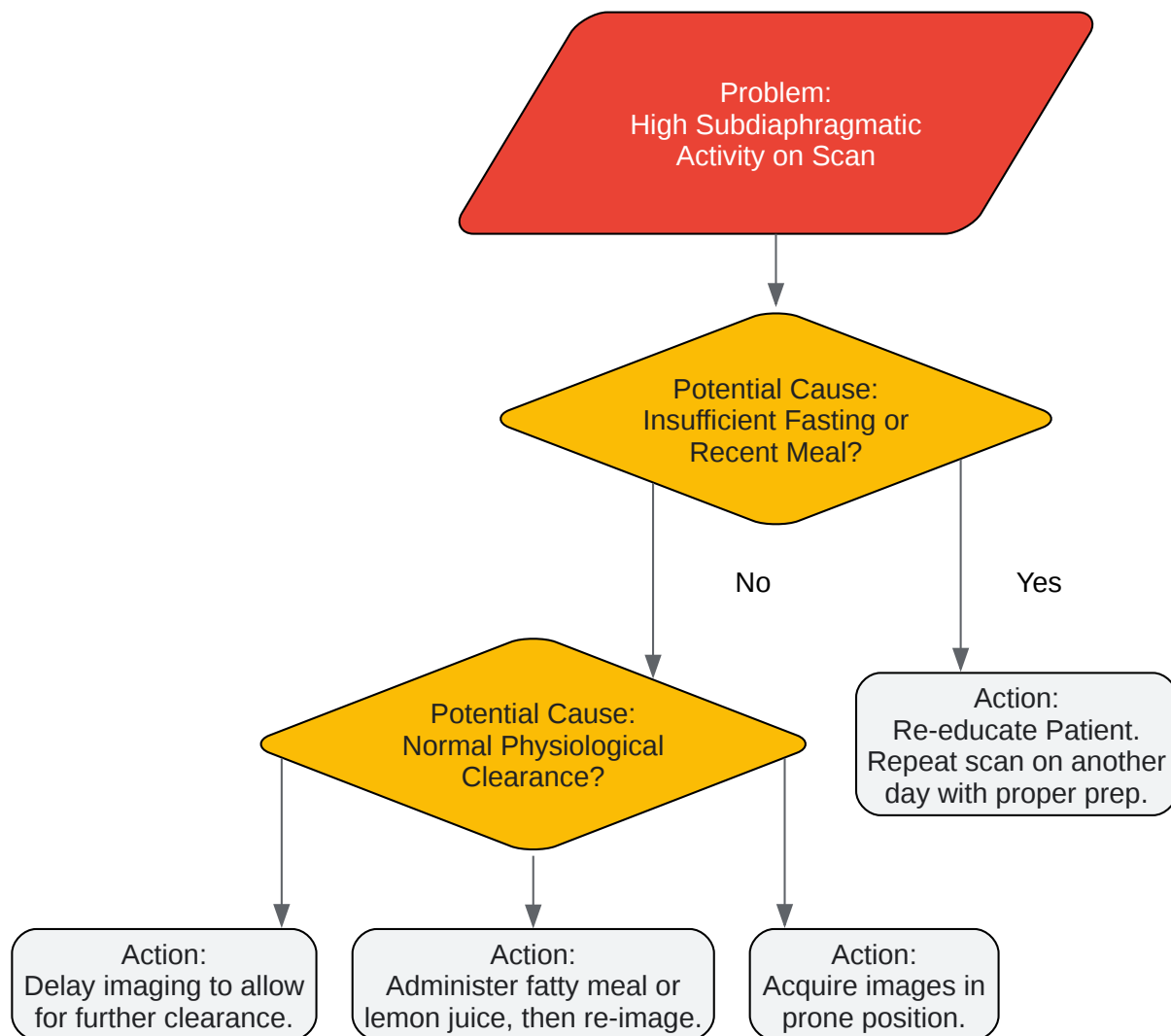
## Visualizations





[Click to download full resolution via product page](#)

Caption: Workflow of Patient Preparation for a Sestamibi Scan.



[Click to download full resolution via product page](#)

Caption: Troubleshooting Logic for Poor Sestamibi Scan Quality.

#### Need Custom Synthesis?

BenchChem offers custom synthesis for rare earth carbides and specific isotopic labeling.

Email: [info@benchchem.com](mailto:info@benchchem.com) or [Request Quote Online](#).

## References

- 1. [tech.snmjournals.org](http://tech.snmjournals.org) [[tech.snmjournals.org](http://tech.snmjournals.org)]
- 2. [asnc.org](http://asnc.org) [[asnc.org](http://asnc.org)]
- 3. [researchgate.net](http://researchgate.net) [[researchgate.net](http://researchgate.net)]
- 4. [snmmi.org](http://snmmi.org) [[snmmi.org](http://snmmi.org)]
- 5. [cabrini.com.au](http://cabrini.com.au) [[cabrini.com.au](http://cabrini.com.au)]
- 6. [radiopaedia.org](http://radiopaedia.org) [[radiopaedia.org](http://radiopaedia.org)]
- 7. Gallbladder dynamics induced by a fatty meal in normal subjects and patients with gallstones: concise communication - PubMed [[pubmed.ncbi.nlm.nih.gov](http://pubmed.ncbi.nlm.nih.gov)]
- 8. Gallbladder Dysfunction Diagnosed by Cholescintigraphy with a Fatty Meal - PMC [[pmc.ncbi.nlm.nih.gov](http://pmc.ncbi.nlm.nih.gov)]
- 9. Gallbladder contraction: effects of fatty meals and cholecystokinin - PubMed [[pubmed.ncbi.nlm.nih.gov](http://pubmed.ncbi.nlm.nih.gov)]
- 10. [eanm.org](http://eanm.org) [[eanm.org](http://eanm.org)]
- 11. [drugs.com](http://drugs.com) [[drugs.com](http://drugs.com)]
- 12. [irjnm.tums.ac.ir](http://irjnm.tums.ac.ir) [[irjnm.tums.ac.ir](http://irjnm.tums.ac.ir)]
- 13. Effect of ursodeoxycholic acid in facilitating early hepatic clearance of radiotracer among patients undergoing 99mTc-sestamibi myocardial perfusion scintigraphy: A randomized double blind placebo controlled parallel trial - PubMed [[pubmed.ncbi.nlm.nih.gov](http://pubmed.ncbi.nlm.nih.gov)]
- 14. Evaluating the Impact of Ursodeoxycholic Acid on Hepatic Clearance of [99mTc]Tc-Sestamibi: A Randomized Controlled Trial to Improve Myocardial Perfusion Imaging - PubMed [[pubmed.ncbi.nlm.nih.gov](http://pubmed.ncbi.nlm.nih.gov)]
- 15. [eanm.org](http://eanm.org) [[eanm.org](http://eanm.org)]
- 16. Parathyroid Sestamibi Scan Technical Page: How Parathyroid Sestamibi Scanning is Performed. This is a page for Radiologists and Nuclear Medicine Techs. [[parathyroid.com](http://parathyroid.com)]
- 17. Sestamibi Scan for Parathyroid Disease. Sestamibi parathyroid x-ray scan locates problem parathyroid glands and parathyroid tumors. Sestamibi is the BEST parathyroid x-ray. [[parathyroid.com](http://parathyroid.com)]
- 18. Sestamibi parathyroid scan - Wikipedia [[en.wikipedia.org](http://en.wikipedia.org)]
- 19. Effective factors on the sensitivity of preoperative sestamibi scanning for primary hyperparathyroidism - PMC [[pmc.ncbi.nlm.nih.gov](http://pmc.ncbi.nlm.nih.gov)]

- 20. Optimal imaging time for delayed images in the diagnosis of abnormal parathyroid tissue with Tc-99m sestamibi - PubMed [pubmed.ncbi.nlm.nih.gov]
- 21. Quantitative application of dual-phase 99mTc-sestamibi SPECT/CT imaging of parathyroid lesions: identification of optimal timing in secondary hyperparathyroidism - PMC [pmc.ncbi.nlm.nih.gov]
- 22. The utility of repeat sestamibi scans in patients with primary hyperparathyroidism after an initial negative scan - PubMed [pubmed.ncbi.nlm.nih.gov]
- 23. Use of a Fatty Meal Cholecystagogue Protocol in Hepatobiliary Scintigraphy for Chronic Functional Gallbladder Disease - PMC [pmc.ncbi.nlm.nih.gov]
- 24. asnc.org [asnc.org]
- To cite this document: BenchChem. [Technical Support Center: Sestamibi Scan Accuracy and Patient Preparation]. BenchChem, [2025]. [Online PDF]. Available at: [https://www.benchchem.com/product/b1142544#impact-of-patient-preparation-on-sestamibi-scan-accuracy]

---

#### Disclaimer & Data Validity:

The information provided in this document is for Research Use Only (RUO) and is strictly not intended for diagnostic or therapeutic procedures. While BenchChem strives to provide accurate protocols, we make no warranties, express or implied, regarding the fitness of this product for every specific experimental setup.

**Technical Support:** The protocols provided are for reference purposes. Unsure if this reagent suits your experiment? [[Contact our Ph.D. Support Team for a compatibility check](#)]

**Need Industrial/Bulk Grade?** [Request Custom Synthesis Quote](#)

## BenchChem

Our mission is to be the trusted global source of essential and advanced chemicals, empowering scientists and researchers to drive progress in science and industry.

#### Contact

Address: 3281 E Guasti Rd

Ontario, CA 91761, United States

Phone: (601) 213-4426

Email: [info@benchchem.com](mailto:info@benchchem.com)