

Technical Support Center: Sestamibi Imaging of Ectopic Parathyroid Glands

Author: BenchChem Technical Support Team. **Date:** December 2025

Compound of Interest

Compound Name: *TECHNETIUM SESTAMIBI*

Cat. No.: *B1142544*

[Get Quote](#)

This guide provides troubleshooting advice and answers to frequently asked questions for researchers, scientists, and drug development professionals working with Technetium-99m Sestamibi imaging for the localization of ectopic parathyroid glands.

Troubleshooting Guide

This section addresses common challenges encountered during Sestamibi imaging that can lead to inaccurate localization of ectopic parathyroid glands.

Question: Why did our Sestamibi scan fail to detect a surgically confirmed ectopic parathyroid adenoma (False-Negative Result)?

Answer: False-negative Sestamibi scans in the context of ectopic parathyroid glands can be attributed to several factors related to gland biology, size, location, and technical parameters.

Key Factors Contributing to False-Negative Scans:

- **Small Gland Size:** The detectability of adenomas is highly dependent on their size and weight.[1][2] Lesions smaller than 250-600 mg are more likely to be missed.[1][2]
- **Histopathology:** Adenomas with a lower density of mitochondria-rich oxyphil cells may exhibit reduced Sestamibi uptake.[2] Glands with a high proportion of clear cells or significant cystic components can also lead to false-negative results due to diminished cellular density.[2]

- **Ectopic Location:** The very nature of ectopic glands makes them challenging to locate. Deep mediastinal, retro-esophageal, or intrathyroidal glands can be obscured by surrounding tissues.[2][3] Ultrasound, for instance, has limited accuracy for identifying glands in the carotid sheath, retro-esophageal region, and mediastinum.[3]
- **Multiglandular Disease (MGD):** The presence of multiple hyperfunctioning glands, such as in parathyroid hyperplasia, reduces the sensitivity of Sestamibi scans.[2][4] Hyperplastic glands often show faster radiotracer washout compared to adenomas.[5]
- **Rapid Washout:** Some adenomas (10-15%) exhibit rapid washout of the Sestamibi tracer, similar to the thyroid gland, making them invisible on delayed imaging.[5]
- **Co-existing Thyroid Disease:** Concurrent thyroid pathologies like nodular goiter or autoimmune thyroiditis can interfere with the scan, reducing its diagnostic accuracy.[2][4]
- **P-glycoprotein (P-gp) Expression:** Overexpression of the P-gp drug metabolism transporter can cause rapid efflux of the Sestamibi tracer from the parathyroid cells, leading to a negative scan.
- **Medications:** The use of calcium channel blockers has been associated with a higher likelihood of a negative MIBI scan.[2]

Question: Our Sestamibi scan indicated an ectopic adenoma, but none was found during surgery (False-Positive Result). What are the common causes?

Answer: False-positive results occur when tissues other than a hyperfunctioning parathyroid gland concentrate the Sestamibi tracer.

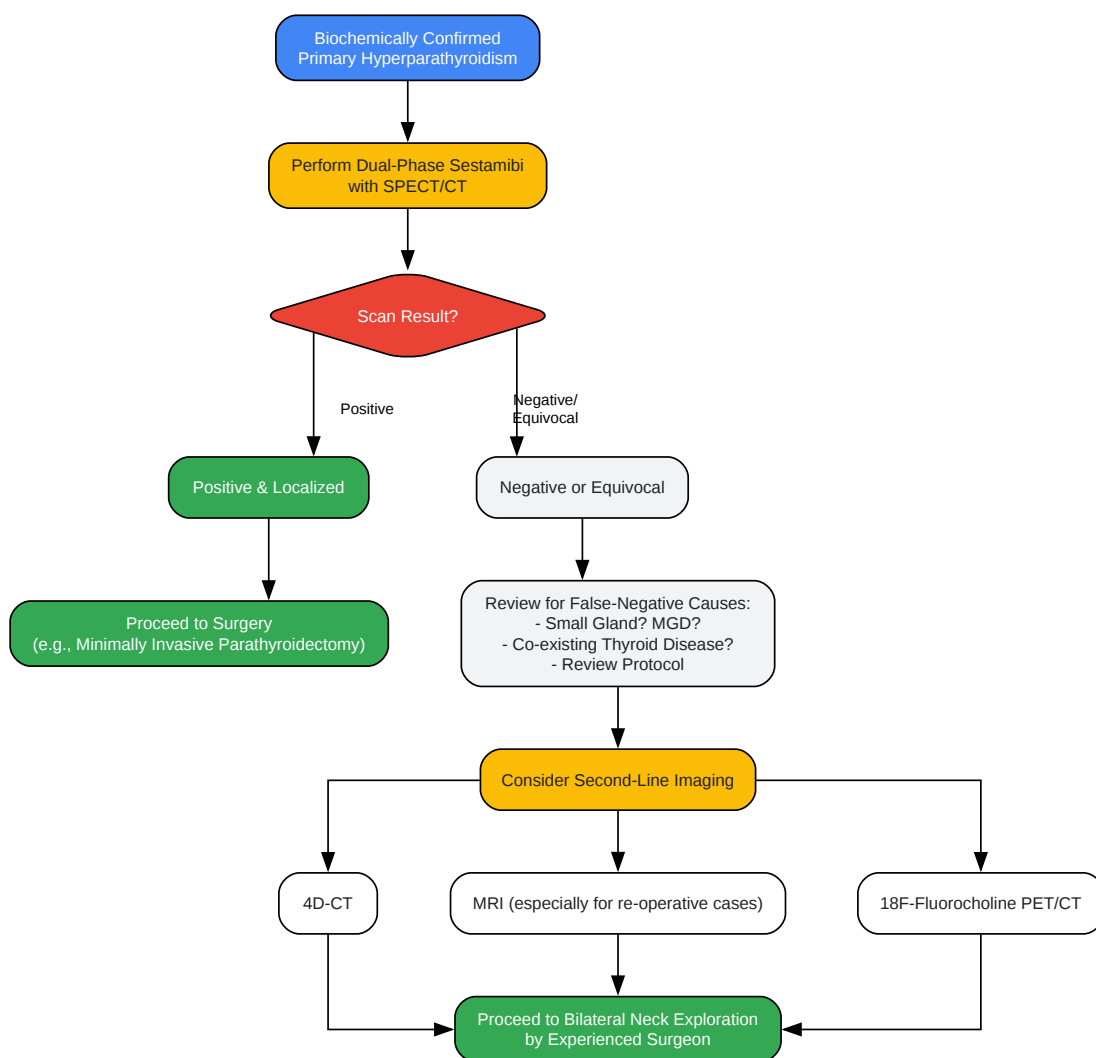
Common Causes of False-Positive Scans:

- **Thyroid Pathology:** Thyroid adenomas (particularly Hürthle cell), thyroid cancer, and nodular goiter are frequent causes of false-positive findings as they are often rich in mitochondria.[6][7]
- **Lymph Nodes:** Reactive or metastatic lymph nodes can also accumulate Sestamibi.[6]

- **Brown Adipose Tissue:** Brown fat, which can be present in the neck and shoulders, is metabolically active and can take up Sestamibi, creating the illusion of an ectopic gland.[\[6\]](#)[\[7\]](#)
- **Tracer Retention in Veins:** If the radiotracer is injected in the arm on the same side as a suspected lesion, retention of the isotope in a vein can be misinterpreted as an ectopic adenoma.[\[6\]](#) Injecting the tracer in the contralateral hand can help avoid this issue.[\[6\]](#)[\[7\]](#)
- **Other Tissues:** Less common causes include other tumors like thymomas.[\[7\]](#)

Logical Troubleshooting Workflow

This diagram outlines a decision-making process when faced with a negative or equivocal initial Sestamibi scan for a patient with biochemically confirmed primary hyperparathyroidism.



[Click to download full resolution via product page](#)

Caption: Troubleshooting workflow for inconclusive Sestamibi scans.

Frequently Asked Questions (FAQs)

Question: What is the most effective Sestamibi imaging protocol for detecting ectopic glands?

Answer: A combination of techniques is generally most effective. The recommended approach involves a dual-phase 99mTc-Sestamibi protocol combined with Single-Photon Emission Computed Tomography/Computed Tomography (SPECT/CT).[\[3\]](#)[\[8\]](#)

- Dual-Phase: Acquiring early (10-20 min) and delayed (90-150 min) images helps differentiate parathyroid from thyroid tissue based on differential washout rates.[\[5\]](#)[\[9\]](#)
- SPECT/CT: This hybrid imaging technique is crucial as it fuses functional data from the Sestamibi scan with anatomical data from a low-dose CT scan.[\[9\]](#)[\[10\]](#) This provides precise three-dimensional localization of ectopic glands, which is a major limitation of planar imaging alone.[\[3\]](#)[\[9\]](#) SPECT/CT has been shown to be superior to planar scintigraphy or SPECT alone for localizing ectopic adenomas.[\[3\]](#)[\[11\]](#)

Question: How can we improve the sensitivity of our Sestamibi scans, especially for small or deep lesions?

Answer: To maximize sensitivity, consider the following technical enhancements:

- Use a Pinhole Collimator: For imaging the neck, a pinhole collimator provides superior resolution and sensitivity compared to a standard parallel-hole collimator.[\[12\]](#)[\[13\]](#) This can significantly improve the detection of smaller adenomas.[\[1\]](#)
- Implement Dual-Isotope Subtraction: This technique involves the simultaneous or sequential administration of a second tracer that is taken up by the thyroid (e.g., 123-Iodine or 99mTc-pertechnetate).[\[5\]](#) The thyroid image is then digitally subtracted from the Sestamibi image, which can unmask parathyroid adenomas that are adjacent to or obscured by thyroid tissue.[\[5\]](#)[\[14\]](#)
- Combine with Other Modalities: No single imaging study is perfect. For challenging cases, especially re-operative surgeries or when initial scans are negative, combining Sestamibi SPECT/CT with another high-resolution modality like 4D-CT or MRI provides the highest localization accuracy.[\[3\]](#)[\[10\]](#)[\[15\]](#)

Question: What is 4D-CT and how does it compare to Sestamibi SPECT/CT for ectopic glands?

Answer: Four-dimensional CT (4D-CT) is a dynamic imaging technique that involves multiphase CT scanning of the neck and chest after the injection of intravenous contrast. It provides excellent anatomical detail and can identify parathyroid adenomas based on their characteristic vascular pattern (arterial enhancement and venous washout).[16]

- Advantages: 4D-CT is highly sensitive for localizing ectopic adenomas and can be particularly useful when Sestamibi scans are negative or equivocal.[3][17]
- Limitations: It involves a higher radiation dose compared to the CT component of SPECT/CT and requires expertise in interpretation.[18]
- Comparison: Both Sestamibi SPECT/CT and 4D-CT have high sensitivities for ectopic glands. Some studies suggest 4D-CT may have a slight advantage in certain situations, while others show comparable accuracy.[19] The choice often depends on institutional expertise and the specific clinical scenario. A combination of both is often used for difficult cases.[17]

Data Presentation: Diagnostic Performance of Imaging Modalities

The following tables summarize the reported diagnostic accuracy of various imaging modalities for the localization of parathyroid adenomas, including ectopic glands. Note that performance can vary significantly based on the patient population and specific techniques used.

Table 1: Performance of Sestamibi-Based Techniques

Imaging Modality	Sensitivity	Specificity	Positive Predictive Value (PPV)	Reference(s)
Planar Sestamibi Scintigraphy	63% - 93.3%	75% - 100%	70.5% - 100%	[11] [20] [21]
Sestamibi with SPECT	66% - 90%	-	82%	[11] [22] [23]
Sestamibi with SPECT/CT	84% - 97%	100%	90% - 95%	[11] [21] [24]
Dual-Phase SPECT/CT	84.4% - 93.8%	-	83.3% - 90.0%	[24]

Table 2: Performance of Other and Combined Imaging Modalities

Imaging Modality	Sensitivity	Specificity	Positive Predictive Value (PPV)	Reference(s)
Neck Ultrasound (Overall)	55% - 94.6%	-	74% - 97.2%	[21]
4D-CT	62% - 90.4%	75% - 100%	100%	[16] [18] [19]
MRI	70% - 93%	-	-	[15] [16] [18]
Sestamibi + Ultrasound (Combined)	81% - 95%	-	-	[10] [21]
Sestamibi + CT/MRI (Combined)	100%	100%	-	[10]

Experimental Protocols

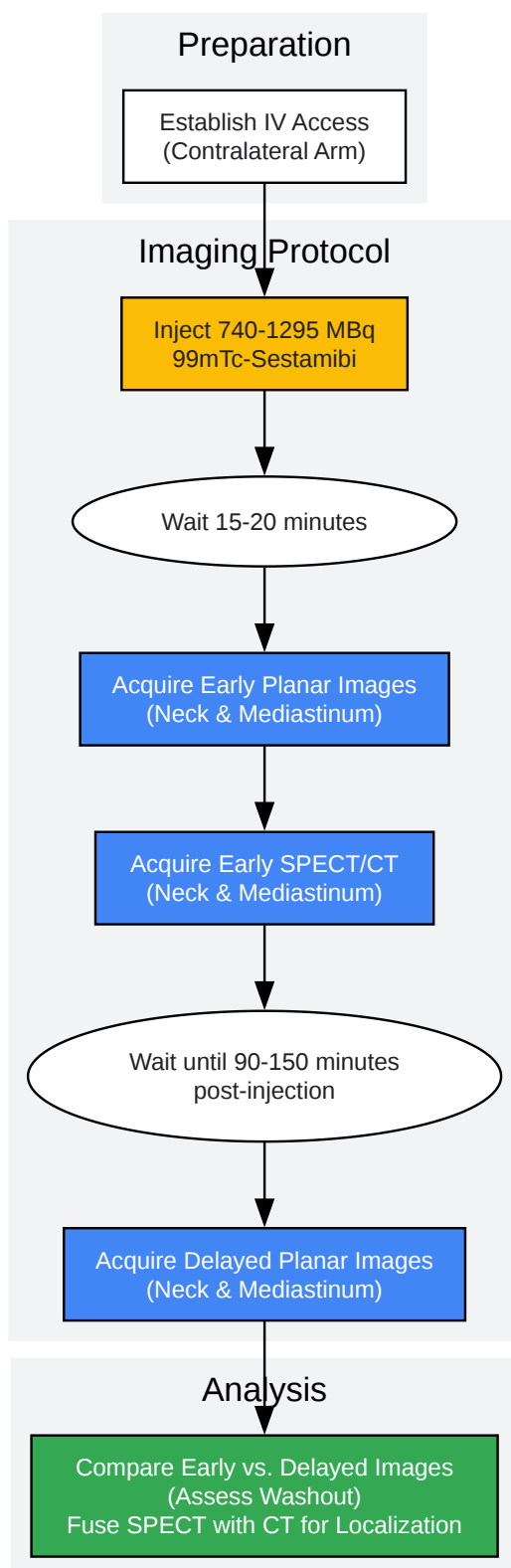
Protocol 1: Dual-Phase ^{99m}Tc-Sestamibi with SPECT/CT

This protocol is designed to maximize both functional differentiation and anatomical localization.

- Patient Preparation: No specific preparation is typically required. Ensure an intravenous line is placed, preferably in the arm contralateral to any suspected pathology.[\[6\]](#)
- Radiotracer Administration: Administer an intravenous injection of 740-1,295 MBq (20-35 mCi) of ^{99m}Tc-Sestamibi.[\[5\]](#)[\[9\]](#)
- Early Imaging (10-30 minutes post-injection):
 - Acquire anterior planar images of the neck and mediastinum. Use of a pinhole collimator for the neck images is recommended for higher resolution.[\[5\]](#)
 - Immediately following planar imaging, perform a SPECT/CT scan over the same region (from the base of the skull to the carina).[\[5\]](#)[\[9\]](#)
- Delayed Imaging (1.5 - 2.5 hours post-injection):
 - Repeat the planar images of the neck and mediastinum.[\[5\]](#)
 - A second SPECT/CT at this stage is optional but can be valuable in cases of equivocal findings on early scans.[\[24\]](#)
- Image Interpretation:
 - Analyze the dual-phase planar images for any focus of tracer uptake that persists or increases in intensity on the delayed images relative to the thyroid, which typically shows washout.[\[5\]](#)
 - Fuse the SPECT and CT images. A parathyroid adenoma should appear as a focal area of intense radiotracer accumulation corresponding to a soft-tissue nodule on the CT scan, providing precise anatomical context.[\[5\]](#)[\[9\]](#)

Workflow Visualization

This diagram illustrates the key steps in a comprehensive dual-isotope, dual-phase imaging protocol.



[Click to download full resolution via product page](#)

Caption: Experimental workflow for dual-phase Sestamibi SPECT/CT.

Need Custom Synthesis?

BenchChem offers custom synthesis for rare earth carbides and specific isotopic labeling.

Email: info@benchchem.com or [Request Quote Online](#).

References

- 1. Parathyroid imaging with technetium-99m sestamibi - PubMed [pubmed.ncbi.nlm.nih.gov]
- 2. False-negative 99mTc-sestamibi scans: factors and outcomes in primary hyperparathyroidism - PMC [pmc.ncbi.nlm.nih.gov]
- 3. contenido.acronline.org [contenido.acronline.org]
- 4. ec.bioscientifica.com [ec.bioscientifica.com]
- 5. tech.snmjournals.org [tech.snmjournals.org]
- 6. The Right Hand Must Know What the Left Hand is Doing: A False-Positive Hotspot on the Sestamibi Scan - PMC [pmc.ncbi.nlm.nih.gov]
- 7. researchgate.net [researchgate.net]
- 8. droracle.ai [droracle.ai]
- 9. Ectopic Submandibular Parathyroid Adenoma by Tc-99m Sestamibi SPECT/CT Localization - Journal of Clinical Imaging Science [clinicalimagingscience.org]
- 10. researchgate.net [researchgate.net]
- 11. Frontiers | Incremental Value of Sestamibi SPECT/CT Over Dual-Phase Planar Scintigraphy in Patients With Primary Hyperparathyroidism and Inconclusive Ultrasound [frontiersin.org]
- 12. Parathyroid imaging: the importance of pinhole collimation with both single- and dual-tracer acquisition - PubMed [pubmed.ncbi.nlm.nih.gov]
- 13. tech.snmjournals.org [tech.snmjournals.org]
- 14. DSpace [helda.helsinki.fi]
- 15. Ectopic parathyroid adenomas: multi-imaging modalities and its management - PubMed [pubmed.ncbi.nlm.nih.gov]
- 16. Parathyroid Adenoma Imaging: Practice Essentials, Computed Tomography, Magnetic Resonance Imaging [emedicine.medscape.com]

- 17. Challenges in the Management of Ectopic Parathyroid Pathologies: A Case Series of Five Patients - PMC [pmc.ncbi.nlm.nih.gov]
- 18. droracle.ai [droracle.ai]
- 19. Comparison of four-dimensional CT and Sestamibi SPECTCT in the localization management of primary hyperparathyroidism - PMC [pmc.ncbi.nlm.nih.gov]
- 20. The diagnostic utility of dual phase Tc-99m sestamibi parathyroid imaging - PubMed [pubmed.ncbi.nlm.nih.gov]
- 21. Ultrasound and Technetium-99m Sestamibi Scintigraphy Diagnostic Performance as Preferred Localization Techniques in Patients with Primary Hyperparathyroidism: A Literature Review [wjoes.com]
- 22. researchgate.net [researchgate.net]
- 23. researchgate.net [researchgate.net]
- 24. Is dual-phase SPECT/CT with 99mTc-sestamibi better than single-phase SPECT/CT for lesion localization in patients with hyperparathyroidism? - PMC [pmc.ncbi.nlm.nih.gov]
- To cite this document: BenchChem. [Technical Support Center: Sestamibi Imaging of Ectopic Parathyroid Glands]. BenchChem, [2025]. [Online PDF]. Available at: [https://www.benchchem.com/product/b1142544#overcoming-challenges-in-sestamibi-imaging-of-ectopic-parathyroid-glands]

Disclaimer & Data Validity:

The information provided in this document is for Research Use Only (RUO) and is strictly not intended for diagnostic or therapeutic procedures. While BenchChem strives to provide accurate protocols, we make no warranties, express or implied, regarding the fitness of this product for every specific experimental setup.

Technical Support: The protocols provided are for reference purposes. Unsure if this reagent suits your experiment? [[Contact our Ph.D. Support Team for a compatibility check](#)]

Need Industrial/Bulk Grade? [Request Custom Synthesis Quote](#)

BenchChem

Our mission is to be the trusted global source of essential and advanced chemicals, empowering scientists and researchers to drive progress in science and industry.

Contact

Address: 3281 E Guasti Rd

Ontario, CA 91761, United States

Phone: (601) 213-4426

Email: info@benchchem.com