

# Technical Support Center: Segmenting Confluent Lesions in Multiple Sclerosis MRI

**Author:** BenchChem Technical Support Team. **Date:** December 2025

## Compound of Interest

Compound Name: WYneN

Cat. No.: B15548174

[Get Quote](#)

This technical support center provides troubleshooting guides and frequently asked questions (FAQs) to address the challenges researchers, scientists, and drug development professionals encounter when segmenting confluent multiple sclerosis (MS) lesions in Magnetic Resonance Imaging (MRI).

## Frequently Asked Questions (FAQs)

Q1: What are confluent lesions and why do they pose a segmentation challenge?

A: In the early stages of multiple sclerosis, lesions in the brain's white matter are typically discrete and focal.<sup>[1]</sup> As the disease progresses, these individual lesions can grow and merge, forming larger, irregularly shaped areas of damage known as confluent lesions.<sup>[1][2]</sup> This confluence is a major challenge for both manual and automated segmentation methods. The primary difficulty lies in accurately identifying and separating the individual lesions that have merged, which is critical for precise disease monitoring.<sup>[3][4]</sup> Standard automated techniques that group connected bright pixels often fail to distinguish between a single large lesion and multiple smaller, pathologically distinct lesions that have become confluent.

Q2: My automated segmentation algorithm is merging distinct lesions into one large confluent area. Why is this happening and how can I address it?

A: This is a common issue, particularly with algorithms that use a semantic segmentation approach followed by a post-processing step like "connected components" (CC) analysis. The CC method identifies any spatially connected group of lesion voxels as a single instance, which

is inherently unable to separate confluent lesions. This can lead to a significant underestimation of the true lesion count, especially in patients with a high lesion load.

#### Troubleshooting Steps:

- **Review the Algorithm's Methodology:** Check if your algorithm is based on a simple connected components approach.
- **Explore Advanced Post-Processing:** Some methods, like the Hessian-based approach, attempt to identify distinct lesion centers within a confluent cluster to partition it into separate lesion candidates. Another method, Automated Confluent Splitting (ACLS), exists but tends to oversplit lesions, leading to an overestimation of lesion counts.
- **Consider Instance Segmentation Models:** For a more robust solution, consider using an end-to-end instance segmentation framework. Models like ConfLUNet are specifically designed to jointly optimize lesion detection and delineation, showing significant improvement over traditional methods for separating confluent lesions.

Q3: What are the best practices for manually segmenting confluent lesions to ensure consistency?

A: Manual segmentation is often considered the gold standard but is time-consuming and prone to inter- and intra-rater variability, especially with complex confluent lesions.

#### Best Practices:

- **Use a Multi-Contrast Approach:** Relying on a single MRI contrast is not recommended. A multimodal protocol using 3D T1-weighted and 3D FLAIR images, supported by conventional T2-weighted and proton-density images, is superior for lesion identification and delineation.
- **Establish Clear Lesion Criteria:** Define strict criteria for what constitutes a lesion (e.g., must be hyperintense on T2/FLAIR, hypointense on T1, and consist of at least 3 contiguous voxels).
- **Develop a Standardized Protocol:** Create a detailed protocol for raters that outlines how to handle ambiguous borders and how to attempt to separate individual lesions within a confluent area, if possible.

- **Blinded Re-reads and Consensus Reviews:** Have multiple expert raters segment the same scans independently. Where discrepancies arise, a consensus review should be performed to finalize the segmentation. This reduces individual bias.
- **Training and Calibration:** Ensure all raters are thoroughly trained on the protocol. Periodic calibration exercises, where all raters segment the same set of images and compare results, can help maintain consistency over time.

Q4: How can I differentiate between periventricular and deep white matter confluent lesions?

A: White matter lesions are often categorized based on their location. Periventricular white matter lesions (PVWMLs) are attached to or contiguous with the brain's ventricular system. Deep white matter lesions (DWMLs) are located separately in the subcortical white matter. This distinction is functionally relevant, as PVWMLs are more strongly associated with cognitive decline, while DWMLs have been linked to mood disorders.

Identification Protocol:

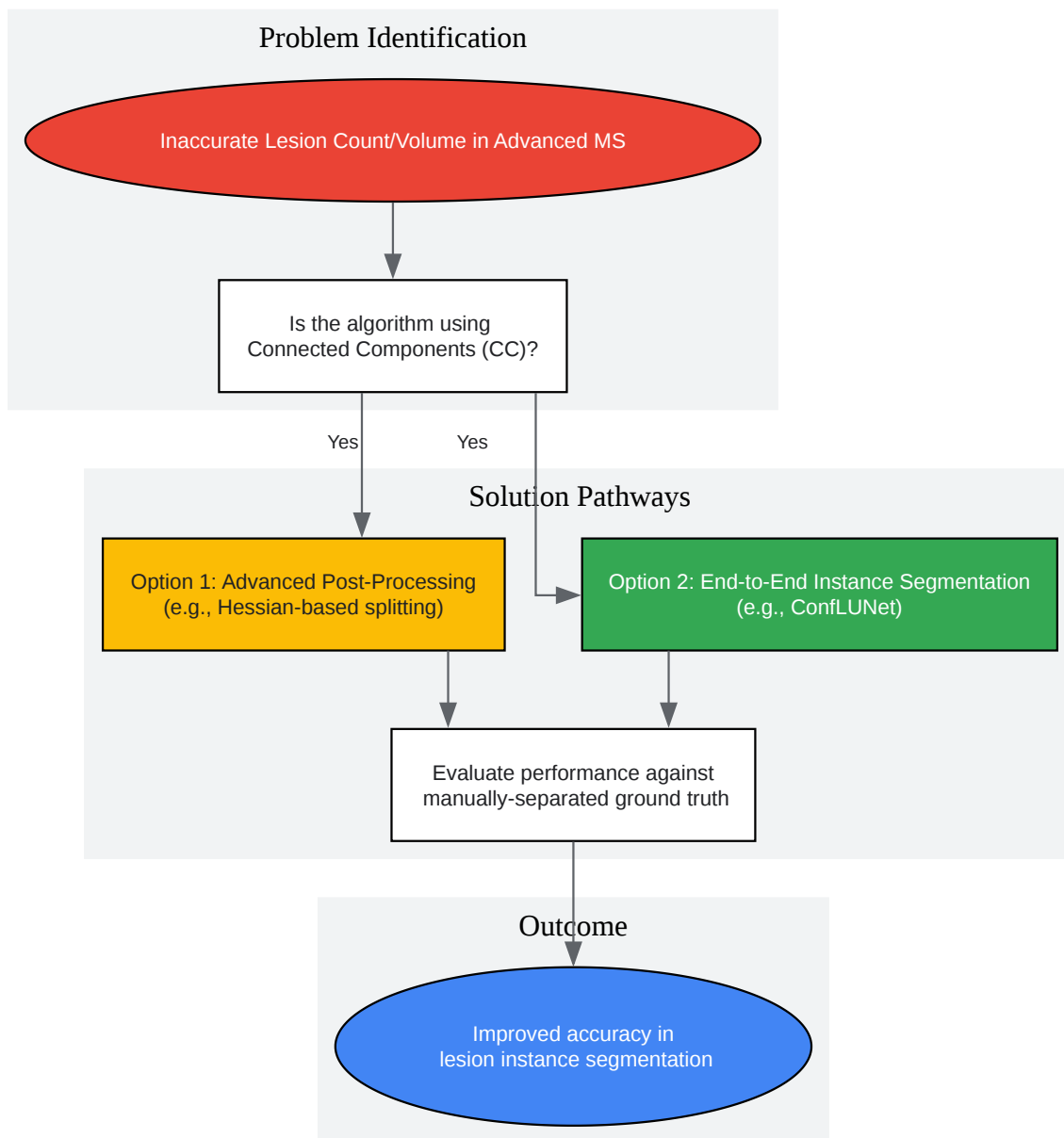
- **Anatomical Reference:** Use a co-registered T1-weighted image to clearly visualize the ventricles.
- **Proximity Rule:** A common approach is to define a proximity threshold. For example, periventricular lesions can be defined as those where at least one lesion voxel is within a specific distance (e.g., 4 mm) of a ventricle. Lesions that do not meet this criterion are classified as deep white matter lesions.
- **Automated Classification:** Some software tools can automatically classify lesions based on their spatial relationship to an anatomical atlas of the ventricular system.

## Troubleshooting Guides

### Guide 1: Inaccurate Lesion Volume and Count in Advanced MS

- **Problem:** You observe that your automated pipeline reports a lower lesion count and a less-than-expected increase in total lesion volume over time in patients with advanced MS, despite clinical evidence of disease progression.

- Probable Cause: As the disease progresses, individual lesions merge into large confluent clusters. Your segmentation algorithm likely uses a connected components analysis, which incorrectly counts these large clusters as single lesions, leading to an underestimation of the true lesion number.
- Solution Workflow:



[Click to download full resolution via product page](#)

Workflow for troubleshooting inaccurate lesion counts.

## Guide 2: High False Positive Rate in Periventricular Regions

- **Problem:** Your segmentation results show a high number of false positive lesions, particularly around the ventricles.
- **Probable Cause:** The FLAIR (Fluid-Attenuated Inversion Recovery) sequence, while sensitive to white matter lesions, can sometimes cause hyperintensities in the periventricular region due to CSF flow artifacts or incomplete CSF signal nulling. These artifacts can be mistaken for lesions.
- **Solution Protocol:**
  - **Multi-Contrast Review:** Do not rely solely on FLAIR images. Cross-reference any potential lesion with T1-weighted and T2-weighted images. True MS lesions are typically hypointense on T1-weighted images.
  - **Intensity and Morphology Analysis:** True lesions often have a characteristic ovoid shape and orientation perpendicular to the ventricles. Artifacts may have a more linear or irregular appearance.
  - **Refine Pre-processing:** Ensure that image pre-processing steps, such as inhomogeneity correction and intensity normalization, are correctly applied across all sequences.
  - **Algorithm Training Data:** If using a supervised machine learning model, ensure the training data includes examples of these common artifacts labeled as non-lesions to improve the model's specificity.

## Quantitative Data Summary

Table 1: Comparison of Automated Segmentation Methods for Confluent Lesions

This table compares the performance of different automated approaches for segmenting individual lesion instances, highlighting the challenges faced by traditional methods with confluent lesions.

Method Category	Core Technology	Advantage	Disadvantage with Confluent Lesions	Reference
Semantic + Connected Components (CC)	CNN (e.g., U-Net) for voxel-wise segmentation, then groups connected voxels.	Simple to implement post-segmentation.	Fails to separate touching or merged lesions, leading to undercounting.	
Semantic + Automated Splitting (ACLS)	CNN for voxel-wise segmentation, followed by an algorithm to split confluent masses.	Attempts to address confluence directly.	Tends to oversplit lesions, resulting in poor precision and overcounting.	
End-to-End Instance Segmentation (ConfLUNet)	A single deep learning model that simultaneously detects and delineates each lesion instance.	Specifically designed to handle confluence; jointly optimizes detection and segmentation.	Outperforms CC and ACLS in both detection and instance segmentation quality.	

Table 2: Performance Metrics for Confluent Lesion Unit (CLU) Detection

Quantitative results comparing ConfLUNet to baseline methods for detecting Confluent Lesion Units (CLUs), which represent the individual pathological lesions. Data is from a study on a held-out test set.

Method	F1 Score (CLU)	Precision (CLU)	Recall (CLU)	Key Finding
Connected Components (CC)	-	High	Low	Consistently underestimates CLU counts due to low recall.
ACLS	-	Low	High	Tends to oversplit, leading to low precision.
ConfLUNet	81.5%	High	High	Achieves the highest F1 score by improving recall over CC and precision over ACLS.

## Experimental Protocols & Methodologies

### Protocol 1: Multi-Contrast Manual Segmentation of Cortical and Confluent Lesions

This protocol is based on a study comparing different manual reading methods.

- Image Acquisition: Acquire 3D T1-weighted, 3D FLAIR, dual fast spin-echo proton-density/T2-weighted (PD/T2) images. A 3T MRI scanner is recommended for higher resolution and signal-to-noise ratio.
- Pre-processing:
  - Perform bias field correction on all images.
  - Resample all images to a 1-mm isotropic resolution.
  - Linearly register FLAIR, PD, and T2 images to the T1-weighted image space.
- Segmentation Criteria: A region is defined as a lesion if it:



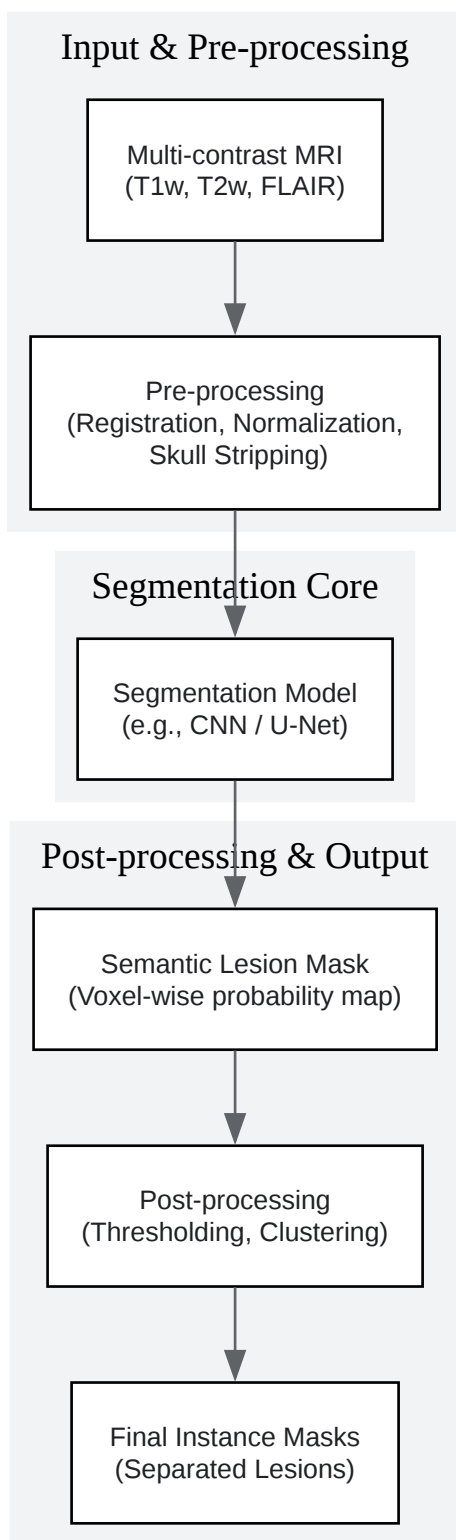
- Includes at least 3 contiguous voxels.
- Appears hyperintense on T2-weighted and FLAIR images.
- Appears hypointense on T1-weighted images relative to adjacent normal-appearing cortex or white matter.
- Procedure: Raters should view all co-registered image contrasts simultaneously. The high gray matter/white matter contrast of the T1-weighted sequence is particularly useful for assessing whether a lesion crosses a cortical boundary. For confluent lesions, raters should use morphological cues and intensity variations across different contrasts to infer the boundaries of the original, distinct lesions where possible.

## Protocol 2: Automated Instance Segmentation using an End-to-End Framework

This describes a generalized workflow for a modern instance segmentation approach like ConfLUNet.

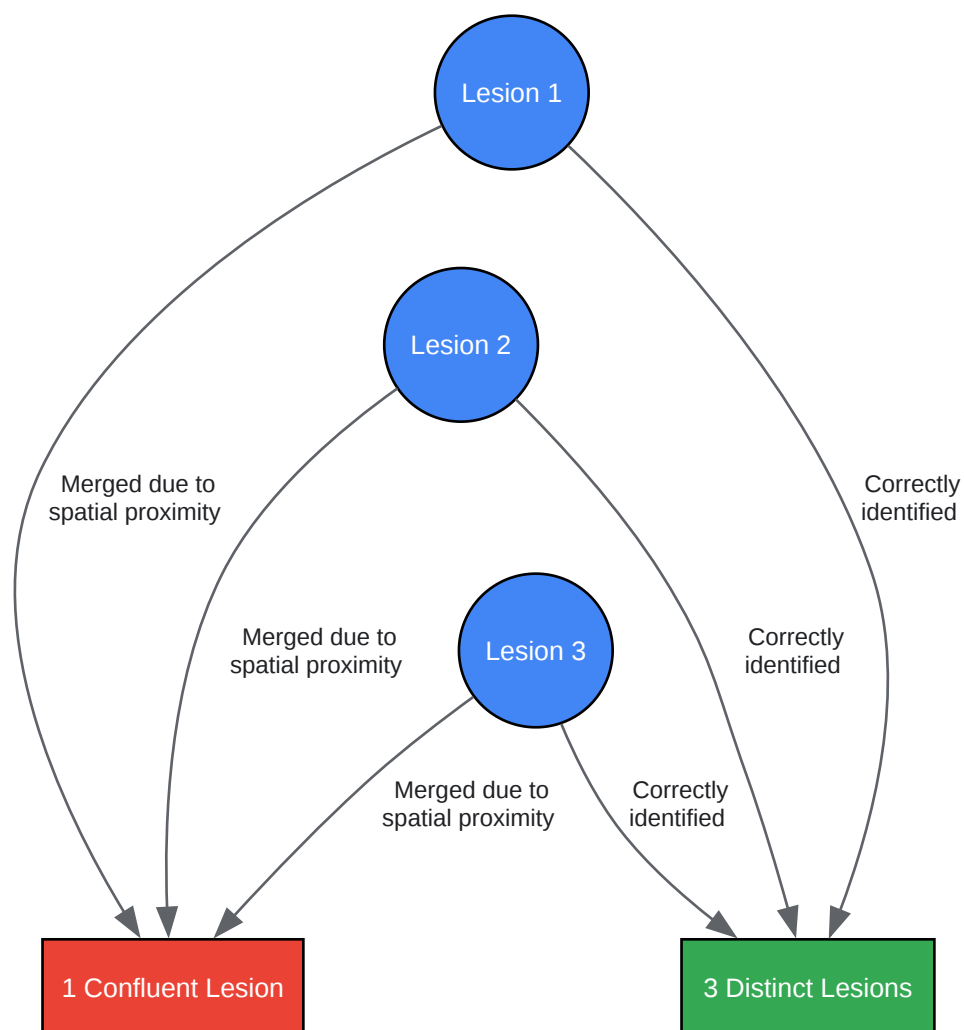
- Input Data: Typically requires a single FLAIR image as input, though multi-contrast inputs are possible.
- Model Architecture: The model is an end-to-end framework, meaning it takes the raw (pre-processed) image and outputs the final instance masks without intermediate steps like semantic segmentation followed by clustering.
- Training: The model is trained on a dataset where each individual lesion, including those within confluent regions, has been manually delineated as a separate instance. This ground truth is crucial for teaching the model to distinguish between merged lesions.
- Output: The model outputs a set of individual masks, where each mask corresponds to a single predicted lesion instance. This directly provides a lesion count and delineation for each instance, avoiding the pitfalls of connected components analysis.

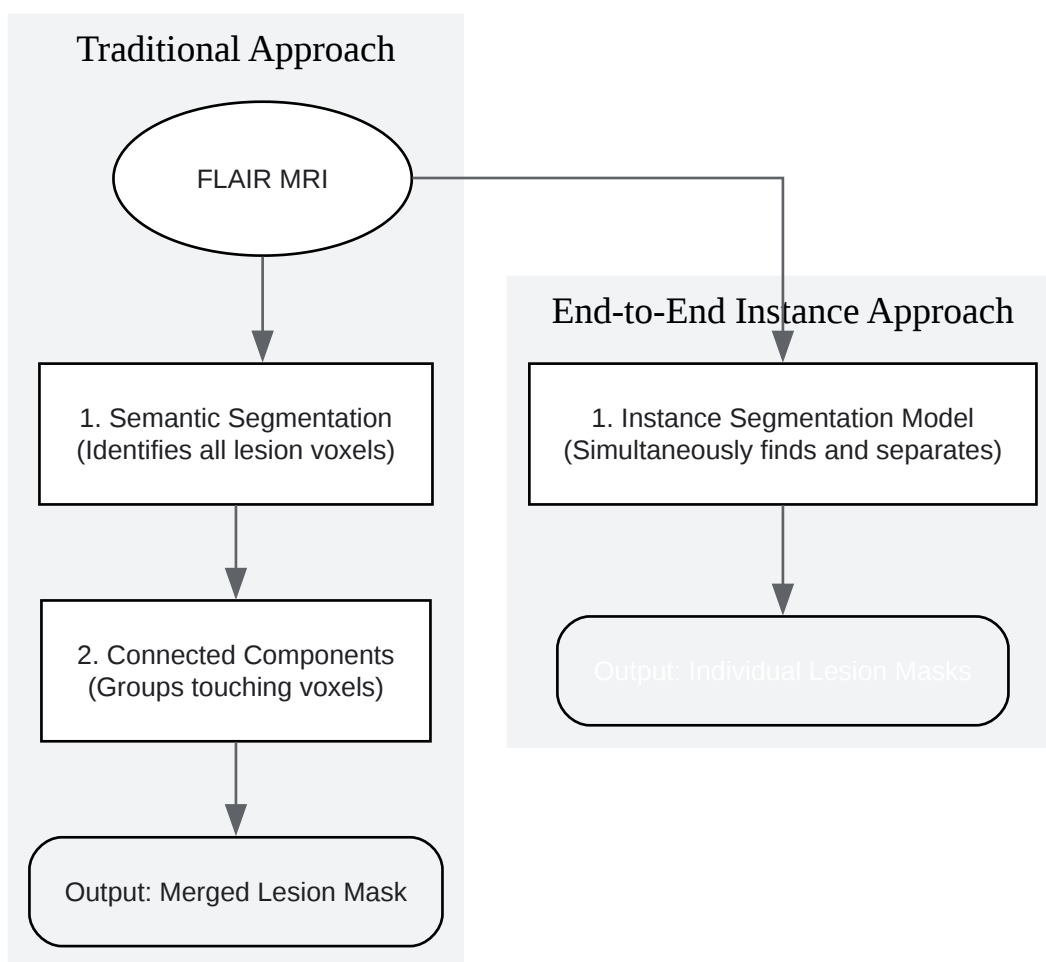
## Visualizations



[Click to download full resolution via product page](#)

A typical automated semantic segmentation workflow.





[Click to download full resolution via product page](#)

### Need Custom Synthesis?

BenchChem offers custom synthesis for rare earth carbides and specific isotopic labeling.

Email: [info@benchchem.com](mailto:info@benchchem.com) or [Request Quote Online](#).

## References

- 1. atc.udg.edu [atc.udg.edu]
- 2. Computer-Assisted Segmentation of White Matter Lesions in 3D MR images, Using Support Vector Machine - PMC [pmc.ncbi.nlm.nih.gov]
- 3. [2505.22537] ConfLUNet: Multiple sclerosis lesion instance segmentation in presence of confluent lesions [arxiv.org]

- 4. An Automated Statistical Technique for Counting Distinct Multiple Sclerosis Lesions - PMC [pmc.ncbi.nlm.nih.gov]
- To cite this document: BenchChem. [Technical Support Center: Segmenting Confluent Lesions in Multiple Sclerosis MRI]. BenchChem, [2025]. [Online PDF]. Available at: [https://www.benchchem.com/product/b15548174#challenges-in-segmenting-confluent-lesions-in-multiple-sclerosis-mri]

---

#### Disclaimer & Data Validity:

The information provided in this document is for Research Use Only (RUO) and is strictly not intended for diagnostic or therapeutic procedures. While BenchChem strives to provide accurate protocols, we make no warranties, express or implied, regarding the fitness of this product for every specific experimental setup.

**Technical Support:** The protocols provided are for reference purposes. Unsure if this reagent suits your experiment? [[Contact our Ph.D. Support Team for a compatibility check](#)]

**Need Industrial/Bulk Grade?** [Request Custom Synthesis Quote](#)

## BenchChem

Our mission is to be the trusted global source of essential and advanced chemicals, empowering scientists and researchers to drive progress in science and industry.

#### Contact

Address: 3281 E Guasti Rd  
Ontario, CA 91761, United States  
Phone: (601) 213-4426  
Email: [info@benchchem.com](mailto:info@benchchem.com)