

# Technical Support Center: Psoas Muscle Pyomyositis Diagnostics

**Author:** BenchChem Technical Support Team. **Date:** December 2025

## Compound of Interest

Compound Name: *Piomy*

Cat. No.: *B1172056*

[Get Quote](#)

This technical support center provides troubleshooting guides and frequently asked questions (FAQs) for researchers, scientists, and drug development professionals investigating psoas muscle pyomyositis.

## Frequently Asked Questions (FAQs)

Q1: What are the primary challenges in the early diagnosis of psoas muscle pyomyositis?

The early diagnosis of psoas muscle pyomyositis is challenging due to its insidious onset and nonspecific initial symptoms.[1][2] The deep anatomical location of the psoas muscle often prevents palpable swelling or a "woody" texture in the initial stages.[1] Patients frequently present with vague symptoms such as low-grade fever, malaise, and dull pain in the back, flank, or hip.[3] These symptoms can mimic a wide range of other conditions, leading to a broad differential diagnosis and potential diagnostic delays.[4][5]

Q2: What are the typical clinical stages of psoas muscle pyomyositis and their key features?

Psoas muscle pyomyositis typically progresses through three clinical stages if left untreated:

- **Stage 1 (Invasive Stage):** This initial stage, lasting about 1 to 3 weeks, is characterized by mild, dull pain, and a variable low-grade fever.[1][3] Local signs of inflammation are often minimal, and there may be mild leukocytosis and an elevated erythrocyte sedimentation rate (ESR).[4] Only about 2% of patients are diagnosed in this stage.[4]

- Stage 2 (Suppurative Stage): Occurring after 10 to 21 days, this stage involves more pronounced fever and tenderness as a frank abscess forms.<sup>[1]</sup> The diagnosis is most commonly established in this stage when imaging can clearly demonstrate a fluid collection.<sup>[1]</sup>
- Stage 3 (Late Stage): If the infection remains untreated, this stage is marked by intense local pain and systemic findings, including sepsis and septic shock.<sup>[1][6]</sup>

Q3: What is the utility of different imaging modalities in diagnosing psoas muscle pyomyositis?

Magnetic Resonance Imaging (MRI) is considered the imaging modality of choice for diagnosing psoas pyomyositis, especially in the early stages, due to its high sensitivity for detecting muscle inflammation and edema.<sup>[1][7][8]</sup> Computed Tomography (CT) with contrast is also highly effective for detecting abscess formation and is often more readily available.<sup>[6][9]</sup> Ultrasound can be a useful initial imaging tool, particularly for guiding aspiration of fluid collections; however, its sensitivity is lower, especially in the early, non-suppurative stage, and a negative ultrasound does not rule out the diagnosis.<sup>[1][9]</sup>

Q4: What are the common causative organisms in psoas muscle pyomyositis?

Staphylococcus aureus is the most common causative organism in psoas muscle pyomyositis.<sup>[10][11]</sup> Other less common bacterial pathogens include Streptococcus species and Escherichia coli.<sup>[11][12]</sup> In some cases, the infection can be polymicrobial.

## Troubleshooting Guides

Problem: A patient presents with suspected psoas muscle pyomyositis, but initial ultrasound imaging is negative.

- Possible Cause: The disease may be in the early invasive stage (Stage 1), where a discrete abscess has not yet formed. Ultrasound has a lower sensitivity in this stage.<sup>[1]</sup>
- Solution:
  - Maintain a high index of suspicion based on clinical symptoms (fever, back/hip pain, limp).

- Proceed with more sensitive imaging, such as a contrast-enhanced CT scan or an MRI of the pelvis.[1][4] MRI is particularly effective at detecting early muscle edema.[8][13]
- Repeat imaging in a few days if clinical suspicion remains high and initial advanced imaging is inconclusive.[14][15]

Problem: Blood cultures from a patient with a confirmed psoas abscess are negative.

- Possible Cause: Blood cultures are not always positive in psoas pyomyositis. The reported rate of positive blood cultures can be as low as 5-35% in pyomyositis, although it may be higher in cases with frank abscesses.[3] Prior antibiotic administration can also lead to negative blood cultures.
- Solution:
  - The definitive diagnosis of the causative organism should be made from a culture of the abscess fluid itself.
  - Obtain a sample of the purulent material via image-guided (CT or ultrasound) aspiration or surgical drainage for Gram stain and culture.[6]

Problem: Difficulty in differentiating psoas pyomyositis from other conditions with similar presentations.

- Possible Cause: The differential diagnosis for psoas pyomyositis is broad and includes septic arthritis of the hip, osteomyelitis, appendicitis (especially on the right side), diverticulitis, deep vein thrombosis, and retroperitoneal hematoma.[4][5]
- Solution:
  - A thorough clinical examination focusing on the hip's range of motion (pain on extension is a key sign) is crucial.[10]
  - Utilize advanced imaging. MRI can help differentiate between soft tissue infection, bone infection (osteomyelitis), and joint effusion (septic arthritis).[7]

- Laboratory markers such as C-reactive protein (CRP) and ESR are typically elevated in pyomyositis but are non-specific.[\[1\]](#)[\[16\]](#)

## Data Presentation

Table 1: Diagnostic Accuracy of Imaging Modalities for Psoas Abscess

Imaging Modality	Sensitivity (Overall)	Sensitivity (Days 1-5 from Onset)	Reference
Plain CT	78%	33%	<a href="#">[14]</a> <a href="#">[15]</a>
Enhanced CT	86%	50%	<a href="#">[14]</a> <a href="#">[15]</a>
Plain MRI	88%	50%	<a href="#">[14]</a> <a href="#">[15]</a>
Ultrasound	~60% (diagnostic in)	Not specified	<a href="#">[1]</a>

Table 2: Common Laboratory Findings in Psoas Pyomyositis

Laboratory Test	Typical Finding	Notes	Reference
White Blood Cell Count	Elevated (Leukocytosis)	Often with a neutrophilic predominance.	<a href="#">[1]</a> <a href="#">[4]</a>
Erythrocyte Sedimentation Rate (ESR)	Elevated	A non-specific marker of inflammation.	<a href="#">[1]</a> <a href="#">[4]</a>
C-Reactive Protein (CRP)	Elevated	A non-specific marker of inflammation.	<a href="#">[1]</a> <a href="#">[16]</a>
Blood Cultures	Positive in up to 70% of cases	The rate may be lower in the absence of a frank abscess.	<a href="#">[1]</a>
Creatine Kinase (CK)	Often normal or slightly elevated	Significant elevation is more characteristic of other myopathies.	<a href="#">[17]</a>

## Experimental Protocols

### 1. Protocol for Blood Culture Collection for Suspected Bacteremia

- Objective: To aseptically collect blood for culture to identify the causative organism of a potential systemic infection.
- Methodology:
  - Preparation: Identify the patient and explain the procedure. Gather necessary equipment: aerobic and anaerobic blood culture bottles, skin antiseptic (e.g., 2% chlorhexidine), sterile gloves, syringe, and butterfly collection system.[\[18\]](#)[\[19\]](#)
  - Site Disinfection: Vigorously cleanse the rubber septa of the blood culture bottles with a 70% alcohol wipe and allow to air dry.[\[18\]](#) Thoroughly disinfect the venipuncture site with the antiseptic solution, scrubbing for at least 30 seconds, and allow it to dry completely. Do not retouch the site.[\[18\]](#)[\[20\]](#)
  - Collection: Perform venipuncture using the syringe and butterfly system. For adults, collect 16-20 mL of blood per set.[\[20\]](#)
  - Inoculation: Transfer the collected blood into the blood culture bottles, inoculating the aerobic bottle first.[\[19\]](#) Gently invert the bottles to mix the blood with the culture medium.[\[20\]](#)
  - Labeling and Transport: Label the bottles with patient information, collection site, and time. Transport to the microbiology laboratory as soon as possible at room temperature.[\[18\]](#)[\[20\]](#)

### 2. Protocol for CT-Guided Psoas Abscess Aspiration and Drainage

- Objective: To obtain a sample of purulent material for microbiological analysis and to drain the abscess under imaging guidance.
- Methodology:
  - Patient Preparation: Obtain informed consent. The patient is typically placed in a prone or lateral decubitus position.

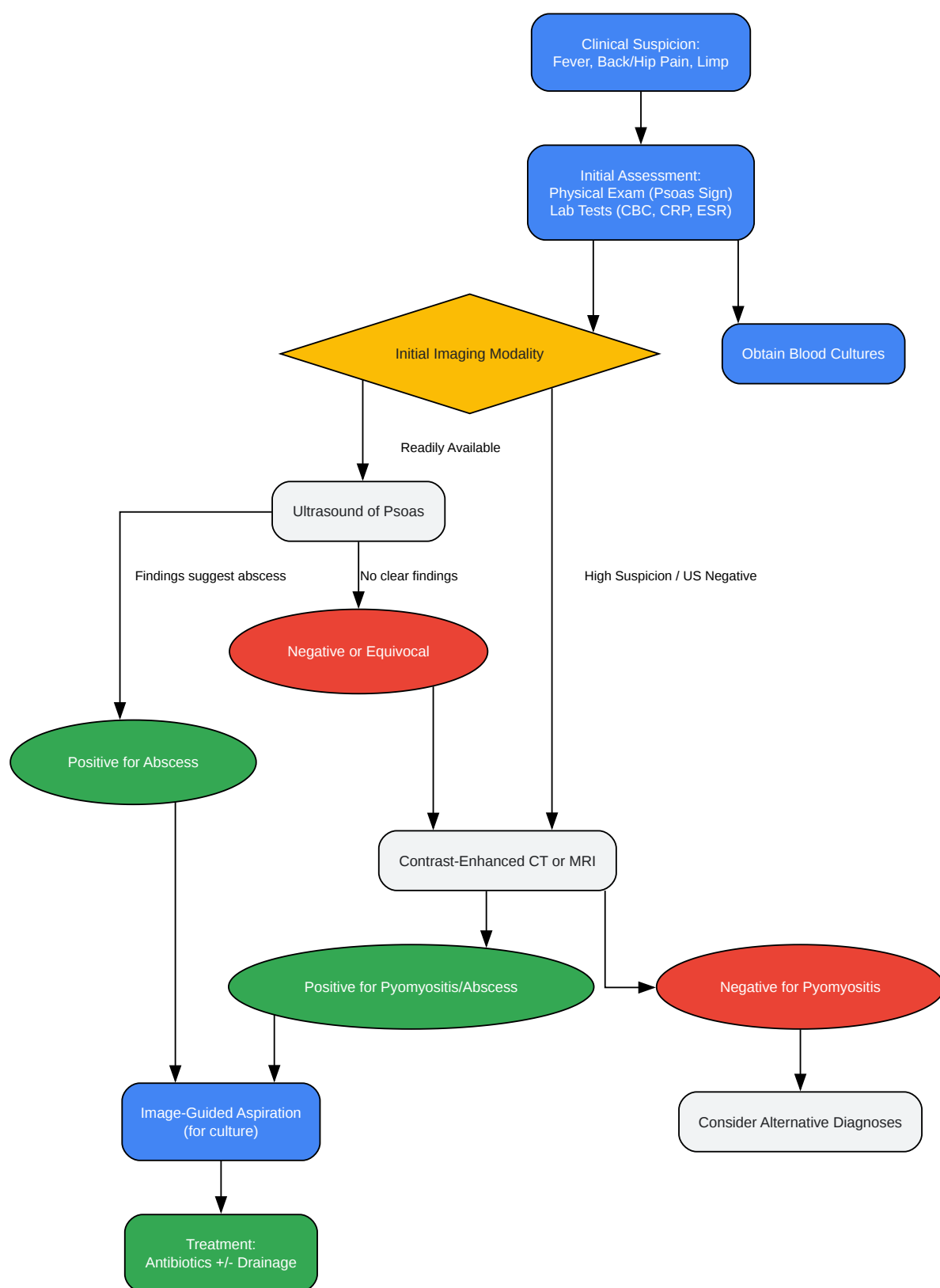
- Initial Imaging: Perform a non-contrast CT scan to localize the abscess and plan the safest access route, avoiding vital structures.
- Aspiration: Under sterile conditions and local anesthesia, a needle (e.g., 18-gauge) is advanced into the abscess cavity under CT fluoroscopic guidance.[\[21\]](#) A sample of the fluid is aspirated for Gram stain, culture, and sensitivity testing.
- Catheter Placement (if indicated): If drainage is required, a guidewire is inserted through the needle, which is then removed. The tract is dilated, and a drainage catheter (e.g., 8-14 French) is placed over the wire into the abscess cavity.[\[22\]](#)
- Confirmation and Securing: The catheter position is confirmed with a small amount of contrast injection and follow-up CT scans. The catheter is then secured to the skin and connected to a drainage bag.

### 3. Protocol for MRI of the Psoas Muscle

- Objective: To visualize the psoas muscle and surrounding structures to detect inflammation, edema, and abscess formation.
- Methodology:
  - Patient Positioning: The patient is positioned supine on the MRI table.
  - Coil Selection: A phased-array body coil is used to cover the area from the lower thoracic spine to the lesser trochanters of the femurs.
  - Sequences:
    - Axial T1-weighted: Provides anatomical detail.
    - Axial and Coronal T2-weighted with fat suppression (or STIR): Highly sensitive for detecting fluid and edema within the muscle.[\[9\]](#)[\[13\]](#)
    - Sagittal T2-weighted: To evaluate for extension from the spine.
    - Post-contrast Axial and Coronal T1-weighted with fat suppression: To assess for rim enhancement around an abscess.

- Slice Planning: Axial slices should be angled perpendicular to the psoas muscle. Slices must be sufficient to cover the entire muscle.

## Mandatory Visualization



[Click to download full resolution via product page](#)

Caption: Diagnostic workflow for suspected psoas pyomyositis.



Caption: Clinical stages and progression of psoas pyomyositis.

### Need Custom Synthesis?

BenchChem offers custom synthesis for rare earth carbides and specific isotopic labeling.

Email: [info@benchchem.com](mailto:info@benchchem.com) or [Request Quote Online](#).

## References

- 1. Pediatric Psoas Abscess, Early Diagnosis of a Challenging Condition - PMC [pmc.ncbi.nlm.nih.gov]
- 2. researchgate.net [researchgate.net]
- 3. Iliopsoas Pyomyositis With Bacteremia at an Early Stage of Presentation in a Temperate Region - PMC [pmc.ncbi.nlm.nih.gov]
- 4. actaorthopaedica.be [actaorthopaedica.be]
- 5. Staphylococcus aureus - Wikipedia [en.wikipedia.org]
- 6. Pyomyositis | Johns Hopkins ABX Guide [hopkinsguides.com]
- 7. Imaging on pelvic pyomyositis in children related to pathogenesis - PMC [pmc.ncbi.nlm.nih.gov]
- 8. researchgate.net [researchgate.net]
- 9. radiopaedia.org [radiopaedia.org]
- 10. Pyomyositis | MSF Medical Guidelines [medicalguidelines.msf.org]
- 11. Acute pyomyositis of the adductor magnus muscle involving the posterior and lateral thigh compartments: a case report of diagnosis and management - PMC [pmc.ncbi.nlm.nih.gov]
- 12. mdpi.com [mdpi.com]
- 13. Imaging Psoas Sign in Lumbar Spinal Infections: Evaluation of Diagnostic Accuracy and Comparison with Established Imaging Characteristics - PMC [pmc.ncbi.nlm.nih.gov]
- 14. researchgate.net [researchgate.net]
- 15. Limitations of using imaging diagnosis for psoas abscess in its early stage - PubMed [pubmed.ncbi.nlm.nih.gov]
- 16. Pyomyositis is not only a tropical pathology: a case series - PMC [pmc.ncbi.nlm.nih.gov]

- 17. Laboratory Test Abnormalities are Common in Polymyositis and Dermatomyositis and Differ Among Clinical and Demographic Groups - PMC [pmc.ncbi.nlm.nih.gov]
- 18. beaumontlaboratory.com [beaumontlaboratory.com]
- 19. Collection and Inoculation of Blood Specimens for Routine Culture (Bacterial, T.B. or Fungus) » Laboratory Alliance of Central New York, LLC [laboratoryalliance.com]
- 20. testmenu.com [testmenu.com]
- 21. Percutaneous drainage of iliopsoas abscess: an effective option in cases not suitable for surgery - PMC [pmc.ncbi.nlm.nih.gov]
- 22. CT-Guided Femoral Approach for Psoas Muscle Abscess Drainage - ProQuest [proquest.com]
- To cite this document: BenchChem. [Technical Support Center: Psoas Muscle Pyomyositis Diagnostics]. BenchChem, [2025]. [Online PDF]. Available at: [https://www.benchchem.com/product/b1172056#challenges-in-the-diagnosis-of-psoas-muscle-pyomyositis]

---

#### Disclaimer & Data Validity:

The information provided in this document is for Research Use Only (RUO) and is strictly not intended for diagnostic or therapeutic procedures. While BenchChem strives to provide accurate protocols, we make no warranties, express or implied, regarding the fitness of this product for every specific experimental setup.

**Technical Support:** The protocols provided are for reference purposes. Unsure if this reagent suits your experiment? [[Contact our Ph.D. Support Team for a compatibility check](#)]

**Need Industrial/Bulk Grade?** [Request Custom Synthesis Quote](#)

## BenchChem

Our mission is to be the trusted global source of essential and advanced chemicals, empowering scientists and researchers to drive progress in science and industry.

#### Contact

Address: 3281 E Guasti Rd

Ontario, CA 91761, United States

Phone: (601) 213-4426

Email: [info@benchchem.com](mailto:info@benchchem.com)