

# Technical Support Center: Pediatric Tracheostomy for Bilateral Vocal Fold Paralysis

**Author:** BenchChem Technical Support Team. **Date:** December 2025

## Compound of Interest

Compound Name: BVFP

Cat. No.: B5387700

[Get Quote](#)

This technical support center provides in-depth information for researchers, scientists, and drug development professionals on the challenges associated with pediatric tracheostomy for bilateral vocal fold paralysis (**BVFP**).

## Troubleshooting Guide

**Q1:** What are the primary challenges that necessitate a tracheostomy in pediatric patients with bilateral vocal fold paralysis?

**A1:** The primary challenge is acute airway obstruction. In pediatric **BVFP**, the vocal folds often rest in a median or paramedian position, critically narrowing the glottic airway. This leads to symptoms such as stridor, respiratory distress, suprasternal and chest retractions, sleep apnea, and failure to thrive.<sup>[1][2]</sup> In severe cases, this obstruction requires immediate airway intervention to ensure adequate ventilation, making tracheostomy a common and often life-saving procedure.<sup>[1][2][3]</sup> While traditionally considered the gold standard, the goal of many current therapeutic strategies is to avoid tracheostomy if possible.<sup>[1][2]</sup>

**Q2:** A research subject with a tracheostomy for **BVFP** is failing to wean from mechanical ventilation. What are the potential underlying issues?

**A2:** Failure to wean in this population can be multifactorial:

- **Persistent Upper Airway Obstruction:** Even with a tracheostomy, significant suprastomal (above the tracheostomy tube) obstruction from the paralyzed vocal folds can increase the

work of breathing.

- **Tracheostomy Tube Issues:** The tube may be too small, malpositioned, or obstructed with secretions.
- **Lower Airway Pathology:** Co-existing conditions such as tracheomalacia, bronchomalacia, or subglottic stenosis can contribute to ventilator dependence.
- **Pulmonary Comorbidities:** Underlying cardiac or pulmonary conditions can complicate weaning.
- **Neurological Immaturity:** In congenital cases, the neurological pathways for respiratory control may be underdeveloped.

A comprehensive evaluation, including flexible or rigid endoscopy, is crucial to identify the specific cause.

**Q3:** What are the common complications associated with long-term tracheostomy in pediatric **BVFP** that might impact experimental data?

**A3:** Long-term tracheostomy in children is associated with a significant chronic care burden and potential complications that can be confounding factors in research.<sup>[4]</sup> These include:

- **Granuloma Formation:** Irritation from the tracheostomy tube can lead to the formation of granulation tissue at the stoma or within the trachea, potentially causing obstruction.<sup>[4]</sup>
- **Tracheal Stenosis:** Scarring and inflammation at the stoma site or cuff location can lead to a narrowing of the airway.
- **Infection:** The stoma provides a direct portal for bacteria into the lower airway, increasing the risk of tracheitis and pneumonia.
- **Speech and Language Delay:** Bypassing the vocal folds can impact the development of normal speech and language.
- **Swallowing Dysfunction (Dysphagia):** The presence of the tube can tether the larynx, affecting its normal elevation during swallowing and potentially increasing the risk of aspiration.<sup>[4]</sup>

## Frequently Asked Questions (FAQs)

Q1: What is the likelihood of spontaneous recovery in pediatric **BVFP**, and how does this influence the decision for tracheostomy?

A1: A significant number of pediatric **BVFP** cases, particularly idiopathic ones, may resolve spontaneously.<sup>[1]</sup> Some literature suggests that spontaneous recovery of vocal cord motility is possible within the first one to two years in over two-thirds of patients.<sup>[1]</sup> This potential for recovery is a major factor in management decisions. Tracheostomy is often employed as a temporary measure to secure the airway while awaiting potential spontaneous resolution.<sup>[1][4]</sup>

Q2: What are the primary surgical alternatives to long-term tracheostomy, and what are their success rates?

A2: Several glottic widening procedures aim to create a larger airway, facilitating decannulation (removal of the tracheostomy tube). There is no definitive evidence showing the superiority of one procedure over another.<sup>[5][6]</sup> The choice of procedure is often individualized based on patient anatomy and surgeon expertise.<sup>[4]</sup>

Surgical Alternative	Description	Reported Success/Decannulation Rate	Key Considerations
Endoscopic Posterior Cricoid Split (EPCS) with Grafting	An endoscopic procedure to divide the posterior cricoid cartilage and insert a graft (often costal cartilage) to widen the posterior glottis.[7][8][9]	High rates of decannulation or avoidance of tracheostomy have been demonstrated.[10] One study reported a 74% success rate in avoiding tracheostomy.[11]	Preserves the anatomy of the vocal folds.[1][2] Risk of graft displacement and dysphagia.[1][2][9] A temporary tracheostomy may still be required post-operatively.[1][2]
CO2 Laser Posterior Cordotomy/Arytenoidectomy	Endoscopic procedures using a CO2 laser to remove a portion of the vocal fold (cordotomy) or the arytenoid cartilage (arytenoidectomy) to enlarge the airway.[12][13][14]	High rates of improved ventilation (95-100% in some studies) are reported.[12] One study on arytenoidectomy reported a 76.5% decannulation/extubation rate.[10]	Balances airway adequacy with voice preservation; voice quality may be worsened.[12][15] Complications can include granulation tissue formation.[12]
Suture Lateralization (Laterofixation)	An endoscopic technique where a suture is used to pull an arytenoid cartilage and the attached vocal fold to the side, opening the airway.[5][16]	Emerging as a promising technique to avoid tracheostomy, with good success rates reported in neonates.[17][18] A study on endoscopic arytenoid lateral abduction reported a 91% decannulation rate.[19]	Minimally invasive and potentially reversible.[1][2]
Laryngeal Reinnervation	A procedure that attempts to restore	This is still a developing area,	Aims to restore dynamic function

nerve supply to the laryngeal muscles responsible for vocal fold abduction.[5][20]	particularly in pediatrics. One review noted a 66% decannulation rate in a small number of reported cases.[17][18]	rather than creating a static opening.[15][16] Improvement can take months.[21]
This can involve transferring a nearby healthy nerve (e.g., from the phrenic nerve).[5]		

Q3: What are the key diagnostic procedures for evaluating pediatric **BVFP** prior to surgical intervention?

A3: A thorough diagnostic workup is essential for guiding treatment.

- Flexible Laryngoscopy: Performed while the child is awake to assess dynamic vocal fold movement and rule out other causes of stridor.[22][23]
- Direct Laryngoscopy and Bronchoscopy: A comprehensive examination of the airway under general anesthesia to confirm the diagnosis, assess for synchronous airway lesions, and palpate the cricoarytenoid joints to rule out fixation.[1][2]
- Laryngeal Electromyography (L-EMG): Can be used to differentiate between vocal fold paralysis (neurological issue) and fixation (mechanical issue) and may offer prognostic information, though its reliability as a prognostic indicator is debated.[5][17][18]
- Imaging: An MRI of the brain is often performed to rule out underlying neurological conditions such as Arnold-Chiari malformation.[22][23]

## Experimental Protocols

### Protocol 1: Endoscopic Posterior Cricoid Split (EPCS) with Costal Cartilage Graft

This protocol outlines the key steps for an EPCS with a rib graft, a common surgical alternative to long-term tracheostomy.

- **Anesthesia and Airway Management:** The patient is placed under general anesthesia. Ventilation is often maintained spontaneously with insufflation to allow for an unobstructed view of the larynx.[8]
- **Laryngeal Exposure:** A suspension laryngoscope is inserted to provide a clear and stable view of the glottis. A laryngeal spreader may be used to improve visualization of the posterior glottis.[7][9]
- **Posterior Cricoid Incision:** A CO2 laser or cold steel instrument (e.g., a sickle knife) is used to make a vertical incision through the midline of the posterior cricoid lamina.[7][8] Care is taken not to violate the posterior cricoid perichondrium.[7]
- **Graft Harvesting and Preparation:** While the airway is temporarily secured with an endotracheal tube, a section of costal cartilage (rib graft) is harvested.[8] The graft is then carved into a specific shape (e.g., an inverted "T") with the perichondrium preserved on the surface that will face the airway lumen.[7][8]
- **Graft Placement:** The endotracheal tube is removed, and spontaneous ventilation is resumed. The carved rib graft is endoscopically inserted into the cricoid split.[7] Its position is confirmed to ensure it is stenting the airway open.[7][8]
- **Postoperative Management:** The patient is typically intubated with a nasotracheal tube for a period to allow the graft to set before being transferred to the intensive care unit for monitoring.[8]

#### Protocol 2: CO2 Laser-Assisted Posterior Cordotomy

This protocol describes the general steps for widening the airway by removing a portion of the vocal fold.

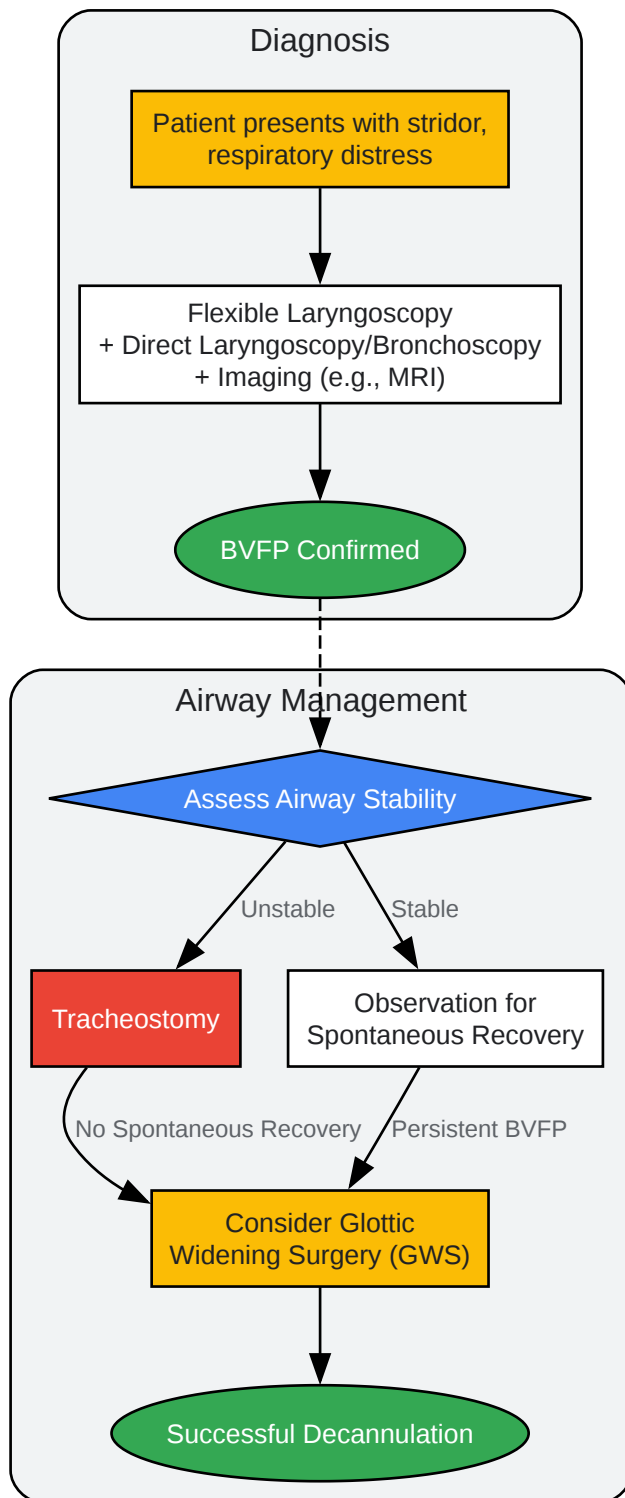
- **Anesthesia and Exposure:** The procedure is performed under general anesthesia. A suspension laryngoscope is used for exposure of the vocal folds.[13]
- **Laser Application:** A CO2 laser, coupled with a microscope, is used for the procedure.[13]
- **Cordotomy:** The laser is used to create a precise incision and remove a wedge of tissue from the posterior aspect of one vocal fold, near the vocal process of the arytenoid cartilage.[13]

[24] The extent of tissue removal is a critical balance between creating an adequate airway and preserving voice quality.[24]

- Hemostasis: The laser provides excellent hemostasis during the procedure.
- Postoperative Care: Patients are monitored for airway edema. A short course of steroids may be administered. Postoperative tracheostomy is rarely needed but may be required in cases of significant edema.[25]

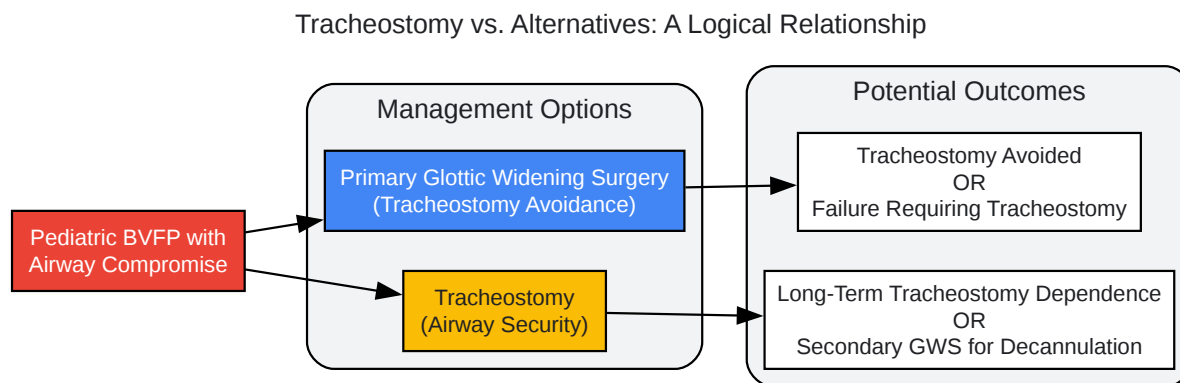
## Visualizations

## Decision-Making Workflow for Pediatric BVFP

[Click to download full resolution via product page](#)

Caption: Decision-making workflow for pediatric bilateral vocal fold paralysis.





[Click to download full resolution via product page](#)

Caption: Logical relationship between tracheostomy and alternative procedures.

#### Need Custom Synthesis?

BenchChem offers custom synthesis for rare earth carbides and specific isotopic labeling.

Email: [info@benchchem.com](mailto:info@benchchem.com) or [Request Quote Online](#).

## References

- 1. Frontiers | Surgical Options for Pediatric Bilateral Vocal Cord Palsy: State of the Art [frontiersin.org]
- 2. Surgical Options for Pediatric Bilateral Vocal Cord Palsy: State of the Art - PMC [pmc.ncbi.nlm.nih.gov]
- 3. publications.aap.org [publications.aap.org]
- 4. Bilateral Vocal Cord Paralysis - StatPearls - NCBI Bookshelf [ncbi.nlm.nih.gov]
- 5. mdpi.com [mdpi.com]
- 6. Management of Pediatric Bilateral Vocal Fold Paralysis: A State-of-the-Art Review of Etiologies, Diagnosis, and Treatments - PubMed [pubmed.ncbi.nlm.nih.gov]
- 7. csurgeries.com [csurgeries.com]
- 8. csurgeries.com [csurgeries.com]

- 9. csurgeries.com [csurgeries.com]
- 10. researchgate.net [researchgate.net]
- 11. 2024.sci-hub.se [2024.sci-hub.se]
- 12. researchgate.net [researchgate.net]
- 13. Awake office based trans nasal flexible endoscopic diode laser assisted posterior cordotomy for bilateral vocal fold paralysis - MedCrave online [medcraveonline.com]
- 14. researchgate.net [researchgate.net]
- 15. researchgate.net [researchgate.net]
- 16. researchgate.net [researchgate.net]
- 17. Management of bilateral vocal fold paralysis in children - PubMed [pubmed.ncbi.nlm.nih.gov]
- 18. Management of bilateral vocal fold paralysis in children. | Semantic Scholar [semanticscholar.org]
- 19. emedicine.medscape.com [emedicine.medscape.com]
- 20. m.youtube.com [m.youtube.com]
- 21. csurgeries.com [csurgeries.com]
- 22. A New Approach to Treating Bilateral Vocal Fold Paralysis | Children's Hospital of Philadelphia [chop.edu]
- 23. Vocal Cord Paralysis - Stanford Medicine Children's Health [stanfordchildrens.org]
- 24. youtube.com [youtube.com]
- 25. Carbon dioxide laser endoscopic posterior cordotomy technique for bilateral abductor vocal cord paralysis: a 15-year experience - PubMed [pubmed.ncbi.nlm.nih.gov]
- To cite this document: BenchChem. [Technical Support Center: Pediatric Tracheostomy for Bilateral Vocal Fold Paralysis]. BenchChem, [2025]. [Online PDF]. Available at: [https://www.benchchem.com/product/b5387700#challenges-in-pediatric-tracheostomy-for-bilateral-vocal-fold-paralysis]

---

### Disclaimer & Data Validity:

The information provided in this document is for Research Use Only (RUO) and is strictly not intended for diagnostic or therapeutic procedures. While BenchChem strives to provide

accurate protocols, we make no warranties, express or implied, regarding the fitness of this product for every specific experimental setup.

**Technical Support:** The protocols provided are for reference purposes. Unsure if this reagent suits your experiment? [[Contact our Ph.D. Support Team for a compatibility check](#)]

**Need Industrial/Bulk Grade?** [Request Custom Synthesis Quote](#)

## BenchChem

Our mission is to be the trusted global source of essential and advanced chemicals, empowering scientists and researchers to drive progress in science and industry.

### Contact

Address: 3281 E Guasti Rd  
Ontario, CA 91761, United States  
Phone: (601) 213-4426  
Email: [info@benchchem.com](mailto:info@benchchem.com)