

Technical Support Center: PSMA-IN-2 PET Imaging

Author: BenchChem Technical Support Team. **Date:** December 2025

Compound of Interest

Compound Name: *Psma-IN-2*

Cat. No.: *B15613848*

[Get Quote](#)

Disclaimer: No specific information could be found for a PET imaging agent named "**PSMA-IN-2**" in the reviewed literature. The following troubleshooting guides and FAQs have been created based on extensive data available for widely studied and clinically utilized PSMA-targeting radiotracers such as 68Ga-PSMA-11, 18F-DCFPyL, and 68Ga-PSMA-I&T. The principles and guidance provided are broadly applicable to PSMA PET imaging in general and should serve as a valuable resource for researchers, scientists, and drug development professionals.

Troubleshooting Guide

This guide addresses specific issues that users might encounter during PSMA PET imaging experiments.

Issue/Question	Potential Cause(s)	Recommended Action(s)
1. High background noise or poor tumor-to-background ratio.	- Inadequate uptake time. - Suboptimal radiotracer dose. - Patient-specific factors (e.g., impaired renal clearance).	- Ensure adequate uptake time as per protocol (typically 60-120 minutes post-injection). - Verify the injected dose is within the recommended range. - Encourage patient hydration to promote urinary clearance of unbound tracer.
2. Intense uptake in non-prostatic tissues leading to potential false positives.	- Physiological Biodistribution: PSMA is expressed in various normal tissues.[1] - Inflammatory Processes: Inflammation can lead to increased PSMA uptake.[2] - Benign Conditions: Benign prostatic hyperplasia (BPH), prostatitis, and certain bone conditions (e.g., fractures, Paget's disease) can show PSMA avidity.[2]	- Familiarize with the normal biodistribution of the specific PSMA tracer being used.[1] - Correlate PET findings with anatomical imaging (CT or MRI) to assess for morphological changes indicative of benign or inflammatory conditions. - Review patient history for recent trauma, inflammation, or other malignancies.
3. "Halo artifact" observed around areas of intense activity (e.g., bladder, kidneys).	- High concentration of the radiotracer in the urinary system.[2] - Inaccurate scatter correction algorithms during image reconstruction, especially in PET/MRI.	- Administer a diuretic (e.g., furosemide) to promote clearance of the tracer from the urinary tract, if clinically appropriate.[3] - Utilize advanced scatter correction methods during image reconstruction. - Optimize imaging protocols to minimize the impact of high count rates.
4. Focal lung uptake without a corresponding CT lesion.	- This can be a rare artifact, potentially due to the formation and trapping of tracer-	- This finding should be interpreted with caution and documented as a potential artifact to avoid misdiagnosis.

concentrating micro-clots in the pulmonary microcirculation.[4]

[4] - Clinical correlation and follow-up imaging may be warranted.

5. Low or no tumor uptake in a patient with confirmed prostate cancer.

- PSMA-negative tumors: A subset of prostate cancers (~5-10%) may not express PSMA.
[2] - Recent Androgen Deprivation Therapy (ADT): New onset of ADT can decrease PSMA expression and tracer uptake.[3] - Small lesion size: Microscopic or very small lesions may be below the resolution limit of the PET scanner.

- Consider alternative imaging modalities (e.g., FDG PET/CT, choline PET/CT) if PSMA-negative disease is suspected.
- Whenever possible, perform PSMA PET/CT before initiating new ADT.[3] - Acknowledge the limitations of PET in detecting micrometastases.

Frequently Asked Questions (FAQs)

Q1: What is the typical biodistribution of PSMA radiotracers in the body?

A1: PSMA radiotracers exhibit a characteristic biodistribution pattern. High physiological uptake is typically observed in the lacrimal and salivary glands, liver, spleen, small intestine (especially the duodenum), kidneys, and urinary bladder due to renal excretion.[1][5] Understanding this normal distribution is crucial to differentiate physiological uptake from pathological findings.

Q2: Can PSMA PET be used to image other cancers besides prostate cancer?

A2: Yes, while PSMA is highly overexpressed in prostate cancer, its expression has also been noted in the neovasculature of other solid tumors, such as renal cell carcinoma and thyroid cancer.[1] This can be a source of potential false-positive findings when imaging prostate cancer patients but also opens avenues for PSMA-targeted imaging and therapy in other malignancies.

Q3: How does patient preparation affect the quality of a PSMA PET scan?

A3: Proper patient preparation is key to obtaining high-quality images. Patients are typically advised to be well-hydrated to facilitate the clearance of the radiotracer and reduce radiation dose to the bladder. Fasting is generally not required.[3] For tracers with high urinary excretion, a diuretic may be administered to reduce artifacts.[3]

Q4: What are the key quantitative parameters used in PSMA PET imaging?

A4: Quantitative analysis of PSMA PET images provides objective measures of tracer uptake. The most common parameter is the Standardized Uptake Value (SUV), particularly SUVmax (the maximum pixel value in a region of interest) and SUVmean (the average pixel value). Other advanced metrics include PSMA-expressing tumor volume (PSMA-TV) and total lesion PSMA (TL-PSMA), which is the product of PSMA-TV and SUVmean. These quantitative values can be used to assess tumor burden and response to therapy.

Q5: Are there standardized protocols for PSMA PET/CT imaging?

A5: Yes, joint procedure guidelines have been published by major nuclear medicine societies like the European Association of Nuclear Medicine (EANM) and the Society of Nuclear Medicine and Molecular Imaging (SNMMI).[3] These guidelines provide recommendations on patient selection, radiopharmaceutical administration, image acquisition protocols, and interpretation criteria to promote standardization and ensure high-quality imaging across different centers.

Experimental Protocols

General PSMA PET/CT Imaging Protocol

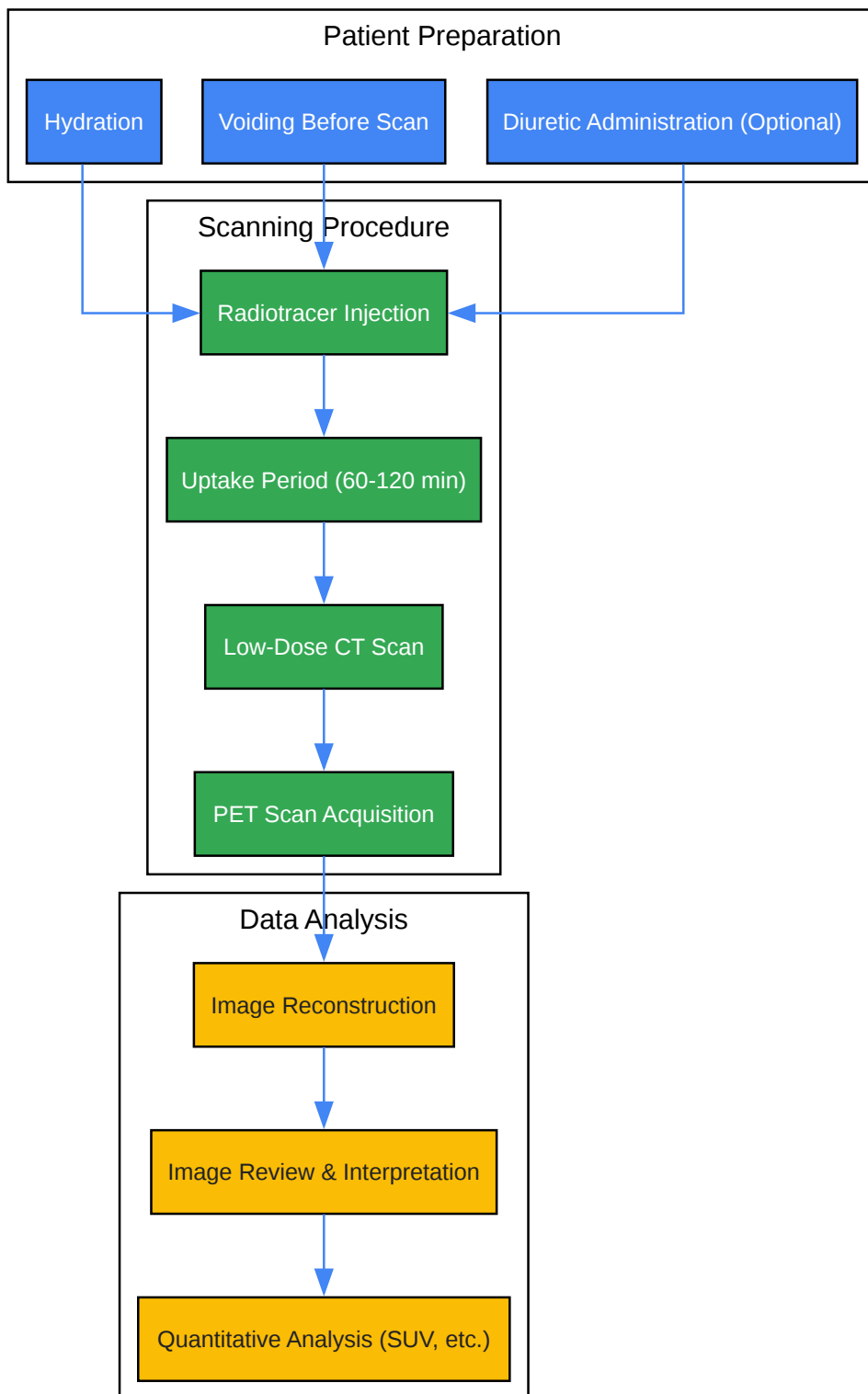
This protocol is a generalized procedure based on common practices with ⁶⁸Ga-labeled PSMA ligands. Specific parameters may vary depending on the tracer, equipment, and institutional guidelines.

- Patient Preparation:
 - No fasting is required.
 - Patients should be well-hydrated. Encourage drinking approximately 1 liter of water before the scan.

- Have the patient void immediately before image acquisition to minimize bladder activity.
- Consider intravenous administration of a diuretic (e.g., 20 mg furosemide) at the time of tracer injection to enhance urinary clearance, especially if imaging the pelvic region is critical.^[3]
- Radiotracer Administration:
 - Administer approximately 1.8-2.2 MBq/kg (0.04-0.06 mCi/kg) of the ⁶⁸Ga-PSMA radiotracer intravenously.
 - The injection should be followed by a saline flush.
- Uptake Period:
 - The patient should rest for an uptake period of 60 to 120 minutes.
- Image Acquisition:
 - CT Scan: Perform a low-dose CT scan for attenuation correction and anatomical localization. A diagnostic-quality contrast-enhanced CT can be performed if clinically indicated.
 - PET Scan: Acquire PET data from the vertex of the skull to the mid-thigh.
 - Acquisition time is typically 2-4 minutes per bed position.
 - Ensure sufficient overlap between bed positions.
- Image Reconstruction:
 - Reconstruct PET images using an iterative algorithm (e.g., OSEM - Ordered Subsets Expectation Maximization).
 - Apply corrections for attenuation (using the CT data), scatter, and random coincidences.

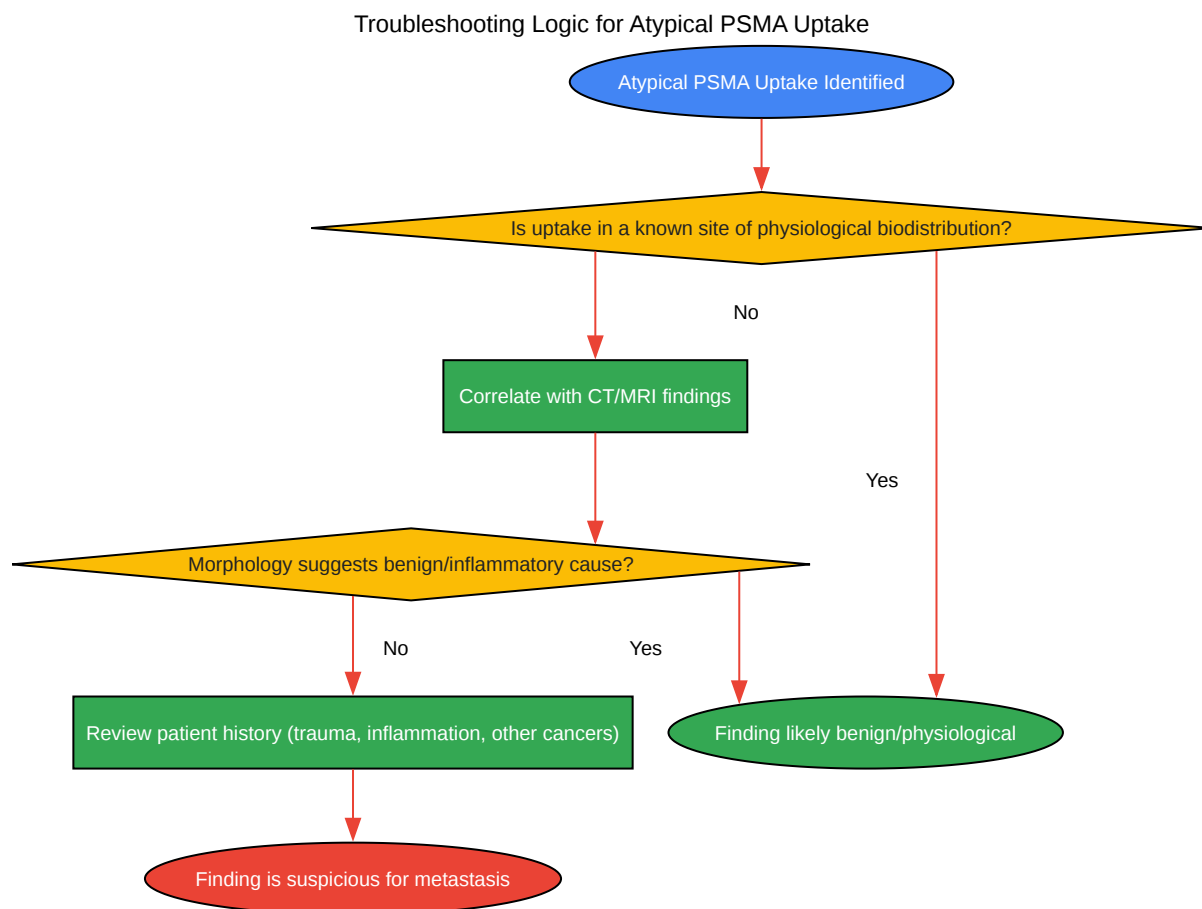
Visualizations

PSMA PET/CT Experimental Workflow



[Click to download full resolution via product page](#)

Caption: A flowchart of the general experimental workflow for PSMA PET/CT imaging.



[Click to download full resolution via product page](#)

Caption: A decision-making diagram for troubleshooting atypical PSMA uptake.

Need Custom Synthesis?

BenchChem offers custom synthesis for rare earth carbides and specific isotopic labeling.

Email: info@benchchem.com or [Request Quote Online](#).

References

- 1. radiopaedia.org [radiopaedia.org]
- 2. Frontiers | Normal Variants, Pitfalls, and Artifacts in Ga-68 Prostate Specific Membrane Antigen (PSMA) PET/CT Imaging [frontiersin.org]
- 3. snmmi.org [snmmi.org]
- 4. All that Glitters on PSMA is Not a Lesion: An Unusual Artifact on PSMA PET/CT - PMC [pmc.ncbi.nlm.nih.gov]
- 5. Physiological biodistribution on Ga68-PSMA PET/CT and the factors effecting biodistribution - PMC [pmc.ncbi.nlm.nih.gov]
- To cite this document: BenchChem. [Technical Support Center: PSMA-IN-2 PET Imaging]. BenchChem, [2025]. [Online PDF]. Available at: [https://www.benchchem.com/product/b15613848#artifacts-in-pet-imaging-with-psma-in-2]

Disclaimer & Data Validity:

The information provided in this document is for Research Use Only (RUO) and is strictly not intended for diagnostic or therapeutic procedures. While BenchChem strives to provide accurate protocols, we make no warranties, express or implied, regarding the fitness of this product for every specific experimental setup.

Technical Support: The protocols provided are for reference purposes. Unsure if this reagent suits your experiment? [[Contact our Ph.D. Support Team for a compatibility check](#)]

Need Industrial/Bulk Grade? [Request Custom Synthesis Quote](#)

BenchChem

Our mission is to be the trusted global source of essential and advanced chemicals, empowering scientists and researchers to drive progress in science and industry.

Contact

Address: 3281 E Guasti Rd
Ontario, CA 91761, United States
Phone: (601) 213-4426
Email: info@benchchem.com