

Technical Support Center: Overcoming Limitations in Radiographic Detection of Chondrocalcinosis

Author: BenchChem Technical Support Team. **Date:** December 2025

Compound of Interest

Compound Name: Calcium pyrophosphate

Cat. No.: B7822615

[Get Quote](#)

Welcome to the Technical Support Center. This resource is designed for researchers, scientists, and drug development professionals investigating chondrocalcinosis, the deposition of **calcium pyrophosphate** dihydrate (CPPD) crystals in articular cartilage. Here you will find troubleshooting guides and frequently asked questions (FAQs) to address specific issues you may encounter during your experiments, with a focus on advanced imaging techniques that surpass the limitations of conventional radiography.

Frequently Asked Questions (FAQs)

Q1: What are the primary limitations of conventional radiography for detecting chondrocalcinosis?

Conventional radiography is often the first-line imaging modality for suspected chondrocalcinosis due to its wide availability and low cost. However, it has significant limitations:

- **Low Sensitivity:** Radiography may not detect early or small-volume crystal deposits, leading to false negatives. Its sensitivity is particularly low in early-stage disease.
- **Lack of Specificity:** The term "chondrocalcinosis" is descriptive for cartilage calcification and is not exclusive to CPPD. Other conditions, such as osteoarthritis and basic calcium

phosphate (BCP) crystal deposition, can also present with cartilage calcification on radiographs.

- **Superimposition of Structures:** The two-dimensional nature of radiographs can lead to the superimposition of bony structures, obscuring subtle calcifications within the cartilage.
- **Difficulty in Quantifying Crystal Burden:** It is challenging to accurately quantify the volume and distribution of crystal deposits using conventional radiography.

Q2: Which advanced imaging modalities offer higher sensitivity for chondrocalcinosis detection?

Several advanced imaging techniques have demonstrated superior sensitivity compared to conventional radiography for detecting chondrocalcinosis:

- **Musculoskeletal Ultrasound (MSKUS):** A non-invasive, real-time imaging modality that can visualize crystal deposits in hyaline cartilage, fibrocartilage, and synovial tissue with high resolution.
- **Computed Tomography (CT):** Provides detailed cross-sectional images, allowing for excellent visualization and localization of calcifications, even in complex joints.
- **Dual-Energy Computed Tomography (DECT):** A specialized CT technique that can differentiate between different types of calcium crystals, such as CPPD and monosodium urate (gout).
- **Magnetic Resonance Imaging (MRI),** especially at high field strengths (e.g., 7-Tesla): While conventional MRI has limitations in directly visualizing calcifications, advanced sequences and high-field magnets can detect cartilage abnormalities associated with crystal deposition and may even visualize the deposits as signal voids.^{[1][2][3]}

Troubleshooting Guides

Musculoskeletal Ultrasound (MSKUS)

Q: I am seeing hyperechoic foci in the cartilage that I suspect are CPPD crystals, but I'm unsure if they are artifacts. How can I differentiate?

A: This is a common challenge. Here's a troubleshooting guide to distinguish true crystal deposits from common artifacts:

Observation/Artifact	Potential Cause	Troubleshooting Steps & Solutions
Anisotropy	The ultrasound beam is not perpendicular to the fibrillar structure of the cartilage or tendons, causing a hypoechoic appearance that can mimic pathology. [4] [5]	Solution: Carefully tilt or "heel-toe" the transducer to ensure the ultrasound beam is perpendicular to the tissue of interest. True hyperechoic crystal deposits will remain visible, while anisotropy will resolve.
Reverberation Artifact	The ultrasound beam bounces between two highly reflective surfaces (e.g., the transducer and bone), creating multiple, equally spaced linear echoes. [4] [5]	Solution: Adjust the transducer position and angle. Changing the imaging window can often mitigate this artifact. Reducing the gain in the far field may also help.
Acoustic Shadowing	Highly attenuating structures like large calcifications or bone block the ultrasound beam, creating a dark area behind them. [4] [6]	Solution: While this can be a helpful sign of calcification, to visualize structures within the shadow, try imaging from a different angle (compounding).
Enhancement Artifact	Fluid-filled structures (e.g., cysts) cause less attenuation of the ultrasound beam, leading to a brighter appearance of the tissue behind them. [5] [6]	Solution: Be aware of this effect when interpreting the echogenicity of tissues deep to fluid collections. Adjusting the time-gain compensation (TGC) can help to create a more uniform image brightness.

Dual-Energy Computed Tomography (DECT)

Q: My DECT scans are showing artifacts that make it difficult to differentiate between CPPD and other calcifications. How can I optimize my protocol?

A: DECT is a powerful tool, but proper protocol and post-processing are crucial. Here are some common issues and solutions:

Observation/Artifact	Potential Cause	Troubleshooting Steps & Solutions
Beam Hardening Artifacts	The preferential absorption of lower-energy X-rays as the beam passes through dense tissue (like bone) can lead to dark streaks or bands that can obscure or mimic crystal deposits.	Solution: Utilize iterative reconstruction algorithms if available. Ensure proper patient positioning to minimize the X-ray path through dense bone. Post-processing software can also help to correct for beam hardening.
Motion Artifacts	Patient movement during the scan can cause blurring and misregistration of the dual-energy images.	Solution: Immobilize the joint being scanned as much as possible. Use the fastest possible scan time. Some software can perform motion correction during post-processing.
Incorrect Material Differentiation	The software is not correctly color-coding the CPPD crystals.	Solution: Ensure you are using the correct material decomposition algorithm for calcium crystals. Unlike gout protocols which are well-established for monosodium urate, CPPD differentiation is more nuanced. You may need to manually adjust the Hounsfield Unit (HU) thresholds for calcium pyrophosphate based on phantom studies or published literature.

Data Presentation: Comparison of Imaging Modalities

The following table summarizes the diagnostic performance of various imaging modalities for the detection of chondrocalcinosis, with synovial fluid analysis or histology often serving as the reference standard.

Imaging Modality	Sensitivity	Specificity	Key Advantages	Key Disadvantages
Conventional Radiography	13.2% - 83.7% ^[7]	~93% - 100% ^[7]	Widely available, low cost.	Low sensitivity, especially in early disease; operator dependent.
Musculoskeletal Ultrasound (MSKUS)	59.5% - 96% ^[7]	87% - 100% ^[7]	High resolution, real-time, non-ionizing radiation, can guide aspiration.	Highly operator-dependent, limited penetration in deep joints.
Computed Tomography (CT)	~72% ^[8]	-	Excellent spatial resolution, good for complex anatomy.	Higher radiation dose than radiography, artifacts can be an issue.
Dual-Energy CT (DECT)	~55% - 90%	~92%	Can differentiate crystal types (e.g., CPPD vs. MSU).	Still an emerging technique for CPPD, potential for artifacts.
3-Tesla MRI	93.2% - 95.9% ^{[1][2][3]}	~100% ^[2]	Excellent soft tissue contrast, can detect associated pathology.	Indirect visualization of crystals, potential for signal void misinterpretation.
7-Tesla MRI	100% ^{[1][2][3]}	~85.7% ^[2]	Very high resolution, improved visualization of cartilage and small deposits. ^{[1][2][3][9]}	Limited availability, higher cost, potential for more pronounced artifacts.

Experimental Protocols

Protocol 1: Ultrasound-Guided Arthrocentesis and Synovial Fluid Analysis

This protocol outlines the steps for obtaining synovial fluid for crystal analysis under ultrasound guidance, the gold standard for definitive diagnosis.

- **Patient Preparation:** Position the patient comfortably to allow access to the target joint. Prepare the skin over the joint using a sterile technique with an antiseptic solution.
- **Ultrasound Imaging:**
 - Use a high-frequency linear transducer (e.g., 10-18 MHz).
 - Apply sterile ultrasound gel and a sterile probe cover.
 - Identify the joint space and any effusion. Use Doppler imaging to identify and avoid blood vessels.
- **Anesthesia:** Infiltrate a local anesthetic (e.g., 1% lidocaine) into the skin and subcutaneous tissue down to the joint capsule.
- **Aspiration:**
 - Under real-time ultrasound guidance, insert a sterile needle (e.g., 18-22 gauge) into the joint space.
 - Aspirate the synovial fluid into a syringe.[\[10\]](#)[\[11\]](#)[\[12\]](#)[\[13\]](#)[\[14\]](#)
- **Synovial Fluid Analysis:**
 - Place a drop of the synovial fluid on a clean glass slide and cover with a coverslip.
 - Examine the slide using a polarized light microscope.
 - CPPD crystals are typically rhomboid-shaped and show weak positive birefringence.

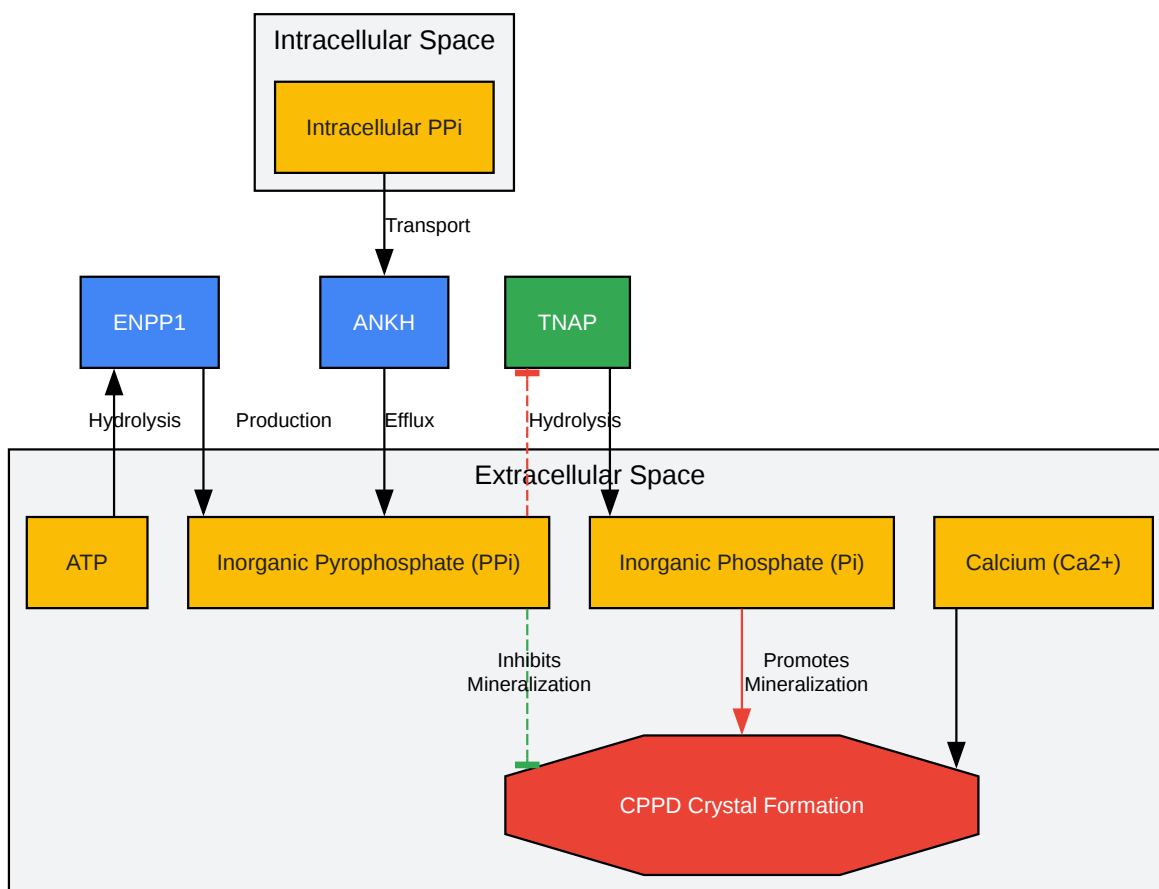
Protocol 2: Histological Staining of CPPD Crystals with Alizarin Red S

This protocol is for the histological identification of calcium deposits in paraffin-embedded tissue sections. Alizarin Red S staining is preferred over standard H&E for preserving CPPD crystals.^{[15][16]}

- Deparaffinization and Rehydration:
 - Deparaffinize tissue sections in xylene.
 - Rehydrate through a graded series of ethanol to distilled water.
- Staining Solution Preparation:
 - Prepare a 1% Alizarin Red S solution in distilled water.
 - Adjust the pH to 6.4 by adding 0.1% ammonia solution dropwise while stirring.^[15]
- Staining Procedure:
 - Immerse the slides in the Alizarin Red S solution for 2-5 minutes. Monitor the staining progress microscopically.
 - Shake off excess dye and blot the sections.
- Dehydration and Mounting:
 - Dehydrate the sections quickly in acetone, followed by an acetone-xylene mixture.
 - Clear in xylene and mount with a synthetic mounting medium.^[17]
- Microscopy: Examine the slides under a bright-field and polarized light microscope. Calcium deposits will appear as red-orange precipitates.

Visualizations

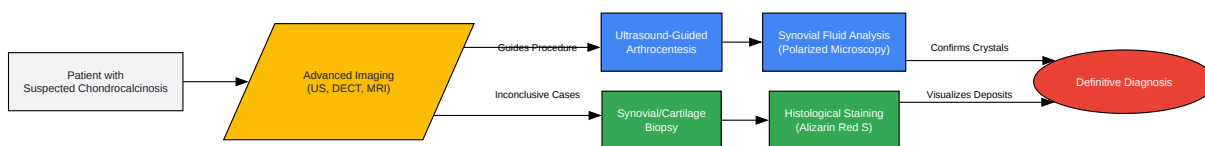
Signaling Pathway in Chondrocalcinosis



[Click to download full resolution via product page](#)

Caption: Pyrophosphate metabolism and its role in chondrocalcinosis.

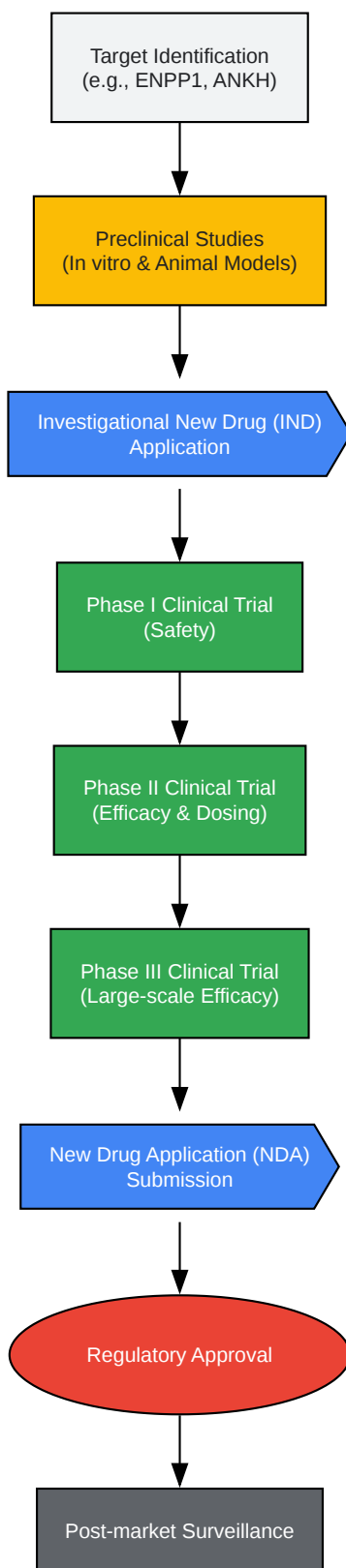
Experimental Workflow: From Patient to Diagnosis



[Click to download full resolution via product page](#)

Caption: Diagnostic workflow for chondrocalcinosis.

Drug Development Pipeline for Chondrocalcinosis



[Click to download full resolution via product page](#)

Caption: Drug development process for chondrocalcinosis therapies.

Need Custom Synthesis?

BenchChem offers custom synthesis for rare earth carbides and specific isotopic labeling.

Email: info@benchchem.com or [Request Quote Online](#).

References

- 1. researchgate.net [researchgate.net]
- 2. Ultra-high resolution 3D MRI for chondrocalcinosis detection in the knee—a prospective diagnostic accuracy study comparing 7-tesla and 3-tesla MRI with CT - PMC [pmc.ncbi.nlm.nih.gov]
- 3. d-nb.info [d-nb.info]
- 4. Musculoskeletal Ultrasound: Understanding Common Artifacts - Gulfcoast Ultrasound News Blog [gcus.com]
- 5. mdpi.com [mdpi.com]
- 6. Musculoskeletal Ultrasound Artifacts | Radiology Key [radiologykey.com]
- 7. Imaging of Calcium Pyrophosphate Deposition Disease - PMC [pmc.ncbi.nlm.nih.gov]
- 8. Comparison of three imaging techniques in diagnosis of chondrocalcinosis of the knees in calcium pyrophosphate deposition disease - PubMed [pubmed.ncbi.nlm.nih.gov]
- 9. 7-Tesla MRI Evaluation of the Knee, 25 Years after Cartilage Repair Surgery: The Influence of Intralesional Osteophytes on Biochemical Quality of Cartilage - PMC [pmc.ncbi.nlm.nih.gov]
- 10. cdn.mdedge.com [cdn.mdedge.com]
- 11. Ultrasound-Guided Arthrocentesis - StatPearls - NCBI Bookshelf [ncbi.nlm.nih.gov]
- 12. radiopaedia.org [radiopaedia.org]
- 13. Synovial Fluid Analysis - StatPearls - NCBI Bookshelf [ncbi.nlm.nih.gov]
- 14. ultrasoundleadershipacademy.com [ultrasoundleadershipacademy.com]
- 15. The utility of alizarin red s staining in calcium pyrophosphate dihydrate crystal deposition disease - PubMed [pubmed.ncbi.nlm.nih.gov]
- 16. researchgate.net [researchgate.net]
- 17. researchgate.net [researchgate.net]

- To cite this document: BenchChem. [Technical Support Center: Overcoming Limitations in Radiographic Detection of Chondrocalcinosis]. BenchChem, [2025]. [Online PDF]. Available at: [\[https://www.benchchem.com/product/b7822615#overcoming-limitations-of-radiographic-detection-of-chondrocalcinosis\]](https://www.benchchem.com/product/b7822615#overcoming-limitations-of-radiographic-detection-of-chondrocalcinosis)

Disclaimer & Data Validity:

The information provided in this document is for Research Use Only (RUO) and is strictly not intended for diagnostic or therapeutic procedures. While BenchChem strives to provide accurate protocols, we make no warranties, express or implied, regarding the fitness of this product for every specific experimental setup.

Technical Support: The protocols provided are for reference purposes. Unsure if this reagent suits your experiment? [[Contact our Ph.D. Support Team for a compatibility check](#)]

Need Industrial/Bulk Grade? [Request Custom Synthesis Quote](#)

BenchChem

Our mission is to be the trusted global source of essential and advanced chemicals, empowering scientists and researchers to drive progress in science and industry.

Contact

Address: 3281 E Guasti Rd
Ontario, CA 91761, United States
Phone: (601) 213-4426
Email: info@benchchem.com