

# Technical Support Center: Overcoming Challenges in HYNIC-iPSMA Image Interpretation

**Author:** BenchChem Technical Support Team. **Date:** December 2025

## Compound of Interest

Compound Name: HYNIC-iPSMA

Cat. No.: B12390982

[Get Quote](#)

This technical support center provides troubleshooting guides and frequently asked questions (FAQs) to assist researchers, scientists, and drug development professionals in accurately interpreting **HYNIC-iPSMA** SPECT/CT images.

## Section 1: Frequently Asked Questions (FAQs)

Q1: What is the typical biodistribution of 99mTc-**HYNIC-iPSMA** in a normal scan?

A1: Normal physiologic biodistribution of [<sup>99m</sup>Tc]Tc-**HYNIC-iPSMA** shows high uptake in the kidneys, salivary glands (parotid and submandibular), lacrimal glands, liver, spleen, and intestines.[1] The urinary bladder will also show high activity due to renal excretion of the radiotracer.[1]

Q2: What is the optimal imaging time post-injection of 99mTc-**HYNIC-iPSMA**?

A2: Imaging is typically performed 2 to 4 hours after the intravenous administration of the radiotracer.[1][2] This time frame allows for sufficient tumor uptake and clearance from background tissues, leading to improved image contrast. In some cases, imaging at 4 hours post-injection can lead to greater urinary clearance, which may improve visualization of the prostate or prostate bed.

Q3: What is the recommended patient preparation protocol before a 99mTc-**HYNIC-iPSMA** scan?

A3: Patients should be well-hydrated. Intravenous hydration with 500 mL of sodium chloride may be administered.[3] Forced diuresis with furosemide (e.g., 20 mg intravenously) administered shortly after the radiotracer injection can significantly reduce urinary bladder activity, which may otherwise obscure pelvic lesions.

Q4: Can 99mTc-**HYNIC-iPSMA** be used to quantify PSMA expression?

A4: Yes, semi-quantitative analysis using Standardized Uptake Values (SUV) or Tumor-to-Background Ratios (TBR) can be performed to estimate PSMA expression. However, it is important to note that SPECT-based SUV calculations require careful calibration and may not be as standardized as PET-based measurements. TBR is often a more practical and robust metric for SPECT imaging.

## Section 2: Troubleshooting Guide for Image Interpretation

This guide addresses common challenges encountered during the interpretation of 99mTc-**HYNIC-iPSMA** SPECT/CT images.

Challenge/Artifact	Question	Possible Cause(s)	Troubleshooting/Interpretation Strategy
High Urinary Activity	How can I differentiate a metastatic pelvic lymph node from physiologic ureter activity?	Due to the renal excretion route of <sup>99m</sup> Tc-HYNIC-iPSMA, tracer accumulation in the ureters can mimic lymph node metastases.	<p>- Carefully examine the fused SPECT/CT images to trace the path of the ureters from the renal pelvis to the bladder.</p> <p>Ureteral activity will appear linear and continuous, following the anatomical course of the ureter. - A CT urogram can be performed for definitive localization if ambiguity persists. - Delayed imaging after hydration and diuresis may show movement or clearance of the activity if it is within the ureter.</p>
High Bladder Activity	How can intense bladder activity obscuring the prostate/prostate bed be managed?	Significant accumulation of the radiotracer in the bladder is a common finding due to urinary excretion.	<p>- Administer a diuretic (e.g., furosemide) after tracer injection and encourage the patient to void immediately before imaging. - Adequate patient hydration is crucial. - Acquiring images at a later time point (e.g., 4 hours) may allow for further bladder emptying.</p>

Bowel Activity	How can I distinguish between physiologic bowel uptake and abdominal metastases?	99mTc-HYNIC-iPSMA can show variable physiologic uptake in the intestines.	<ul style="list-style-type: none"><li>- Correlate the SPECT findings with the anatomical location on the CT scan.</li><li>Physiologic uptake will conform to the shape and location of the bowel loops.</li><li>- Delayed imaging can be helpful, as the distribution of physiologic bowel activity may change over time, whereas metastatic lesions will remain fixed.</li></ul>
Uptake in Sympathetic Ganglia	Can sympathetic ganglia show uptake and be mistaken for lymph node metastases?	Yes, sympathetic ganglia, such as the celiac or stellate ganglia, can demonstrate low-grade uptake on PSMA-targeted imaging and may be misinterpreted as metastatic lymph nodes.	<ul style="list-style-type: none"><li>- Knowledge of the typical anatomical locations of sympathetic ganglia is essential.</li><li>- The uptake in ganglia is usually of lower intensity compared to malignant lesions.</li><li>- The shape of ganglia is often elongated or stellate, which can be distinguished from the more rounded appearance of lymph nodes on CT.</li></ul>
Free Pertechnetate	What does uptake in the thyroid, salivary glands, and stomach indicate?	This pattern of uptake suggests the presence of free, unbound <sup>99m</sup> Tc-	<ul style="list-style-type: none"><li>- Review the radiochemical purity results from the quality control of the</li></ul>

pertechnetate, which can result from radiopharmaceutical preparation failure or in vivo dechelation.

radiopharmaceutical. It should be >95%. - While high salivary gland uptake is a normal physiological finding with HYNIC-iPSMA, intense and concurrent uptake in the thyroid and stomach is indicative of free pertechnetate and may compromise image quality and interpretation.

## Section 3: Quantitative Data

The following tables summarize semi-quantitative uptake values for 99mTc-**HYNIC-iPSMA** in various tissues. Note that these values can vary depending on the patient, imaging protocol, and quantification method.

Table 1: SUVmax and TBR in Normal Organs and Lesions from a Comparative Study with <sup>68</sup>Ga-PSMA-11 PET/CT

Organ/Lesion	SUVmax (Mean ± SD)	TBR (Mean ± SD)
Kidney	45.6 ± 3.4	35.6 ± 27.3
Parotid Gland	19.5 ± 2.4	53.7 ± 37.47
Bladder	28.5 ± 4.2	7.0 ± 10.7
Prostate Lesion	25.2 ± 4.7	35.9 ± 45.2
Bone Metastasis	18.4 ± 1.6	15.4 ± 18.9
Lymph Node Metastasis	11.4 ± 1.2	19.1 ± 51.7

Table 2: Detection Rates and SUVmax of 99mTc-**HYNIC-iPSMA** in Recurrent Prostate Cancer

PSA Level (ng/mL)	Detection Rate (%)
>0.2 - 2	48.6%
>2 - 5	85.1%
>5 - 10	92.1%
>10	96.3%

A significant positive correlation has been observed between PSA levels and the SUVmax of detected lesions. A tumor-to-background ratio of  $9.42 \pm 2.62$  has also been reported in malignant lesions.

## Section 4: Experimental Protocols

### Radiolabeling of HYNIC-iPSMA with $^{99m}\text{Tc}$

This protocol is a generalized procedure based on published methods. Researchers should always refer to the specific instructions provided with their radiolabeling kits.

- Reconstitution of the Kit:
  - To a sterile vial containing the lyophilized **HYNIC-iPSMA**, add 1.0 mL of 0.2 M phosphate buffer (pH 7.0).
- Addition of  $^{99m}\text{Tc}$ :
  - Immediately add 555-740 MBq (15-20 mCi) of sterile  $^{99m}\text{Tc}$ -pertechnetate to the vial.
- Incubation:
  - Incubate the reaction mixture in a block heater or boiling water bath at 95-100°C for 15-20 minutes.
- Cooling:
  - Allow the vial to cool to room temperature before proceeding with quality control.

## Quality Control

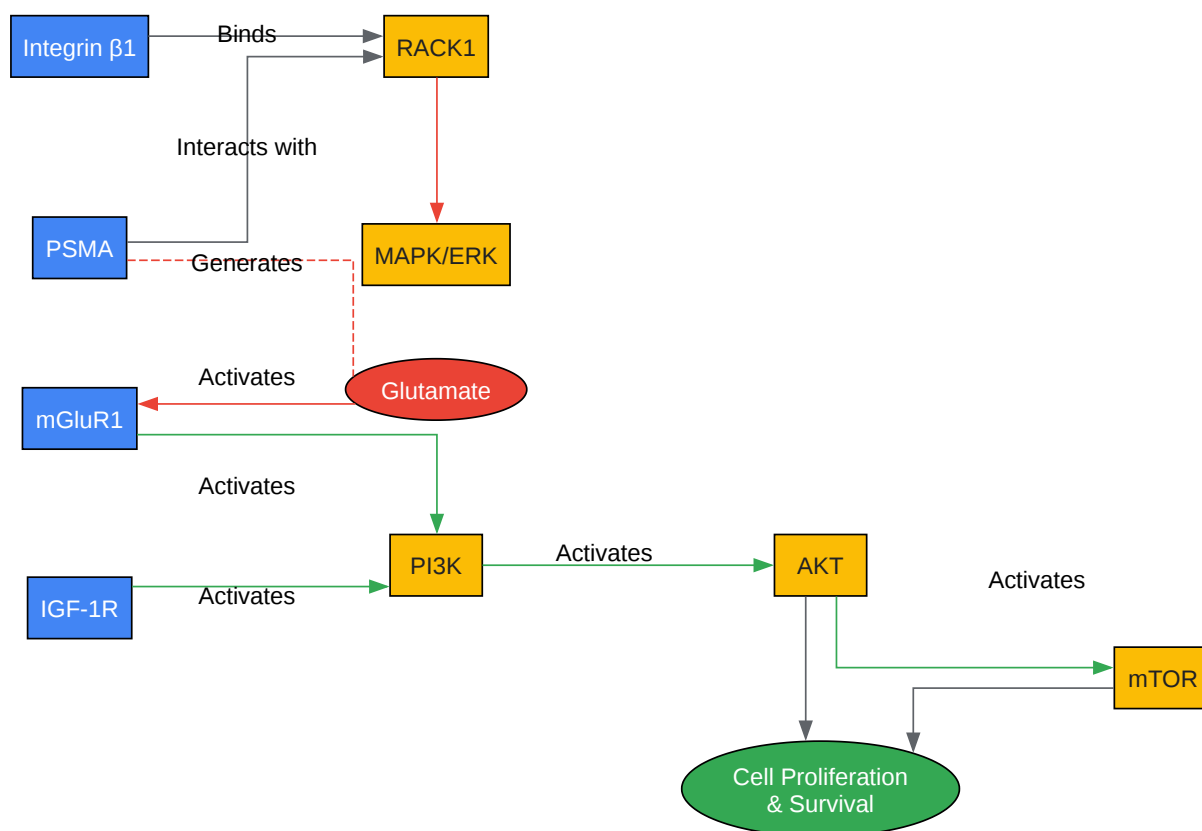
- Radiochemical Purity (RCP):
  - RCP should be determined using instant thin-layer chromatography (ITLC) or high-performance liquid chromatography (HPLC).
  - The RCP should be greater than 95%.

## Imaging Protocol

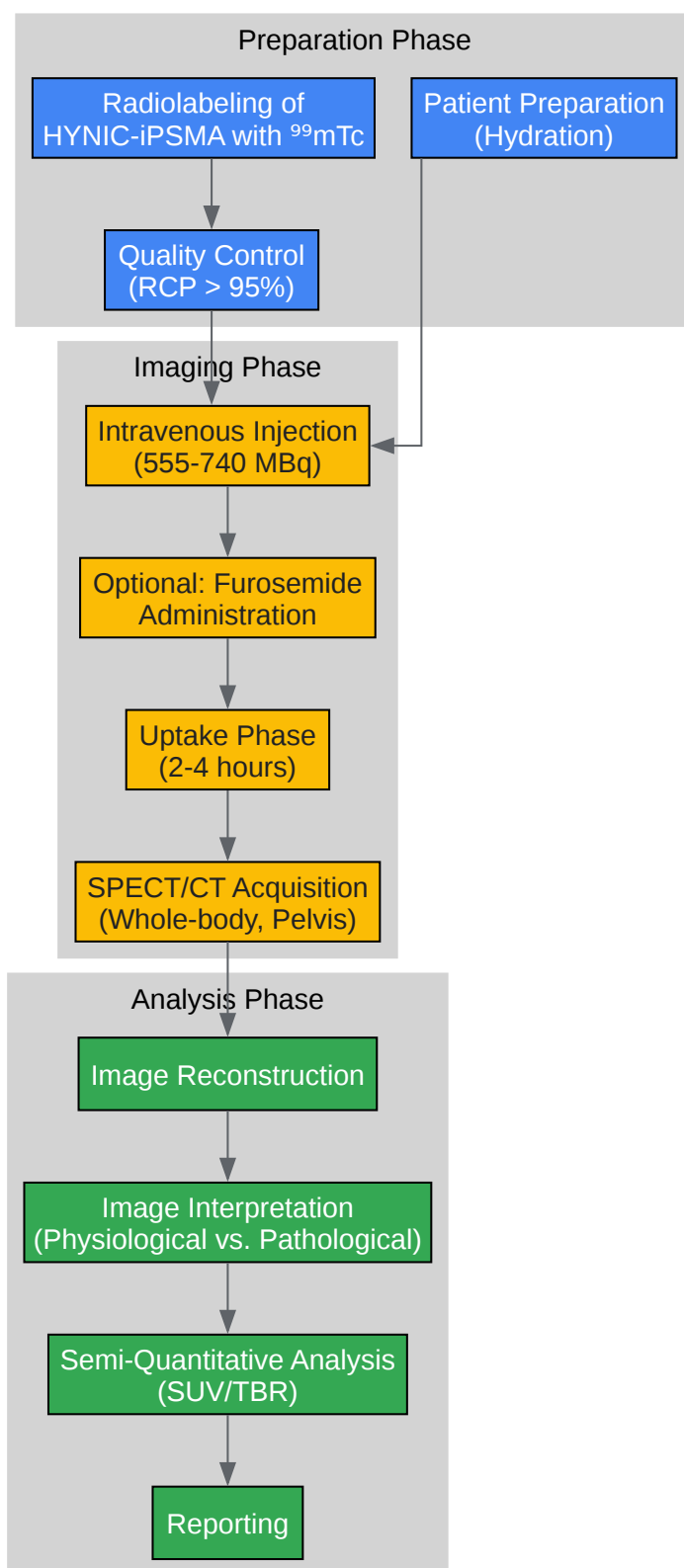
- Patient Preparation:
  - Ensure the patient is well-hydrated.
  - Consider the administration of a diuretic (e.g., 20 mg furosemide IV) after radiotracer injection to promote urinary clearance.
- Radiotracer Administration:
  - Administer 555-740 MBq (15-20 mCi) of <sup>99m</sup>Tc-**HYNIC-iPSMA** intravenously.
- Image Acquisition:
  - Acquire whole-body planar and SPECT/CT images 2-4 hours post-injection.
  - SPECT/CT should cover the chest, abdomen, and pelvis.

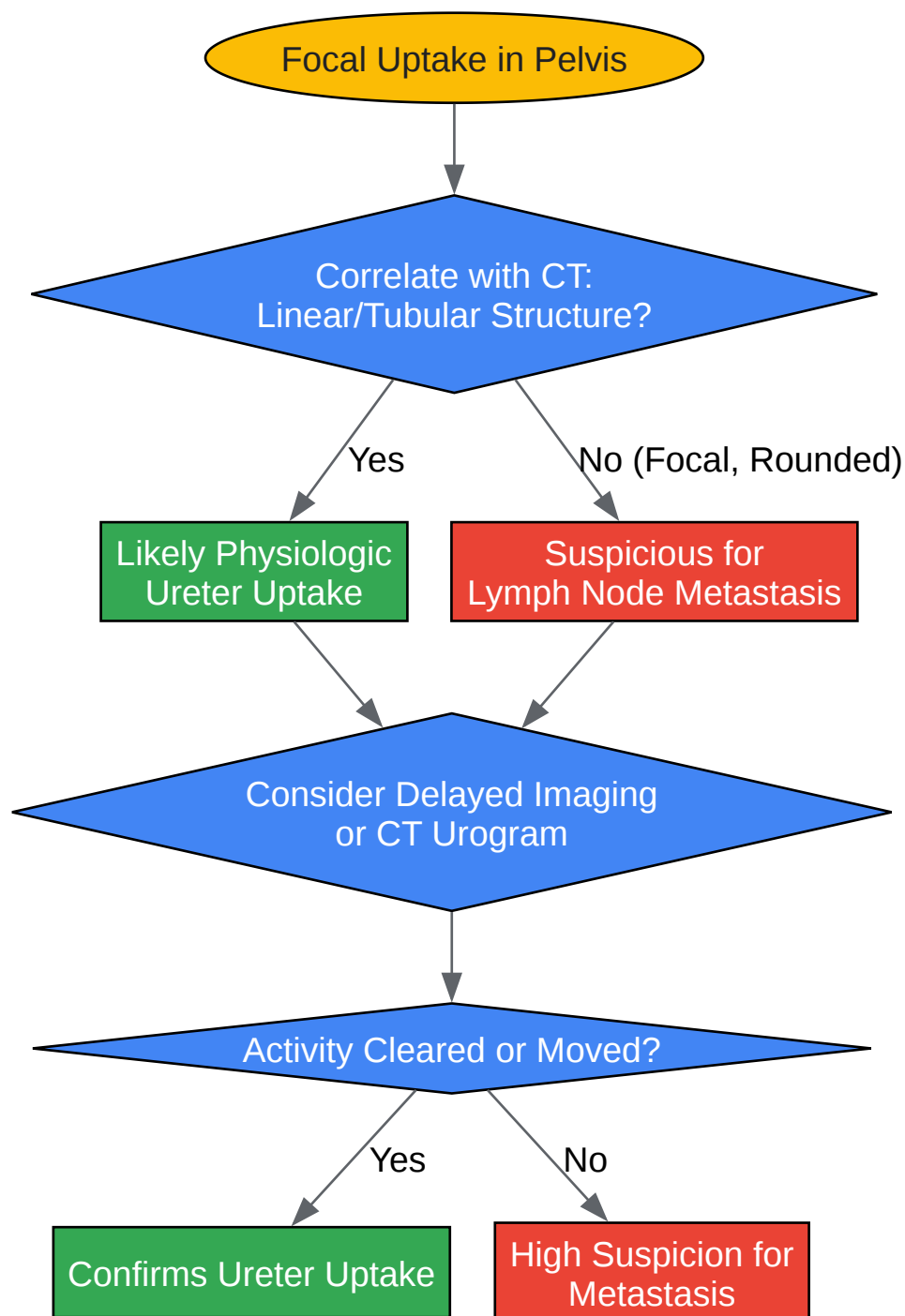
## Section 5: Visualizations

### PSMA Signaling Pathway









[Click to download full resolution via product page](#)

#### Need Custom Synthesis?

BenchChem offers custom synthesis for rare earth carbides and specific isotopic labeling.

Email: [info@benchchem.com](mailto:info@benchchem.com) or [Request Quote Online](#).

## References

- 1. Real world experience with [99mTc]Tc-HYNIC-iPSMA SPECT prostate cancer detection: interim results from the global NOBLE registry - PMC [pmc.ncbi.nlm.nih.gov]
- 2. researchoutput.csu.edu.au [researchoutput.csu.edu.au]
- 3. Impact of forced diuresis with furosemide and hydration on the halo artefact and intensity of tracer accumulation in the urinary bladder and kidneys on [68Ga]Ga-PSMA-11-PET/CT in the evaluation of prostate cancer patients - PubMed [pubmed.ncbi.nlm.nih.gov]
- To cite this document: BenchChem. [Technical Support Center: Overcoming Challenges in HYNIC-iPSMA Image Interpretation]. BenchChem, [2025]. [Online PDF]. Available at: [https://www.benchchem.com/product/b12390982#overcoming-challenges-in-hynic-ipsma-image-interpretation]

---

### Disclaimer & Data Validity:

The information provided in this document is for Research Use Only (RUO) and is strictly not intended for diagnostic or therapeutic procedures. While BenchChem strives to provide accurate protocols, we make no warranties, express or implied, regarding the fitness of this product for every specific experimental setup.

**Technical Support:** The protocols provided are for reference purposes. Unsure if this reagent suits your experiment? [[Contact our Ph.D. Support Team for a compatibility check](#)]

**Need Industrial/Bulk Grade?** [Request Custom Synthesis Quote](#)

## BenchChem

Our mission is to be the trusted global source of essential and advanced chemicals, empowering scientists and researchers to drive progress in science and industry.

### Contact

Address: 3281 E Guasti Rd  
Ontario, CA 91761, United States  
Phone: (601) 213-4426  
Email: [info@benchchem.com](mailto:info@benchchem.com)