

Technical Support Center: Overcoming Challenges in Gadoxetic Acid Imaging of Small Lesions

Author: BenchChem Technical Support Team. **Date:** December 2025

Compound of Interest

Compound Name: *Gadoxetic acid*

Cat. No.: *B1262754*

[Get Quote](#)

This technical support center provides troubleshooting guidance and frequently asked questions (FAQs) for researchers, scientists, and drug development professionals utilizing **Gadoxetic acid** (Gd-EOB-DTPA) enhanced MRI for the imaging of small lesions.

Troubleshooting Guides

Issue: Transient Severe Motion (TSM) Artifacts Obscuring Small Lesions

Question: We are experiencing significant motion artifacts during the arterial phase of our **Gadoxetic acid**-enhanced MRI scans, making the detection and characterization of small lesions difficult. What are the potential causes and how can we mitigate this issue?

Answer:

Transient severe motion (TSM) is a known challenge in **Gadoxetic acid** imaging, often occurring during the arterial phase. The exact cause is not fully understood but is thought to be related to a transient dyspnea (shortness of breath) immediately following contrast injection.

Troubleshooting Steps:

- Identify At-Risk Subjects: Certain factors increase the risk of TSM. Consider implementing modified protocols for subjects with:

- Older age
- High Body Mass Index (BMI)
- History of chronic obstructive pulmonary disease (COPD) or other respiratory conditions.
[\[1\]](#)[\[2\]](#)
- Lower serum albumin levels.[\[1\]](#)[\[2\]](#)
- Modify Injection Protocol:
 - Slower Injection Rate: Reducing the injection rate from the standard 2 mL/s to 1 mL/s or even 0.5 mL/s has been shown to decrease the incidence and severity of motion artifacts without significantly compromising image quality for lesion detection.[\[3\]](#)
 - Dilution of Contrast: Diluting the **Gadoxetic acid** with saline (e.g., a 1:1 ratio) can also help in reducing motion artifacts.
 - Saline Flush: Always follow the contrast injection with a saline flush to ensure the full dose is delivered and to clear the injection line.
- Optimize Imaging Sequence:
 - Multiple Arterial Phase Acquisitions: Acquiring multiple arterial phase images can increase the likelihood of obtaining at least one artifact-free dataset.[\[4\]](#)
 - Motion-Robust Sequences: Consider using advanced motion-insensitive imaging sequences if available on your MRI system.[\[4\]](#)
- Patient Communication and Preparation:
 - Breath-hold Practice: Practice breath-holding with the subject before the contrast injection to ensure they can comfortably hold their breath for the required duration.
 - Clear Instructions: Provide clear and calm instructions to the subject immediately before and during the arterial phase acquisition.

Issue: Suboptimal Lesion-to-Liver Contrast in the Hepatobiliary Phase (HBP)

Question: We are having difficulty achieving sufficient contrast between small lesions and the surrounding liver parenchyma in the hepatobiliary phase (HBP). How can we optimize the timing of the HBP acquisition?

Answer:

Optimal lesion-to-liver contrast in the HBP is crucial for the detection of small, non-hypervascular lesions. The timing of the HBP is critical and can be influenced by the patient's liver function.

Troubleshooting Steps:

- Standard HBP Timing: For patients with normal liver function, the HBP is typically acquired 20 minutes post-injection.[\[5\]](#)[\[6\]](#)
- Adjusting for Liver Function:
 - Cirrhosis or Impaired Liver Function: In patients with compromised liver function, the uptake of **Gadoxetic acid** by hepatocytes is slower. Extending the delay time for HBP acquisition to 30, 40, or even 60 minutes may be necessary to achieve adequate liver enhancement and improve lesion conspicuity.[\[6\]](#)
 - Normal Liver Function: In some cases with normal liver function, optimal contrast may be achieved as early as 10 minutes post-injection.[\[6\]](#)
- Consider Patient-Specific Factors: Liver function can be assessed through clinical parameters (e.g., Child-Pugh score) or laboratory tests (e.g., bilirubin levels) to help guide the selection of an appropriate HBP delay.[\[6\]](#)

Frequently Asked Questions (FAQs)

Q1: What is the recommended injection protocol for **Gadoxetic acid** to minimize artifacts while ensuring adequate enhancement for small lesion detection?

A1: A slower injection rate of 1 mL/s is often recommended as a good balance between reducing the risk of transient severe motion artifacts and achieving sufficient arterial enhancement for the detection of hypervascular small lesions.^[3] Following the contrast injection with a saline flush is also a standard practice.

Q2: How does **Gadoxetic acid** uptake differ between healthy liver tissue and hepatocellular carcinoma (HCC)?

A2: Healthy hepatocytes actively take up **Gadoxetic acid** via organic anion transporting polypeptides (OATP1B3) on the cell membrane.^{[7][8][9]} Most HCCs, particularly poorly differentiated ones, have reduced or absent expression of these transporters, leading to decreased uptake and appearing as hypointense (dark) lesions on HBP images.^{[8][9]}

Q3: Can small benign lesions also appear hypointense in the hepatobiliary phase?

A3: Yes, some benign lesions that do not contain functional hepatocytes, such as cysts and hemangiomas, will also appear hypointense in the HBP. Therefore, it is crucial to interpret the HBP images in conjunction with the dynamic phase images and T2-weighted sequences for accurate characterization.^[10]

Q4: What is the role of Apparent Diffusion Coefficient (ADC) values in characterizing small lesions with **Gadoxetic acid** MRI?

A4: Diffusion-weighted imaging (DWI) and the corresponding ADC map provide complementary information. Malignant lesions, including small HCCs, tend to have restricted diffusion and thus lower ADC values compared to benign lesions and healthy liver tissue. Combining HBP imaging with DWI can improve the diagnostic accuracy for small HCCs.^[11]

Quantitative Data Summary

Parameter	Standard Protocol (2 mL/s injection)	Modified Protocol (1 mL/s injection)	Reference
Arterial Phase Motion Artifacts	Higher incidence and severity	Significantly lower incidence and severity	[3]
Aortic Signal-to-Noise Ratio (SNR)	190.94 +/- 96.90	235.43 +/- 82.59	[3]
Hypervascular HCC Detection Rate	Comparable	Comparable	[3]

Lesion Type	Typical Appearance on HBP	Typical ADC Values (x 10 ⁻³ mm ² /s)	Reference
Small Hepatocellular Carcinoma (HCC)	Hypointense	Low (e.g., < 1.2)	[11]
Dysplastic Nodule	Variable (often isointense to hypointense)	Variable (can overlap with HCC)	[11]
Hemangioma	Hypointense	High (e.g., > 1.8)	[10]
Focal Nodular Hyperplasia (FNH)	Isointense to Hyperintense	Similar to or slightly higher than liver	[10]

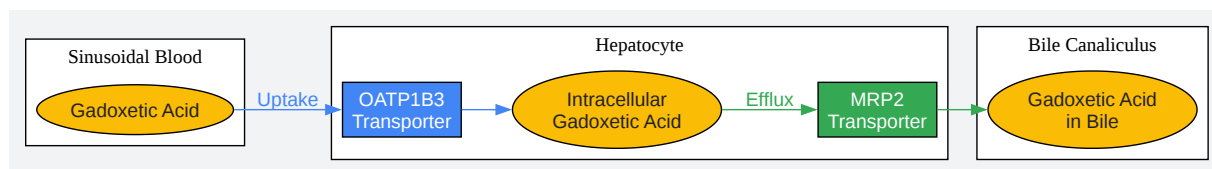
Experimental Protocols

Optimized Gadoteric Acid Injection and Imaging Protocol for Small Lesion Detection

- Patient Preparation:
 - Fasting for at least 4 hours prior to the MRI scan.
 - Informed consent obtained.
 - Practice breath-holding with the patient.

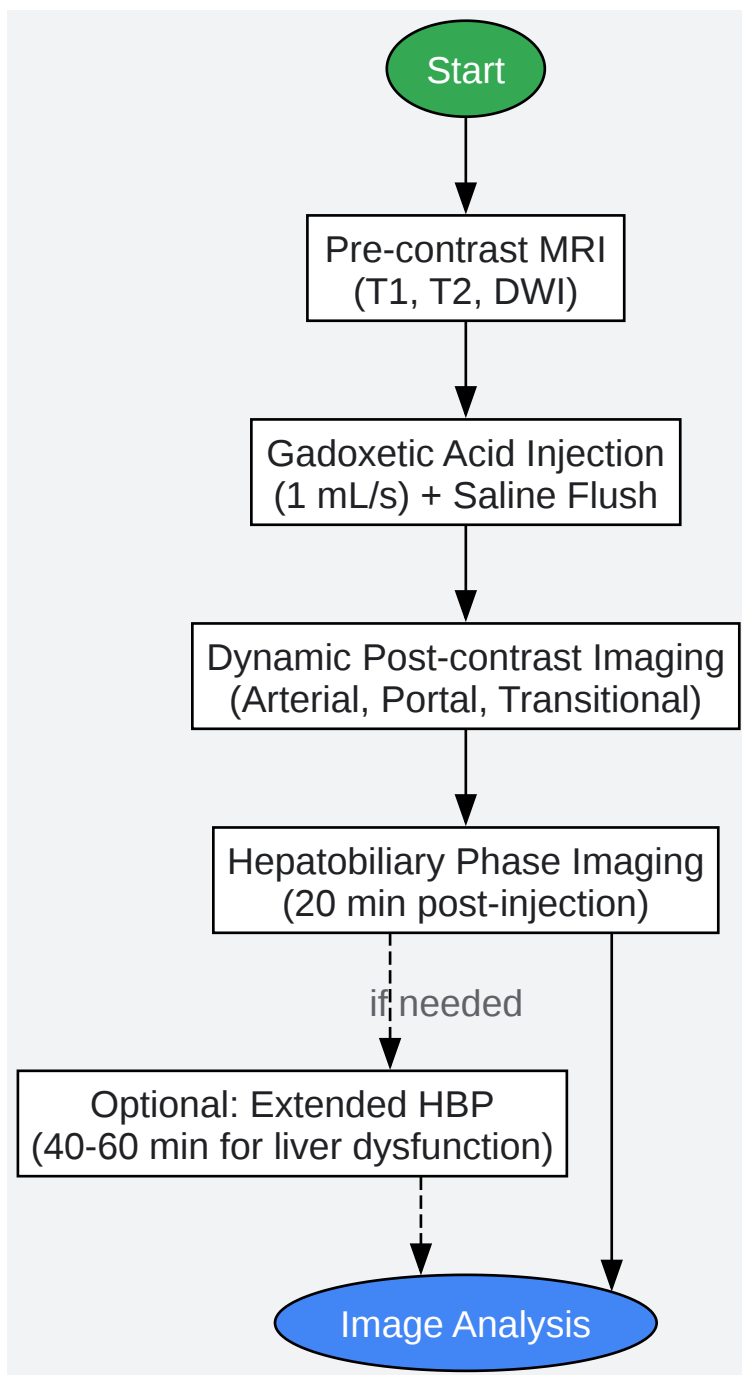
- MRI System: 1.5T or 3T MRI scanner with a phased-array torso coil.
- Pre-contrast Imaging:
 - T1-weighted in-phase and out-of-phase imaging.
 - T2-weighted single-shot fast spin-echo (SSFSE) or turbo spin-echo (TSE) sequences with and without fat suppression.
 - Diffusion-weighted imaging (DWI) with b-values of at least 0 and 800 s/mm².
- Contrast Injection:
 - Contrast Agent: **Gadoxetic acid** (0.025 mmol/kg body weight).
 - Injection Rate: 1 mL/s.
 - Saline Flush: 20 mL saline flush immediately following the contrast injection at the same rate.
- Dynamic Post-contrast Imaging (3D T1-weighted gradient-echo with fat suppression):
 - Arterial Phase: Acquired using a bolus tracking technique or a fixed delay of 20-30 seconds post-injection. Consider acquiring multiple arterial phases.
 - Portal Venous Phase: 60-70 seconds post-injection.
 - Transitional Phase: 3-5 minutes post-injection.
- Hepatobiliary Phase (HBP) Imaging (3D T1-weighted gradient-echo with fat suppression):
 - Standard Timing: 20 minutes post-injection.
 - Extended Timing (for suspected liver dysfunction): Consider additional acquisitions at 40 and 60 minutes post-injection.

Visualizations



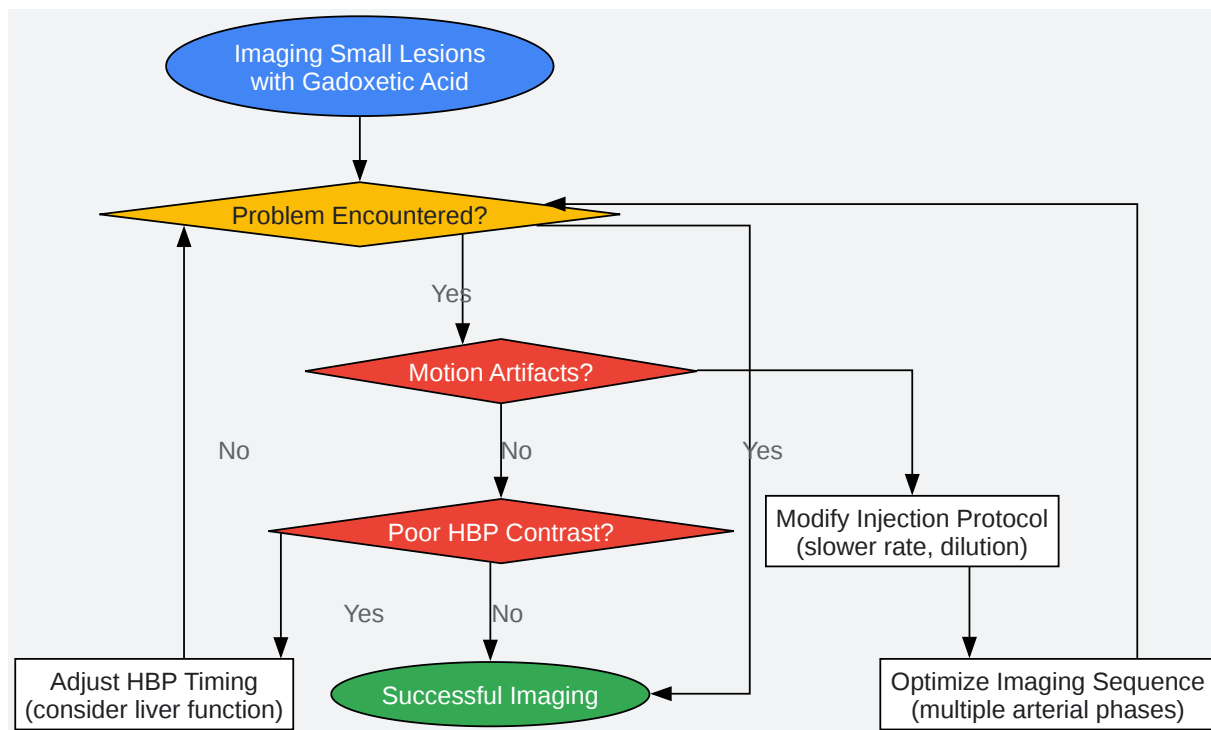
[Click to download full resolution via product page](#)

Caption: Cellular transport pathway of **Gadoxetic acid** in a hepatocyte.



[Click to download full resolution via product page](#)

Caption: Optimized experimental workflow for **Gadoxetic acid**-enhanced MRI.



[Click to download full resolution via product page](#)

Caption: Logical workflow for troubleshooting common challenges.

Need Custom Synthesis?

BenchChem offers custom synthesis for rare earth carbides and specific isotopic labeling.

Email: info@benchchem.com or [Request Quote Online](#).

References

- 1. Magnetic Resonance Imaging | Investigation of transient severe motion artifacts on gadoxetic acid–enhanced MRI: frequency and risk factors | [springermedicine.com](https://www.springermedicine.com)

[springermedicine.com]

- 2. Investigation of transient severe motion artifacts on gadoxetic acid-enhanced MRI: frequency and risk factors - PubMed [pubmed.ncbi.nlm.nih.gov]
- 3. Comparison of two different injection rates of gadoxetic acid for arterial phase MRI of the liver - PubMed [pubmed.ncbi.nlm.nih.gov]
- 4. Troubleshooting Arterial-Phase MR Images of Gadoxetate Disodium-Enhanced Liver - PMC [pmc.ncbi.nlm.nih.gov]
- 5. The MR imaging diagnosis of liver diseases using gadoxetic acid: Emphasis on hepatobiliary phase - PMC [pmc.ncbi.nlm.nih.gov]
- 6. Optimization of hepatobiliary phase imaging in gadoxetic acid-enhanced magnetic resonance imaging: a narrative review - PMC [pmc.ncbi.nlm.nih.gov]
- 7. pubs.rsna.org [pubs.rsna.org]
- 8. pubs.rsna.org [pubs.rsna.org]
- 9. Patterns of enhancement in the hepatobiliary phase of gadoxetic acid-enhanced MRI - PMC [pmc.ncbi.nlm.nih.gov]
- 10. Liver-specific gadoxetic acid-enhanced magnetic resonance for focal lesion evaluation | Revista de Gastroenterología de México [revistagastroenterologiamexico.org]
- 11. Characterization of small (≤ 3 cm) hepatic lesions with atypical enhancement feature and hypointensity in hepatobiliary phase of gadoxetic acid-enhanced MRI in cirrhosis: A STARD-compliant article - PMC [pmc.ncbi.nlm.nih.gov]
- To cite this document: BenchChem. [Technical Support Center: Overcoming Challenges in Gadoxetic Acid Imaging of Small Lesions]. BenchChem, [2025]. [Online PDF]. Available at: [https://www.benchchem.com/product/b1262754#overcoming-challenges-in-gadoxetic-acid-imaging-of-small-lesions]

Disclaimer & Data Validity:

The information provided in this document is for Research Use Only (RUO) and is strictly not intended for diagnostic or therapeutic procedures. While BenchChem strives to provide accurate protocols, we make no warranties, express or implied, regarding the fitness of this product for every specific experimental setup.

Technical Support: The protocols provided are for reference purposes. Unsure if this reagent suits your experiment? [[Contact our Ph.D. Support Team for a compatibility check](#)]

Need Industrial/Bulk Grade? [Request Custom Synthesis Quote](#)

BenchChem

Our mission is to be the trusted global source of essential and advanced chemicals, empowering scientists and researchers to drive progress in science and industry.

Contact

Address: 3281 E Guasti Rd
Ontario, CA 91761, United States
Phone: (601) 213-4426
Email: info@benchchem.com