

Technical Support Center: Optimizing the Big-Bubble Technique for Difficult Cases

Author: BenchChem Technical Support Team. **Date:** December 2025

Compound of Interest

Compound Name: dALK-3

Cat. No.: B15575147

[Get Quote](#)

This technical support center provides troubleshooting guides and frequently asked questions (FAQs) to assist researchers, scientists, and drug development professionals in optimizing the big-bubble technique for challenging scenarios in Deep Anterior Lamellar Keratoplasty (DALK).

Troubleshooting Guides

This section addresses specific issues that may be encountered during the big-bubble procedure, offering step-by-step solutions to overcome them.

Issue 1: Failure to Form a Big Bubble

- Question: I am injecting air, but a big bubble is not forming. What should I do?
- Answer: Failure to form a big bubble is a common challenge. Here's a systematic approach to troubleshoot this issue:
 - Assess Needle Depth: The most common reason for failure is incorrect needle depth. The needle tip should be placed as close to the Descemet's membrane (DM) as possible.^[1] Some studies suggest that successful big bubble formation requires the needle to be at a significant corneal depth.^[1]
 - Re-injection Strategy: If the initial attempt fails and surgical emphysema occurs in the superficial stroma, stop the injection. Withdraw the needle and reinsert it at a deeper level

in an adjacent clear corneal area.[2] Repeat the air injection until a large bubble forms or the cornea becomes too opaque for visualization.[2]

- Confirm Bubble Presence: In cases of an opaque cornea after multiple attempts, you can confirm the presence of a bubble by draining aqueous from the anterior chamber. The cornea over the bubble will remain firm in a soft eye.[2]
- Consider Viscoelastic Injection: If air injection repeatedly fails, some surgeons have found success by injecting a viscoelastic substance to create or expand the bubble.[3][4] This can be particularly useful for expanding a partially formed bubble.
- Manual Dissection as a Fallback: If all attempts to create a big bubble fail, the procedure can be converted to a manual layer-by-layer dissection down to the pre-Descemet or Descemet level.[4][5][6] While visually not as optimal as a successful big bubble, it can still yield good results.[6][7][8]

Issue 2: Descemet's Membrane (DM) Perforation

- Question: I suspect a perforation of the Descemet's membrane has occurred. How should I proceed?
- Answer: DM perforation is a significant complication, but it can often be managed without converting to a full-thickness penetrating keratoplasty (PK).
 - Identify the Perforation: Microperforations can be difficult to see. A sign might be the shallowing of the anterior chamber.
 - Management of Microperforations: Small perforations can often be managed by injecting an air bubble into the anterior chamber to seal the leak.[2] The remainder of the procedure can then be completed. At the end of the surgery, filling the anterior chamber with air can help prevent a double anterior chamber.[5]
 - Management of Larger Tears: For larger tears, conversion to PK may be necessary.[9] The decision to convert depends on the size and location of the tear and the surgeon's experience.

- Postoperative Care: Even with seemingly insignificant microperforations, there is a risk of postoperative DM detachment.[7][8] Close postoperative monitoring is crucial.

Issue 3: Management of Different Bubble Types

- Question: I have formed a bubble, but it doesn't look like the typical "big bubble." How do I identify and manage different bubble types?
- Answer: It is now understood that different types of bubbles can form during the procedure.
[10]
 - Type 1 Bubble: This is the desired bubble, where air separates Dua's layer from the deep stroma, creating a large central bubble of about 8-9 mm in diameter.[10] This is the ideal scenario for DALK.
 - Type 2 Bubble: In this case, the air separates the DM from the posterior surface of Dua's layer.[10] Attempting to bare the DM in the presence of a Type 2 bubble has a high rate of conversion to PK and should be avoided.[11] Safer management involves deep stromal dissection to find an incomplete Type 1 bubble or using manual dissection techniques.[11]
 - Mixed Bubble (Type 1 and Type 2): When a mixed bubble occurs, the Type 1 portion should be opened, and the surgery completed while avoiding the Type 2 bubble area.[11]

Frequently Asked Questions (FAQs)

Q1: What are the success rates of the big-bubble technique in difficult cases like keratoconus?

A1: The success rate of achieving a big bubble in keratoconus varies in the literature, generally ranging from 75% to over 80%.[6][9][12][13] The learning curve for the technique can influence these rates, with success often increasing with surgical experience.[9] Even if a big bubble is not achieved, the procedure can often be successfully completed using manual dissection, although the visual outcomes may be slightly inferior to cases with a successful big bubble.[6]
[14]

Q2: What are the common complications associated with the big-bubble technique, especially in pediatric patients?

A2: Common intraoperative complications include failure to create a big bubble and perforation of the Descemet's membrane.[5] Postoperative complications can include graft rejection (non-endothelial), suture-related issues, high intraocular pressure, and graft epithelial problems.[9][12][13] In pediatric patients with keratoconus, suture-related complications such as premature loosening, broken sutures, and suture-tract vascularization are also frequently observed.[12][13]

Q3: Are there any modifications to the standard big-bubble technique for cases with corneal scarring?

A3: Yes, corneal scarring can make the standard technique challenging. In such cases, the air injection should be initiated in an area of the trephination with the least opacity to allow for better visualization.[5] If a big bubble is achieved, a sharp blade is used to enter the stroma towards the air bubble, and placing viscoelastic over the central stroma before this step can slow the release of the air bubble and reduce the risk of perforation.[5] Another modification is the "large-bubble" technique, which involves a shallow trephination followed by a more superficial air injection to achieve a bubble that extends to the periphery.[15]

Q4: What are the visual outcomes of DALK using the big-bubble technique compared to penetrating keratoplasty (PK)?

A4: Studies have shown that the visual acuity following a successful big-bubble DALK is comparable to that achieved with PK.[7][8][16] However, when manual dissection is performed due to a failed big bubble, the visual outcomes might not be as good as PK.[7][8] DALK offers significant advantages over PK, including the elimination of endothelial graft rejection and a lower risk of postoperative complications like ocular hypertension.[16]

Data Presentation

Table 1: Success Rates and Visual Outcomes of Big-Bubble DALK in Keratoconus

Study	Number of Eyes	Big-Bubble Success Rate	Pre-operative BSCVA (logMAR)	Post-operative BSCVA (logMAR)
Feizi et al. (Pediatric Keratoconus)[12] [13]	44	75.0%	1.34 ± 0.49	0.24 ± 0.10
Javadi et al.[9]	104	82.7%	1.23 ± 0.4	0.26 ± 0.2
Ghodhbani et al. [6]	289	79.2%	Not Specified	Better in successful BB group

BSCVA: Best Spectacle-Corrected Visual Acuity

Table 2: Common Complications of Big-Bubble DALK

Complication	Feizi et al. (Pediatric)[12] [13]	Javadi et al.[9]
DM Perforation	11.4%	Not Specified
Non-endothelial Graft Rejection	11.4%	14.4%
High Intraocular Pressure	18.2%	Not Specified
Suture-related Complications	High incidence (e.g., 29.6% premature loosening)	10.6% suture abscess
Filamentary Keratitis	Not Specified	19.2%

Experimental Protocols

Protocol 1: Standard Big-Bubble Technique (Anwar's Technique)

- Trephination: Perform a partial-thickness trephination of the recipient cornea to approximately 80% of its depth.[9]

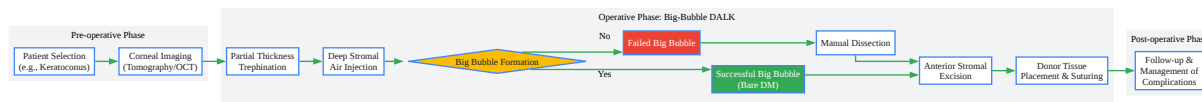
- Needle Insertion: Insert a 27-gauge or 30-gauge needle, bent at a 30-40 degree angle with the bevel down, into the deep stroma at the base of the trephination groove.[\[5\]](#)[\[9\]](#)
- Air Injection: Inject air forcefully to create a "big bubble" that separates the Descemet's membrane from the posterior stroma.[\[2\]](#)
- Bubble Confirmation: The formation of a large, central, clear bubble indicates success.
- Stromal Excision: Create a small opening in the anterior stroma to enter the plane of the big bubble. Use a blunt-tipped spatula and scissors to excise the anterior stromal tissue, exposing the bare Descemet's membrane.[\[2\]](#)
- Donor Tissue Placement: Place the donor cornea (with its endothelium and DM removed) onto the recipient bed and suture it in place.

Protocol 2: "Expanding Bubble" Modification

This technique is useful when the initial big bubble is smaller than the trephination diameter.[\[3\]](#)

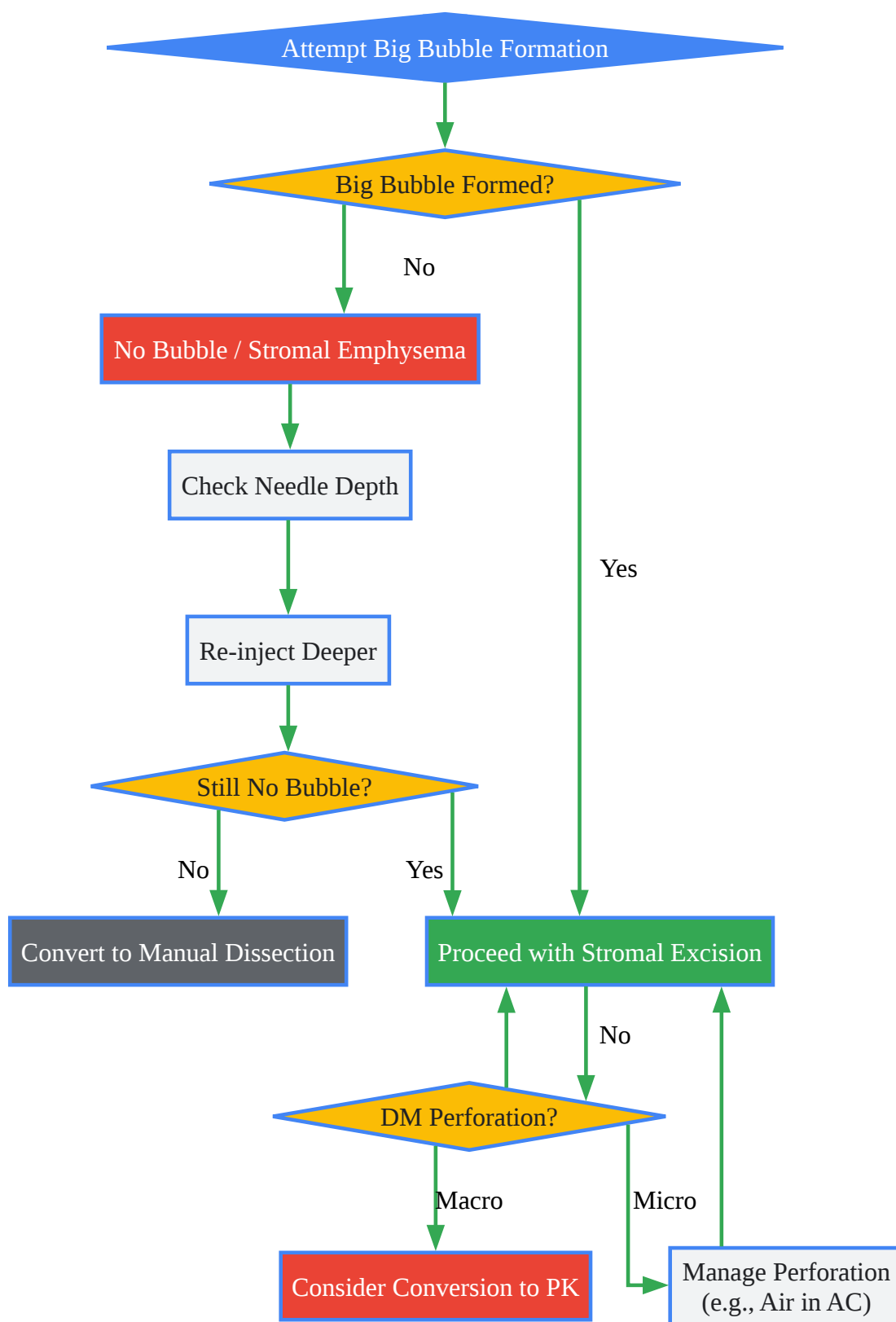
- Initial Big Bubble Formation: Follow steps 1-3 of the standard protocol to create an initial big bubble.
- Viscoelastic Injection: Inject a viscoelastic substance into the bubble cavity.[\[3\]](#)
- Bubble Expansion: The viscoelastic will expand the bubble to the desired size, reaching the edges of the trephination wound.[\[3\]](#)
- Stromal Excision and Donor Placement: Proceed with stromal excision and donor tissue placement as in the standard technique.

Mandatory Visualization



[Click to download full resolution via product page](#)

Caption: Workflow of the Big-Bubble Deep Anterior Lamellar Keratoplasty (DALK).



[Click to download full resolution via product page](#)

Caption: Troubleshooting logic for common issues in the big-bubble technique.

Need Custom Synthesis?

BenchChem offers custom synthesis for rare earth carbides and specific isotopic labeling.

Email: info@benchchem.com or [Request Quote Online](#).

References

- 1. Needle Depth and Big Bubble Success in Deep Anterior Lamellar Keratoplasty: An Ex Vivo Microscope-Integrated OCT Study - PMC [pmc.ncbi.nlm.nih.gov]
- 2. The Big Bubble Technique | Ento Key [entokey.com]
- 3. 'Expanding bubble' modification of 'big-bubble' technique for performing maximum-depth anterior lamellar keratoplasty - PMC [pmc.ncbi.nlm.nih.gov]
- 4. reviewofophthalmology.com [reviewofophthalmology.com]
- 5. DALK: Performing Big-Bubble Keratoplasty | Corneal Physician [pv-cp-staging.hbrsd.com]
- 6. Visual Outcomes of Successful versus Failed Big-Bubble Deep Anterior Lamellar Keratoplasty for Keratoconus - PMC [pmc.ncbi.nlm.nih.gov]
- 7. aao.org [aao.org]
- 8. aao.org [aao.org]
- 9. Deep Anterior Lamellar Keratoplasty Using the Big-Bubble Technique in Keratoconus - PMC [pmc.ncbi.nlm.nih.gov]
- 10. Differentiating type 1 from type 2 big bubbles in deep anterior lamellar keratoplasty - PMC [pmc.ncbi.nlm.nih.gov]
- 11. Management of Type 2 Bubble Formed During Big Bubble Deep Anterior Lamellar Keratoplasty - PubMed [pubmed.ncbi.nlm.nih.gov]
- 12. Outcomes of big-bubble deep anterior lamellar keratoplasty for pediatric keratoconus - ProQuest [proquest.com]
- 13. Outcomes of big-bubble deep anterior lamellar keratoplasty for pediatric keratoconus - PubMed [pubmed.ncbi.nlm.nih.gov]
- 14. researchgate.net [researchgate.net]
- 15. dr-jabarvand.com [dr-jabarvand.com]
- 16. reviewofoptometry.com [reviewofoptometry.com]

- To cite this document: BenchChem. [Technical Support Center: Optimizing the Big-Bubble Technique for Difficult Cases]. BenchChem, [2025]. [Online PDF]. Available at: [https://www.benchchem.com/product/b15575147#optimizing-the-big-bubble-technique-for-difficult-cases]

Disclaimer & Data Validity:

The information provided in this document is for Research Use Only (RUO) and is strictly not intended for diagnostic or therapeutic procedures. While BenchChem strives to provide accurate protocols, we make no warranties, express or implied, regarding the fitness of this product for every specific experimental setup.

Technical Support: The protocols provided are for reference purposes. Unsure if this reagent suits your experiment? [[Contact our Ph.D. Support Team for a compatibility check](#)]

Need Industrial/Bulk Grade? [Request Custom Synthesis Quote](#)

BenchChem

Our mission is to be the trusted global source of essential and advanced chemicals, empowering scientists and researchers to drive progress in science and industry.

Contact

Address: 3281 E Guasti Rd
Ontario, CA 91761, United States
Phone: (601) 213-4426
Email: info@benchchem.com