

Technical Support Center: Optimizing Ultrasound Imaging of CPP Deposits

Author: BenchChem Technical Support Team. **Date:** December 2025

Compound of Interest

Compound Name: Calcium pyrophosphate

Cat. No.: B051889

[Get Quote](#)

This technical support center provides troubleshooting guidance and answers to frequently asked questions to help researchers, scientists, and drug development professionals minimize artifacts during ultrasound imaging of **Calcium Pyrophosphate** Dihydrate (CPPD) crystal deposits.

Troubleshooting Guide: Common Imaging Artifacts

Issue: Suspected CPPD deposits are not clearly visible or appear hypoechoic (darker than expected).

Possible Cause & Solution:

- **Anisotropy:** The ultrasound beam is not perpendicular to the bone surface, causing a "bone pseudo-defect artifact" where the bone appears hypoechoic.^[1] Since CPPD echogenicity is often compared to the underlying bone, this can lead to misinterpretation.
 - **Troubleshooting Step:** Carefully adjust the probe to ensure the ultrasound beam is perfectly perpendicular (at a 90-degree angle) to the bone surface beneath the deposit.^[1] This will maximize the reflection from the bone, providing an accurate reference for the echogenicity of the CPP crystals.
- **Incorrect Gain or Dynamic Range Settings:** Inappropriate machine settings can reduce the visibility of smaller or less dense deposits.

- Troubleshooting Step:

- Adjust Dynamic Range (DR): A lower DR (higher contrast) can increase the echogenicity of small deposits, making them appear more similar to the bone profile.[\[1\]](#)
[\[2\]](#)
- Optimize Gain: While adjusting the gain modifies the overall brightness of the image, the ratio of echogenicity between the bone and the deposits should remain consistent.
[\[1\]](#)[\[2\]](#) If deposits are still unclear, try slightly increasing the gain. In cases of uncertainty, scanning other potential CPPD sites can help increase diagnostic confidence.[\[1\]](#)[\[2\]](#)

Issue: Difficulty distinguishing CPPD deposits from other hyperechoic structures.

Possible Cause & Solution:

- Posterior Acoustic Shadowing: Unlike other calcifications, CPPD crystals typically do not produce posterior acoustic shadowing.[\[1\]](#) This is likely due to their three-dimensional structure, which results in lower acoustic impedance and less attenuation of the ultrasound beam.[\[1\]](#)[\[3\]](#)
 - Troubleshooting Step: Look for the presence or absence of a shadow behind the hyperechoic finding. The absence of a shadow is a key characteristic of CPPD deposits.
- Anisotropy in Tendons: Tendons can appear hyperechoic, similar to CPPD, but they exhibit anisotropy.
 - Troubleshooting Step: Tilt the probe. The tendon will become hypoechoic due to anisotropy, while the CPPD deposits, which are not anisotropic, will remain hyperechogenic.[\[4\]](#) This "trick" can help in the easy identification of calcium crystals within tendons.[\[4\]](#)
- Dynamic Scanning: Some hyperechoic areas may be due to ligaments that appear bright only when taut.
 - Troubleshooting Step: Perform dynamic scanning by moving the joint through its range of motion. CPPD deposits will generally remain visible regardless of the joint's position, whereas ligamentous artifacts may disappear or change with movement.[\[1\]](#)[\[2\]](#)

Frequently Asked Questions (FAQs)

Q1: What are the characteristic ultrasound findings of CPPD?

According to the OMERACT (Outcome Measures in Rheumatology) definitions, CPP deposits typically appear as hyperechogenic (bright) structures, similar in echogenicity to the bone profile.^[1] They are often seen as thin, hyperechoic bands within hyaline cartilage or as punctate, hyperechoic spots in fibrocartilage.^[5] A key distinguishing feature is the typical absence of posterior acoustic shadowing.^[1]

Q2: Which joints are most important to scan for suspected CPPD?

The knee is the most frequently involved joint in CPPD.^[1] Studies have shown that a reduced scanning protocol that includes bilateral assessment of the knees, wrists, and hips provides excellent sensitivity and specificity for diagnosing CPPD.^{[6][7][8][9]} The meniscal fibrocartilage is the most commonly affected structure.^[1]

Q3: Can ultrasound machine settings affect the appearance of CPPD deposits?

Yes, machine settings, particularly gain and dynamic range, can significantly influence the echogenicity of CPPD deposits.^[1] It is crucial to optimize these settings to enhance crystal visualization. Operator experience in adjusting these parameters is fundamental for accurate diagnosis.^{[1][2]}

Q4: What is the "pseudo double contour" sign in CPPD?

The "pseudo double contour" sign refers to the deposition of CPP crystals over the cartilage, which can be observed on ultrasound.^[1] This is thought to be caused by crystals depositing in the capsule or ligaments located just above the hyaline cartilage, rather than on the cartilage itself, as seen in gout.^[1]

Experimental Protocols

Standardized Ultrasound Scanning Protocol for CPPD Assessment

This protocol is based on established research methodologies for the comprehensive evaluation of CPPD.^{[6][8][10]}

Objective: To systematically scan multiple joints and anatomical targets to identify the presence and extent of CPP crystal deposition.

Equipment: High-resolution ultrasound machine with a linear transducer (frequency appropriate for the depth of the structure being imaged).

Procedure:

- **Patient Positioning:** Position the patient comfortably to allow for easy access to the joints being scanned. Specific positioning for each joint (e.g., knee flexion to access the femoral trochlea's hyaline cartilage) should be followed.[\[1\]](#)
- **Bilateral Joint Assessment:** Scan the following joints bilaterally:
 - Knees
 - Wrists
 - Hips
 - Shoulders
 - Elbows
 - Metacarpophangeal joints (2nd to 5th)
 - Ankles
- **Anatomical Targets:** Within each joint, systematically evaluate the following structures for hyperechoic deposits consistent with CPPD:
 - Hyaline cartilage
 - Fibrocartilage (e.g., menisci, triangular fibrocartilage complex)
 - Tendons
 - Ligaments

- Joint capsule
- Image Optimization: For each target, optimize the ultrasound settings (gain, dynamic range, frequency, focus) to enhance the visualization of potential crystal deposits.
- Artifact Mitigation: Actively employ techniques to minimize artifacts, such as ensuring a perpendicular insonation angle to avoid anisotropy and performing dynamic scanning.
- Scoring: The presence or absence of CPPD in each anatomical site is recorded. A semiquantitative scoring system, as developed by the OMERACT ultrasound working group, can also be used to assess the burden of deposition.[\[1\]](#)

Quantitative Data Summary

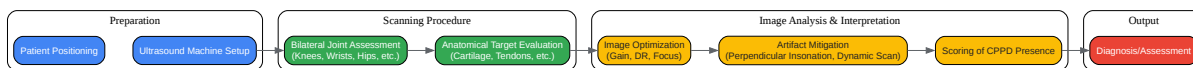Diagnostic Accuracy of Reduced Ultrasound Scanning Protocol (Bilateral Knees, Wrists, and Hips)[\[6\]](#)[\[8\]](#)[\[9\]](#)

Metric	Value (95% Confidence Interval)
Sensitivity	96.7% (82.8% - 99.9%)
Specificity	100% (88.8% - 100.0%)

Prevalence of CPPD in Different Anatomical Sites in Patients with CPPD[\[7\]](#)

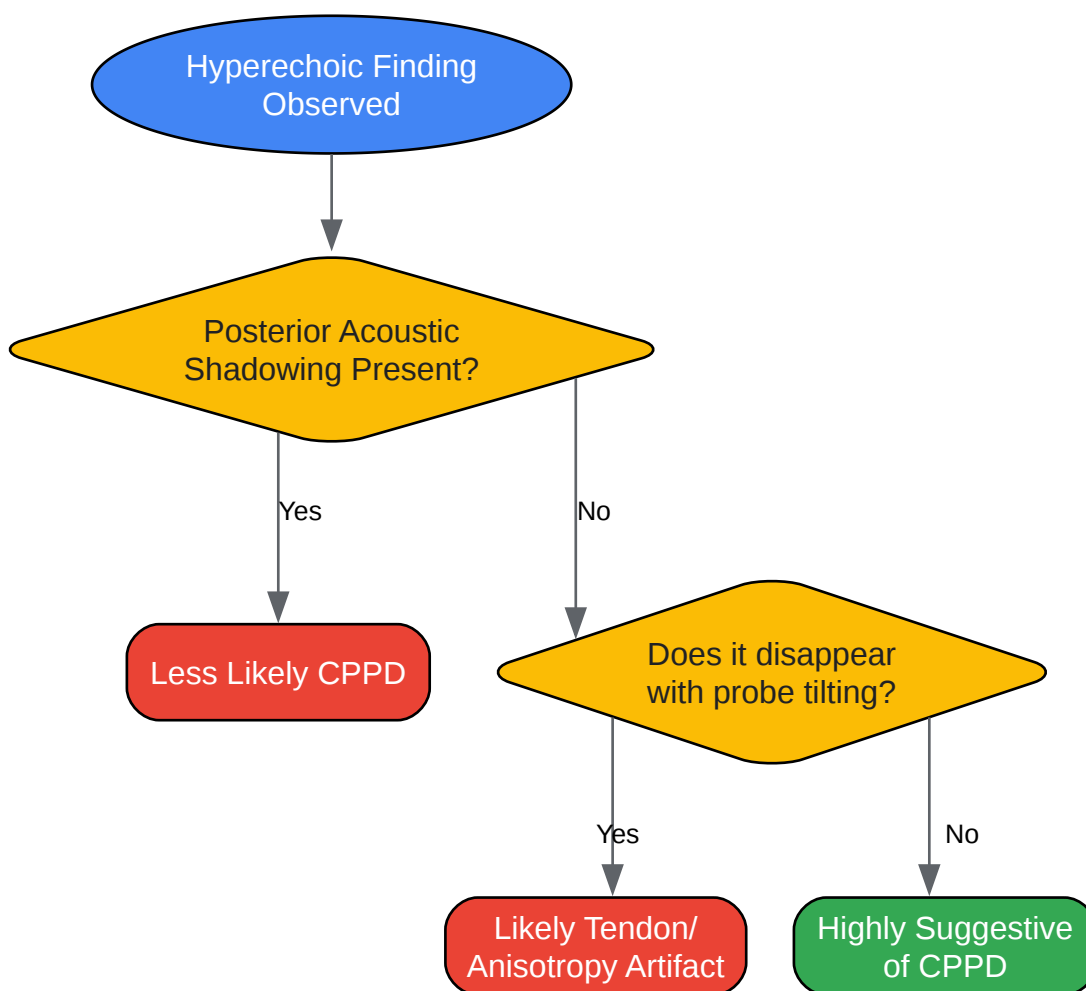
Anatomical Site	Prevalence
Medial Meniscus (Knee)	87.5%
Lateral Meniscus (Knee)	80.7%

Visual Guides



[Click to download full resolution via product page](#)

Caption: Standardized workflow for ultrasound assessment of CPPD.



[Click to download full resolution via product page](#)

Caption: Decision tree for differentiating CPPD from common artifacts.

Need Custom Synthesis?

BenchChem offers custom synthesis for rare earth carbides and specific isotopic labeling.

Email: info@benchchem.com or [Request Quote Online](#).

References

- 1. Optimizing the Use of Ultrasound in Calcium Pyrophosphate Deposition (CPPD): A Review from the Ground Up | MDPI [mdpi.com]
- 2. researchgate.net [researchgate.net]
- 3. Advanced imaging techniques in crystal arthritis - PMC [pmc.ncbi.nlm.nih.gov]
- 4. researchgate.net [researchgate.net]
- 5. Imaging of Calcium Pyrophosphate Deposition Disease - PMC [pmc.ncbi.nlm.nih.gov]
- 6. academic.oup.com [academic.oup.com]
- 7. Ultrasound Diagnosis of Calcium Pyrophosphate Crystal Deposition: Which Sites Should Be Scanned? - ACR Meeting Abstracts [acrabstracts.org]
- 8. physiciansweekly.com [physiciansweekly.com]
- 9. [PDF] Diagnosis of calcium pyrophosphate crystal deposition disease by ultrasonography: how many and which sites should be scanned? | Semantic Scholar [semanticscholar.org]
- 10. Diagnosis of calcium pyrophosphate crystal deposition disease by ultrasonography: how many and which sites should be scanned? - PMC [pmc.ncbi.nlm.nih.gov]
- To cite this document: BenchChem. [Technical Support Center: Optimizing Ultrasound Imaging of CPP Deposits]. BenchChem, [2025]. [Online PDF]. Available at: [https://www.benchchem.com/product/b051889#minimizing-artifacts-in-ultrasound-imaging-of-cpp-deposits]

Disclaimer & Data Validity:

The information provided in this document is for Research Use Only (RUO) and is strictly not intended for diagnostic or therapeutic procedures. While BenchChem strives to provide accurate protocols, we make no warranties, express or implied, regarding the fitness of this product for every specific experimental setup.

Technical Support: The protocols provided are for reference purposes. Unsure if this reagent suits your experiment? [[Contact our Ph.D. Support Team for a compatibility check](#)]

Need Industrial/Bulk Grade? [Request Custom Synthesis Quote](#)

BenchChem

Our mission is to be the trusted global source of essential and advanced chemicals, empowering scientists and researchers to drive progress in science and industry.

Contact

Address: 3281 E Guasti Rd
Ontario, CA 91761, United States
Phone: (601) 213-4426
Email: info@benchchem.com