

Technical Support Center: Optimizing Imaging for LX-039 Treated Tumors

Author: BenchChem Technical Support Team. **Date:** December 2025

Compound of Interest

Compound Name: LX-039

Cat. No.: B15142904

[Get Quote](#)

This technical support center provides researchers, scientists, and drug development professionals with comprehensive guidance on optimizing imaging techniques for tumors treated with **LX-039**, a novel inhibitor of the PI3K/AKT/mTOR signaling pathway. This document includes troubleshooting guides, frequently asked questions (FAQs), detailed experimental protocols, and data presentation tables to address specific issues encountered during pre-clinical and clinical imaging studies.

I. Frequently Asked Questions (FAQs)

This section addresses common questions regarding the imaging of **LX-039** treated tumors.

Q1: What is the primary mechanism of action for **LX-039** and how does it influence our imaging strategy?

A1: **LX-039** is a potent inhibitor of the PI3K/AKT/mTOR signaling pathway, which is crucial for tumor cell growth, proliferation, and survival.^{[1][2][3]} By blocking this pathway, **LX-039** is expected to induce metabolic changes and apoptosis in tumor cells. This mechanism suggests that functional and molecular imaging techniques, which can detect these early cellular changes, may be more informative for assessing treatment response than conventional anatomical imaging that primarily measures tumor size.

Q2: Which imaging modalities are recommended for monitoring the therapeutic effects of **LX-039**?

A2: A multi-modal imaging approach is recommended. This includes:

- Positron Emission Tomography (PET): Primarily using tracers like 18F-FDG to assess changes in glucose metabolism and 18F-FLT to monitor cell proliferation.[1]
- Magnetic Resonance Imaging (MRI): Including advanced techniques like Diffusion-Weighted Imaging (DWI) to measure changes in water diffusion related to cell density and Magnetic Resonance Spectroscopy (MRS) to detect alterations in tumor metabolism.[4][5][6]
- Anatomical Imaging (CT and conventional MRI): To monitor changes in tumor size and morphology over the course of treatment.[7][8]

Q3: How soon after **LX-039** treatment can we expect to see changes with these imaging techniques?

A3: Functional and molecular imaging techniques can often detect treatment effects earlier than anatomical imaging.

- PET: Changes in 18F-FDG uptake can be observed within hours to days of initiating treatment.[9]
- DWI: Alterations in the Apparent Diffusion Coefficient (ADC) can also be detected within a few days of successful therapy.[5]
- Anatomical Changes: Significant reductions in tumor volume may take longer to become apparent, often weeks into the treatment.

Q4: Can MRI differentiate between a cancerous and a non-cancerous tumor?

A4: While MRI can provide clues about the nature of a tumor, it cannot definitively diagnose cancer.[8][10] Benign tumors often have smoother, more defined edges, whereas malignant tumors may appear more irregular.[10] However, a biopsy is typically required for a definitive diagnosis.[10] MRI is particularly effective at visualizing soft tissue tumors.[11]

Q5: What are the limitations of PET scans in detecting cancer?

A5: PET scans can sometimes produce false negatives for several reasons, including small tumor size, the type of tumor (some have low glucose uptake), and technical limitations such as patient movement.^[7]

II. Troubleshooting Guides

This section provides solutions to common problems encountered during the imaging of **LX-039** treated tumors.

Positron Emission Tomography (PET) Imaging

| Problem | Possible Cause(s) | Recommended Solution(s) |
|---|--|---|
| High background signal or non-specific uptake of 18F-FDG. | Inflammation, infection, or recent surgery at the tumor site. [12] [13] | Correlate PET findings with anatomical imaging (CT or MRI) to rule out non-malignant causes of uptake. Ensure the patient has followed proper preparation protocols (e.g., fasting). |
| Variable 18F-FDG uptake within the tumor. | Tumor heterogeneity, with some regions being more metabolically active than others. [9] | Perform detailed image analysis, including segmenting the tumor to assess regional changes in tracer uptake. Consider co-registration with other imaging modalities to understand the underlying biology. |
| Misalignment of PET and CT images. | Patient movement between scans or respiratory motion. [14] [15] | Use motion correction techniques and ensure the patient is comfortable and immobilized during the scan. For thoracic imaging, respiratory gating can minimize motion artifacts. [13] |
| False-positive findings. | Benign processes such as inflammation, infection, or certain benign tumors can show increased FDG uptake. [12] [13] | Careful review of the patient's clinical history and correlation with CT or MRI findings are essential. In some cases, a biopsy may be necessary to confirm malignancy. |

Magnetic Resonance Imaging (MRI)

| Problem | Possible Cause(s) | Recommended Solution(s) |
|---|---|--|
| Low contrast between tumor and surrounding tissue. | Suboptimal pulse sequence parameters. | Optimize T1-weighted, T2-weighted, and FLAIR sequences. The use of a contrast agent (e.g., gadolinium) can enhance tumor visibility. [8] |
| Motion artifacts. | Patient movement during the long acquisition times. | Use motion correction sequences and ensure the patient is comfortable. For pediatric or uncooperative patients, sedation may be necessary. |
| Inaccurate tumor volume measurements. | Poor image resolution or difficulty in delineating tumor margins. | Acquire high-resolution 3D images. Use semi-automated or automated segmentation software for more reproducible measurements. |
| Inability to distinguish recurrent tumor from post-treatment changes. | Scar tissue and inflammation can mimic tumor recurrence on conventional MRI. [16] | Utilize advanced MRI techniques. DWI can help by showing restricted diffusion in recurrent tumors, and MRS may reveal a metabolic profile consistent with malignancy. [17] |

Diffusion-Weighted Imaging (DWI)

| Problem | Possible Cause(s) | Recommended Solution(s) |
|--|---|---|
| No significant change in ADC values post-treatment despite other indicators of response. | The chosen b-values may not be optimal for detecting subtle changes in water diffusion. | Experiment with a range of b-values to find the most sensitive settings for the specific tumor type. |
| "T2 shine-through" effect. | Tissues with long T2 relaxation times can appear bright on DWI images, mimicking restricted diffusion. [18] | Always correlate DWI images with the corresponding ADC map. True restricted diffusion will appear dark on the ADC map. [18] |
| Low signal-to-noise ratio. | High b-values can lead to a decrease in signal. | Optimize imaging parameters, including the number of acquisitions, to improve the signal-to-noise ratio. |

Magnetic Resonance Spectroscopy (MRS)

| Problem | Possible Cause(s) | Recommended Solution(s) |
|---|---|--|
| Poor spectral quality. | Magnetic field inhomogeneity, patient motion, or lipid contamination. | Ensure proper shimming of the magnetic field. Use outer volume suppression techniques to minimize lipid signals. |
| Difficulty in interpreting metabolic changes. | The metabolic response to LX-039 may be complex and vary between tumor types. | Establish a baseline metabolic profile before treatment. Compare post-treatment spectra to the baseline and to control subjects. |
| Low spatial resolution. | MRS typically has lower spatial resolution compared to other MRI techniques. | Use higher field strength magnets (e.g., 3T or 7T) if available. Employ advanced spectroscopic imaging techniques to improve spatial coverage. |

III. Experimental Protocols

18F-FDG PET/CT Imaging Protocol

- Patient Preparation: Patients should fast for at least 6 hours prior to the scan to ensure low blood glucose and insulin levels.
- Radiotracer Injection: Administer 18F-FDG intravenously at a dose of 370 MBq (10 mCi).
- Uptake Phase: The patient should rest in a quiet, dimly lit room for 60 minutes to allow for tracer uptake.
- Imaging: Acquire a whole-body CT scan for attenuation correction and anatomical localization, followed by a whole-body PET scan.
- Image Analysis: Reconstruct PET images and co-register with the CT data. Calculate Standardized Uptake Values (SUV) for quantitative analysis of glucose metabolism in the tumor.

Diffusion-Weighted Imaging (DWI) Protocol

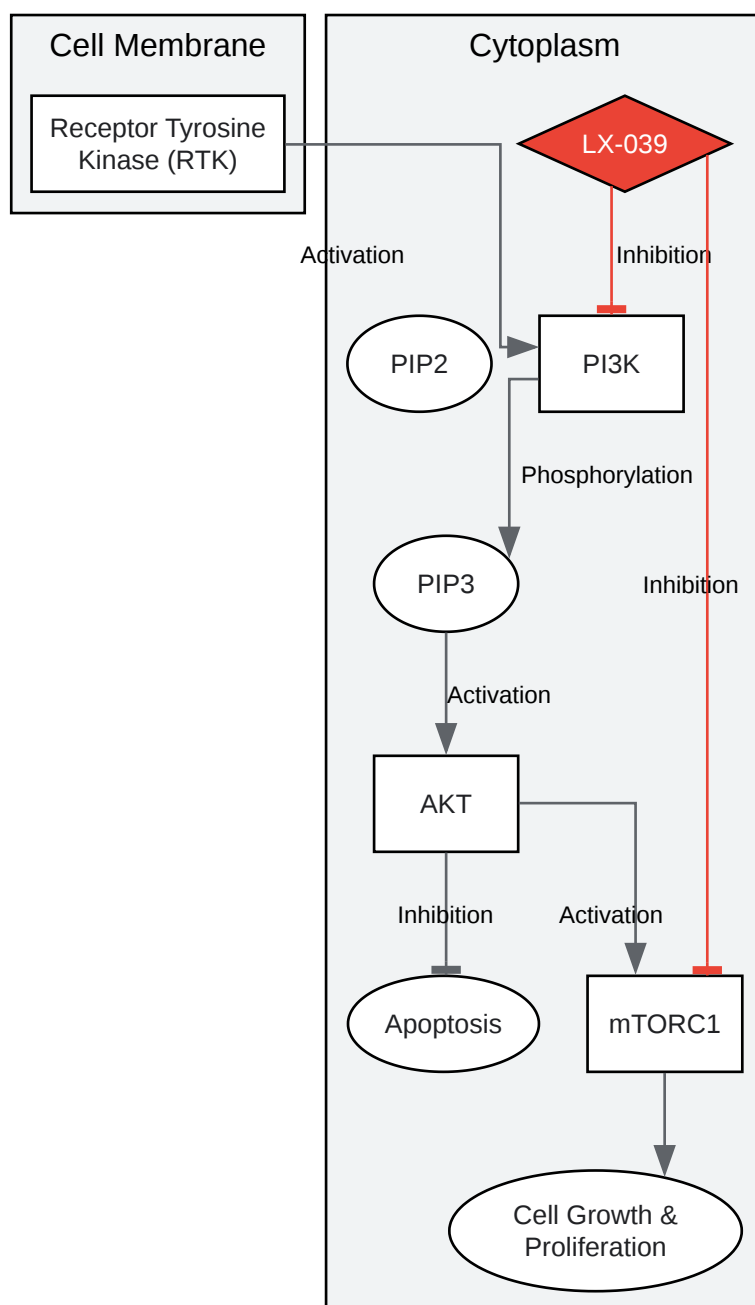
- Pulse Sequence: Utilize a single-shot echo-planar imaging (EPI) sequence.
- b-values: Acquire images with at least two b-values (e.g., 0 and 1000 s/mm²). For more detailed analysis, a multi-b-value acquisition is recommended.
- Image Analysis: Generate ADC maps from the DWI data. Perform region of interest (ROI) analysis on the tumor to calculate the mean ADC value. A post-treatment increase in ADC is indicative of a positive therapeutic response.[\[5\]](#)

IV. Data Presentation

Table 1: Summary of Imaging Biomarkers for LX-039 Treatment Response

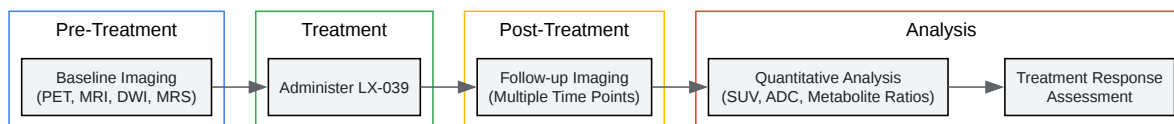
| Imaging Modality | Biomarker | Expected Change with Effective Treatment | Time to Observe Change |
|-------------------|-----------------------|--|------------------------|
| 18F-FDG PET | SUVmax / SUVmean | Decrease | Hours to Days |
| 18F-FLT PET | SUVmax / SUVmean | Decrease | Days |
| DWI | ADC | Increase | Days |
| MRS | Choline/Citrate Ratio | Decrease | Days to Weeks |
| Anatomical MRI/CT | Tumor Volume (RECIST) | Decrease | Weeks to Months |

V. Visualizations



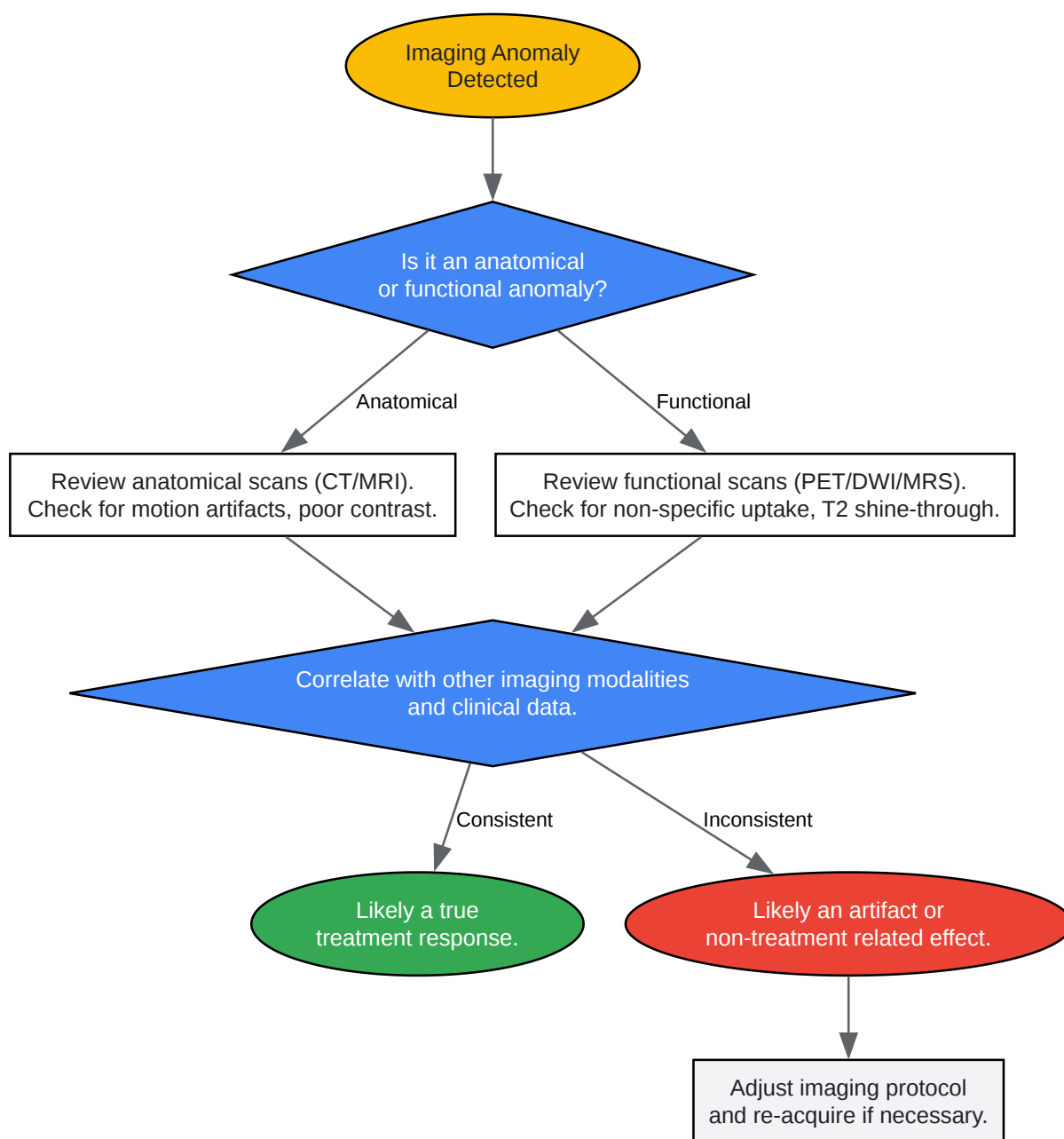
[Click to download full resolution via product page](#)

Caption: **LX-039** inhibits the PI3K/AKT/mTOR signaling pathway.



[Click to download full resolution via product page](#)

Caption: Workflow for imaging **LX-039** treated tumors.



[Click to download full resolution via product page](#)

Caption: Troubleshooting logic for imaging anomalies.

Need Custom Synthesis?

BenchChem offers custom synthesis for rare earth carbides and specific isotopic labeling.

Email: info@benchchem.com or [Request Quote Online](#).

References

- 1. Non-invasive imaging of PI3K/Akt/mTOR signalling in cancer - PMC [pmc.ncbi.nlm.nih.gov]
- 2. Non-invasive imaging of PI3K/Akt/mTOR signalling in cancer. | Semantic Scholar [semanticscholar.org]
- 3. Frontiers | PI3K/Akt/mTOR Pathway and Its Role in Cancer Therapeutics: Are We Making Headway? [frontiersin.org]
- 4. An Update on MR Spectroscopy in Cancer Management: Advances in Instrumentation, Acquisition, and Analysis - PMC [pmc.ncbi.nlm.nih.gov]
- 5. Diffusion-Weighted Imaging in Oncology: An Update - PMC [pmc.ncbi.nlm.nih.gov]
- 6. tandfonline.com [tandfonline.com]
- 7. Cancer not detected by PET scan: Why Some Tumors Are Missed on Imaging [int.livhospital.com]
- 8. MRI for Cancer | Magnetic Resonance Imaging Test | American Cancer Society [cancer.org]
- 9. Use of metabolic imaging to monitor heterogeneity of tumour response following therapeutic mTORC1/2 pathway inhibition - PMC [pmc.ncbi.nlm.nih.gov]
- 10. Can an MRI Tell If a Tumor Is Benign? | Tisch Brain Tumor Center [tischbraintumorcenter.duke.edu]
- 11. Can an MRI Detect Cancer? What It Can and Can't Detect [healthline.com]
- 12. Pitfalls in PET/CT oncologic imaging: A series of interesting cases | Journal of Nuclear Medicine [jnm.snmjournals.org]
- 13. auntminnieeurope.com [auntminnieeurope.com]
- 14. egr.msu.edu [egr.msu.edu]
- 15. Pitfalls on PET/CT due to artifacts and instrumentation - PMC [pmc.ncbi.nlm.nih.gov]
- 16. Problems with MRI for Cancer Diagnosis [ctoam.com]
- 17. Diffusion-Weighted Magnetic Resonance Imaging as a Cancer Biomarker: Consensus and Recommendations - PMC [pmc.ncbi.nlm.nih.gov]
- 18. Principles and Applications of Diffusion-weighted Imaging in Cancer Detection, Staging, and Treatment Follow-up - PMC [pmc.ncbi.nlm.nih.gov]

- To cite this document: BenchChem. [Technical Support Center: Optimizing Imaging for LX-039 Treated Tumors]. BenchChem, [2025]. [Online PDF]. Available at: [https://www.benchchem.com/product/b15142904#optimizing-imaging-techniques-for-lx-039-treated-tumors]

Disclaimer & Data Validity:

The information provided in this document is for Research Use Only (RUO) and is strictly not intended for diagnostic or therapeutic procedures. While BenchChem strives to provide accurate protocols, we make no warranties, express or implied, regarding the fitness of this product for every specific experimental setup.

Technical Support: The protocols provided are for reference purposes. Unsure if this reagent suits your experiment? [[Contact our Ph.D. Support Team for a compatibility check](#)]

Need Industrial/Bulk Grade? [Request Custom Synthesis Quote](#)

BenchChem

Our mission is to be the trusted global source of essential and advanced chemicals, empowering scientists and researchers to drive progress in science and industry.

Contact

Address: 3281 E Guasti Rd
Ontario, CA 91761, United States
Phone: (601) 213-4426
Email: info@benchchem.com