

# Technical Support Center: Optimizing HIDA Scan Image Acquisition

**Author:** BenchChem Technical Support Team. **Date:** December 2025

## Compound of Interest

Compound Name: *Technetium Tc 99m mebrofenin*

Cat. No.: *B1243543*

[Get Quote](#)

This technical support center provides troubleshooting guides and frequently asked questions (FAQs) to assist researchers, scientists, and drug development professionals in optimizing image acquisition parameters for Hepatobiliary Iminodiacetic Acid (HIDA) scans.

## Troubleshooting Guide

This guide addresses specific issues that may arise during HIDA scan experiments, along with recommended solutions.

Issue	Potential Cause(s)	Recommended Action(s)
Non-visualization of the gallbladder within 60 minutes	<p>1. Cystic duct obstruction (Acute Cholecystitis): This is the most common cause.<a href="#">[1]</a> 2. Prolonged Fasting (&gt;24 hours): The gallbladder is full of viscous bile, preventing radiotracer entry.<a href="#">[1]</a> 3. Total Parenteral Nutrition (TPN): Lack of oral intake leads to gallbladder stasis.<a href="#">[1]</a> 4. Severe Hepatocellular Disease: Impaired liver function results in poor uptake and excretion of the radiotracer.<a href="#">[1]</a> 5. Recent Opiate Use: Opiates can cause spasm of the sphincter of Oddi, mimicking a blockage.<a href="#">[1]</a> 6. Chronic Cholecystitis: Severe inflammation can lead to a non-functional gallbladder.<a href="#">[1]</a></p>	<p>1. Administer Morphine: If there is no visualization after 60 minutes, morphine can be administered to differentiate true obstruction from functional issues. Non-visualization 30 minutes post-morphine is highly indicative of acute cholecystitis.<a href="#">[1]</a> 2. Pre-treat with Sincalide (CCK): For patients with prolonged fasting or on TPN, pre-treat with sincalide 30-60 minutes before the radiotracer to empty the gallbladder.<a href="#">[1]</a><a href="#">[2]</a> 3. Consider Alternative Imaging: In cases of severe liver disease, a HIDA scan may not be diagnostic. 4. Discontinue Opiates: Ensure opiates have been discontinued for at least 6 hours prior to the scan.<a href="#">[1]</a></p>
Delayed Biliary-to-Bowel Transit (>60 minutes)	<p>1. Common Bile Duct Obstruction: A blockage in the common bile duct prevents the tracer from reaching the small intestine. 2. Sphincter of Oddi Dysfunction: The sphincter does not relax appropriately to allow bile to pass. 3. Recent Opiate Use: Opiates can cause the sphincter of Oddi to contract.<a href="#">[3]</a></p>	<p>1. Delayed Imaging: Continue imaging for up to 4 hours.<a href="#">[4]</a> 2. Morphine Administration: In some protocols, morphine can be used to challenge the sphincter of Oddi.<a href="#">[5]</a></p>

False-Positive for Acute Cholecystitis	1. Inadequate Fasting (<4 hours): Recent food intake can cause the gallbladder to be contracted. 2. Prolonged Fasting (>24 hours): Leads to a full, static gallbladder.[6] 3. Severe Liver Disease: Poor tracer uptake by the liver.[4] 4. Hyperbilirubinemia: High bilirubin levels can compete with the radiotracer for uptake. [4]	1. Strict Adherence to Fasting Protocols: Ensure the patient has fasted for 4-6 hours.[7] 2. Pre-treatment with Sincalide (CCK): For patients with prolonged fasting, administer sincalide prior to the scan.[2]

## Frequently Asked Questions (FAQs)

Q1: What is the standard radiopharmaceutical and dosage for a HIDA scan?

A1: The most commonly used radiopharmaceuticals are Technetium-99m (Tc-99m) labeled HIDA agents, such as Tc-99m mebrofenin or Tc-99m disofenin. The typical adult dose is 5-7 mCi (185-259 MBq) administered intravenously.[8][9]

Q2: What are the optimal image acquisition parameters?

A2: Standard acquisition parameters are summarized in the table below.

Parameter	Value
Gamma Camera	Large field of view with a low-energy, high-resolution collimator
Energy Window	15-20% centered at 140 keV[8][9]
Matrix Size	128x128 or 256x256[8][10]
Imaging Mode	Dynamic acquisition
Frame Rate	1 frame per minute for 60 minutes[6]

Q3: When is morphine augmentation indicated, and what is the protocol?

A3: Morphine augmentation is indicated when the gallbladder is not visualized within 60 minutes of radiotracer injection, despite visualization of the common bile duct and small bowel. [1] It helps differentiate acute cholecystitis from other causes of non-visualization. The standard protocol is to administer 0.04 mg/kg of morphine sulfate intravenously over 2-3 minutes, followed by an additional 30 minutes of imaging.[11]

Q4: What is the purpose of administering cholecystikinin (CCK) during a HIDA scan?

A4: Cholecystikinin (CCK), or its synthetic analog sincalide, is administered to stimulate gallbladder contraction and calculate the gallbladder ejection fraction (GBEF).[12] This is particularly useful in evaluating for chronic acalculous cholecystitis or biliary dyskinesia.

Q5: What is the standard protocol for CCK administration and GBEF calculation?

A5: After the gallbladder is visualized, sincalide is infused intravenously at a dose of 0.02 µg/kg over 30-60 minutes.[2][12] Dynamic imaging continues during and after the infusion to measure the GBEF. A GBEF of ≥38% is generally considered normal.[13][14]

## Experimental Protocols

### Standard HIDA Scan Protocol

- Patient Preparation: The patient should be fasting for a minimum of 4 hours but no longer than 24 hours prior to the scan.[1] Opiate medications should be withheld for at least 6 hours.[1]
- Radiopharmaceutical Administration: Administer 5-7 mCi of a Tc-99m labeled HIDA agent intravenously.[8][9]
- Image Acquisition:
  - Position the patient supine under a large field-of-view gamma camera with a low-energy, high-resolution collimator.
  - Begin dynamic imaging immediately after injection.

- Acquire images at 1 frame per minute for 60 minutes using a 128x128 or 256x256 matrix.  
[\[6\]](#)[\[8\]](#)[\[10\]](#)
- Initial Interpretation:
  - Normal: Visualization of the liver, biliary tree, gallbladder, and small bowel within 60 minutes.
  - Abnormal: Non-visualization of the gallbladder, delayed biliary-to-bowel transit, or tracer accumulation outside the biliary system.

## Morphine-Augmented HIDA Scan Protocol

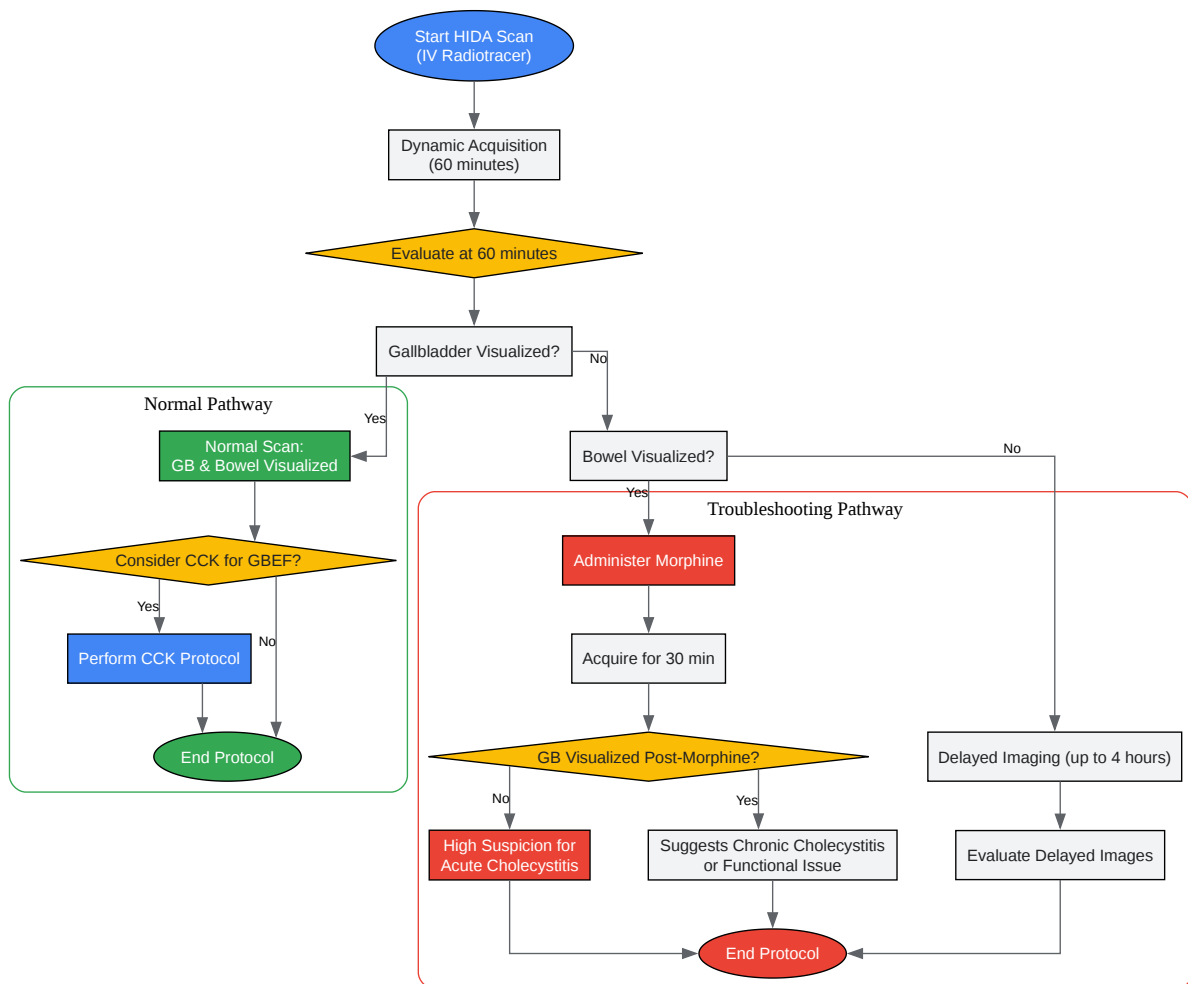
- Indication: This protocol is initiated if the gallbladder is not visualized at 60 minutes, but activity is present in the common bile duct and small bowel.[\[1\]](#)
- Morphine Administration: Administer 0.04 mg/kg of morphine sulfate intravenously over 2-3 minutes.[\[11\]](#)
- Continued Image Acquisition: Continue dynamic imaging for an additional 30 minutes.
- Interpretation:
  - Gallbladder Visualization: Rules out acute cholecystitis.
  - Gallbladder Non-visualization: Highly suggestive of acute cholecystitis.[\[1\]](#)

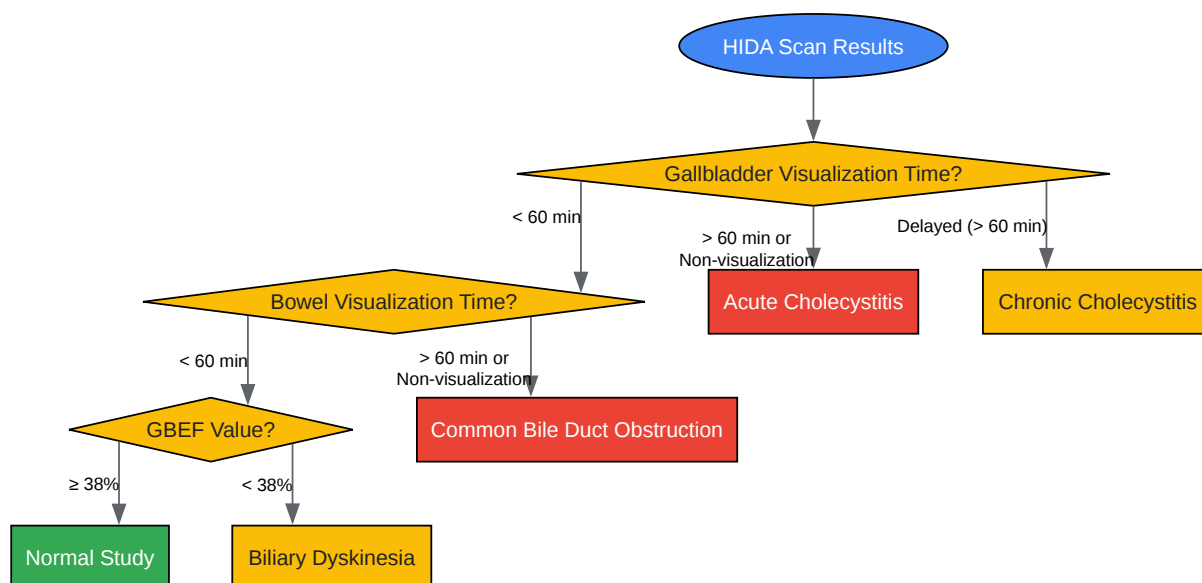
## CCK-Augmented HIDA Scan for GBEF

- Indication: To assess gallbladder function in patients with suspected chronic cholecystitis or biliary dyskinesia.
- Initial Imaging: Perform a standard HIDA scan until the gallbladder is maximally filled with the radiotracer (typically around 60 minutes).
- CCK (Sincalide) Administration: Infuse 0.02 µg/kg of sincalide intravenously over 30-60 minutes.[\[2\]](#)[\[12\]](#)

- Image Acquisition for GBEF: Acquire dynamic images for the duration of the infusion and for a post-infusion period.
- GBEF Calculation:
  - Draw regions of interest (ROIs) around the gallbladder and an adjacent background area.
  - Calculate the GBEF using the formula:  $\text{GBEF (\%)} = \frac{[(\text{Maximal gallbladder counts} - \text{Minimal gallbladder counts}) / \text{Maximal gallbladder counts}] \times 100$
- Interpretation:
  - Normal GBEF:  $\geq 38\%$ [\[13\]](#)[\[14\]](#)
  - Abnormal GBEF:  $< 38\%$  may indicate gallbladder dysfunction.[\[13\]](#)

## Visualizations





[Click to download full resolution via product page](#)

### Need Custom Synthesis?

BenchChem offers custom synthesis for rare earth carbides and specific isotopic labeling.

Email: [info@benchchem.com](mailto:info@benchchem.com) or [Request Quote Online](#).

## References

- 1. benchchem.com [benchchem.com]
- 2. auntminnie.com [auntminnie.com]
- 3. RiT radiology: Nonvisualization of the Gallbladder with HIDA Scan [radiologyinthaiblogspot.com]
- 4. Untitled Document [meddean.luc.edu]
- 5. cdn.ymaws.com [cdn.ymaws.com]



- 6. Hepatobiliary Iminodiacetic Acid Scan - StatPearls - NCBI Bookshelf [ncbi.nlm.nih.gov]
- 7. droracle.ai [droracle.ai]
- 8. Hida Scan – SPHP Radiology Protocols [temiprotocols.org]
- 9. medfordradiology.com [medfordradiology.com]
- 10. radiopaedia.org [radiopaedia.org]
- 11. Revisiting morphine-augmented hepatobiliary imaging for diagnosing acute cholecystitis: the potential pitfall of high false positive rate - PMC [pmc.ncbi.nlm.nih.gov]
- 12. Optimal hepatobiliary scintigraphy for gallbladder dyskinesia - PMC [pmc.ncbi.nlm.nih.gov]
- 13. droracle.ai [droracle.ai]
- 14. radiopaedia.org [radiopaedia.org]
- To cite this document: BenchChem. [Technical Support Center: Optimizing HIDA Scan Image Acquisition]. BenchChem, [2025]. [Online PDF]. Available at: [https://www.benchchem.com/product/b1243543#optimizing-image-acquisition-parameters-for-hida-scan]

---

#### Disclaimer & Data Validity:

The information provided in this document is for Research Use Only (RUO) and is strictly not intended for diagnostic or therapeutic procedures. While BenchChem strives to provide accurate protocols, we make no warranties, express or implied, regarding the fitness of this product for every specific experimental setup.

**Technical Support:** The protocols provided are for reference purposes. Unsure if this reagent suits your experiment? [[Contact our Ph.D. Support Team for a compatibility check](#)]

**Need Industrial/Bulk Grade?** [Request Custom Synthesis Quote](#)

# BenchChem

Our mission is to be the trusted global source of essential and advanced chemicals, empowering scientists and researchers to drive progress in science and industry.

## Contact

Address: 3281 E Guasti Rd

Ontario, CA 91761, United States

Phone: (601) 213-4426

Email: [info@benchchem.com](mailto:info@benchchem.com)