

Technical Support Center: Optimizing Gadoxetic Acid Dose for Cirrhotic Patients

Author: BenchChem Technical Support Team. **Date:** December 2025

Compound of Interest

Compound Name: *Gadoxetic acid*

Cat. No.: *B1262754*

[Get Quote](#)

This technical support center provides researchers, scientists, and drug development professionals with troubleshooting guides and frequently asked questions (FAQs) for optimizing **gadoxetic acid**-enhanced magnetic resonance imaging (MRI) in cirrhotic patients.

Frequently Asked Questions (FAQs)

Q1: Why is optimizing the **gadoxetic acid** dose crucial for cirrhotic patients?

A1: In cirrhotic patients, liver function is compromised, affecting the uptake and excretion of **gadoxetic acid**. Standard doses and imaging protocols may result in suboptimal liver enhancement, making it difficult to detect and characterize liver lesions accurately.^{[1][2]} Optimization is necessary to ensure adequate contrast enhancement for a reliable diagnosis.

Q2: How does cirrhosis affect the pharmacokinetics of **gadoxetic acid**?

A2: Cirrhosis leads to a reduction in the number and function of hepatocytes, which are responsible for taking up **gadoxetic acid** from the blood.^{[1][3]} This impaired uptake results in a slower and lower overall enhancement of the liver parenchyma during the hepatobiliary phase (HBP).^{[1][2]} Consequently, the contrast agent's plasma half-life is prolonged, and a larger proportion is excreted renally as a compensatory mechanism.^[1]

Q3: What is the standard dose of **gadoxetic acid**, and should it be adjusted for cirrhotic patients?

A3: The standard recommended dose of **gadoxetic acid** is 0.025 mmol/kg of body weight.[4][5] While this is the standard, some studies have explored the use of half-dose or double-dose in specific clinical scenarios. For instance, a half-dose might be considered in patients with severe renal impairment to minimize risks, though this may compromise image quality. Conversely, a double dose has been investigated to improve lesion-to-liver contrast in patients with moderate cirrhosis (Child-Pugh class B).[5] However, dose adjustments should be made cautiously and based on a careful risk-benefit assessment for each patient.

Q4: What are the key imaging phases in a **gadoxetic acid**-enhanced liver MRI for a cirrhotic patient?

A4: The essential phases include the late hepatic arterial phase, portal venous phase, transitional phase, and the hepatobiliary phase (HBP).[1] The arterial phase is crucial for detecting hypervascular lesions like hepatocellular carcinoma (HCC). The portal venous and transitional phases provide information about lesion washout. The HBP, typically acquired 20 minutes post-injection, is critical for differentiating lesions based on the presence or absence of functioning hepatocytes.[1][2]

Troubleshooting Guides

Issue 1: Suboptimal or Inadequate Hepatobiliary Phase (HBP) Enhancement

- Problem: The liver parenchyma does not show sufficient enhancement in the 20-minute HBP images, leading to poor lesion-to-liver contrast.
- Possible Causes:
 - Severe Liver Dysfunction: In patients with advanced cirrhosis (e.g., high Child-Pugh or MELD score), hepatocyte function is severely impaired, leading to reduced uptake of **gadoxetic acid**. [1][6]
 - Incorrect Timing of HBP Acquisition: A standard 20-minute delay may be too short for patients with severe cirrhosis, as contrast uptake is slower. [2]
 - Presence of Shunts: Arterial-portal or portal-systemic shunts can decrease the amount of contrast agent delivered to the liver parenchyma. [1]

- Solutions:
 - Adjust HBP Acquisition Time: For patients with moderate to severe cirrhosis, consider extending the delay time for HBP imaging to 30 minutes or even longer.[2] Monitoring the enhancement of the portal vein relative to the liver can help determine the optimal timing; an adequate HBP is often achieved when the liver parenchyma is significantly brighter than the portal vein.[1]
 - Assess Liver Function Prior to Imaging: Utilize liver function scores like Child-Pugh and MELD to anticipate the likelihood of suboptimal enhancement and plan the imaging protocol accordingly.[6]
 - Consider Alternative Contrast Agents: In cases of very severe liver dysfunction, a conventional extracellular gadolinium-based contrast agent might provide better diagnostic information during the dynamic phases, although the specific benefits of the HBP will be lost.

Issue 2: Arterial Phase Ringing Artifacts

- Problem: Motion-like artifacts appear during the arterial phase, obscuring the fine details of small hypervascular lesions.
- Possible Causes:
 - Transient Dyspnea: Some patients experience a temporary shortness of breath immediately after **gadoteric acid** injection, leading to motion artifacts.
 - High Injection Rate: A rapid injection can lead to a very concentrated bolus of contrast, which can cause artifacts.
- Solutions:
 - Patient Communication: Inform the patient about the possibility of transient dyspnea and instruct them on breath-holding techniques.
 - Optimize Injection Rate: Reducing the injection rate from 2 mL/s to 1 mL/s can sometimes mitigate these artifacts without significantly compromising arterial phase enhancement.[7]

Issue 3: Difficulty in Differentiating HCC from other Nodules

- Problem: Distinguishing between small hepatocellular carcinomas (HCCs) and benign regenerative or dysplastic nodules is challenging.
- Possible Causes:
 - Variable Enhancement Patterns: Early HCCs may not show the classic "wash-in, wash-out" pattern, and some benign nodules can have atypical enhancement features.
 - Suboptimal HBP Contrast: Insufficient contrast between the lesion and the surrounding liver in the HBP can make interpretation difficult.
- Solutions:
 - Utilize Ancillary Features: Look for ancillary imaging features that favor malignancy, such as mild-moderate T2 hyperintensity, restricted diffusion, and the absence of **gadoxetic acid** uptake in the HBP. Most HCCs will appear hypointense in the HBP due to a lack of functioning hepatocytes.^{[1][8]}
 - Optimize HBP Imaging: As described in Issue 1, ensure the HBP is adequately timed to maximize the lesion-to-liver contrast. Increasing the flip angle during HBP acquisition can also improve the conspicuity of hypointense lesions.

Data Presentation

Table 1: **Gadoxetic Acid** Dose and Injection Rate Comparison in Cirrhotic Patients

Parameter	Standard Protocol	Modified Protocol 1	Modified Protocol 2
Gadoxetic Acid Dose	0.025 mmol/kg	0.025 mmol/kg	0.05 mmol/kg (Double Dose)
Injection Rate	2 mL/s	1 mL/s	1-2 mL/s
Target Patient Group	Child-Pugh A	Patients with susceptibility to artifacts	Child-Pugh B
Observed Outcome	Standard enhancement	Reduced arterial phase artifacts, comparable image quality	Improved lesion-liver contrast in HBP
Reference	[4] [5]	[7]	[5]

Table 2: Recommended Hepatobiliary Phase (HBP) Delay Time Based on Liver Function

Liver Function Status	Child-Pugh Class	MELD Score	Recommended HBP Delay Time	Reference
Normal to Mildly Impaired	A (5-6 points)	< 10	10-20 minutes	[2]
Moderately Impaired	B (7-9 points)	10-15	20-30 minutes	[2] [6]
Severely Impaired	C (10-15 points)	> 15	> 30 minutes (consider viability)	[6]

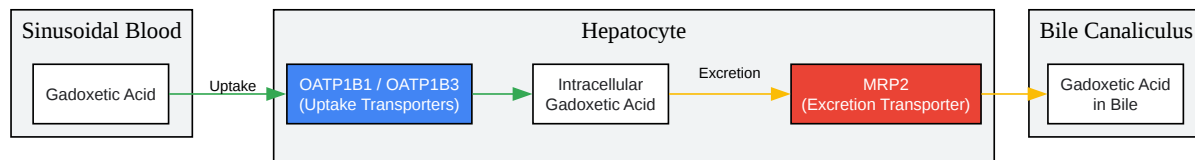
Experimental Protocols

Protocol 1: Quantitative Assessment of Liver Function using **Gadoxetic Acid**-Enhanced MRI

- Patient Preparation: Patients should fast for at least 4 hours prior to the MRI examination to minimize gallbladder contraction and optimize visualization of the biliary system.

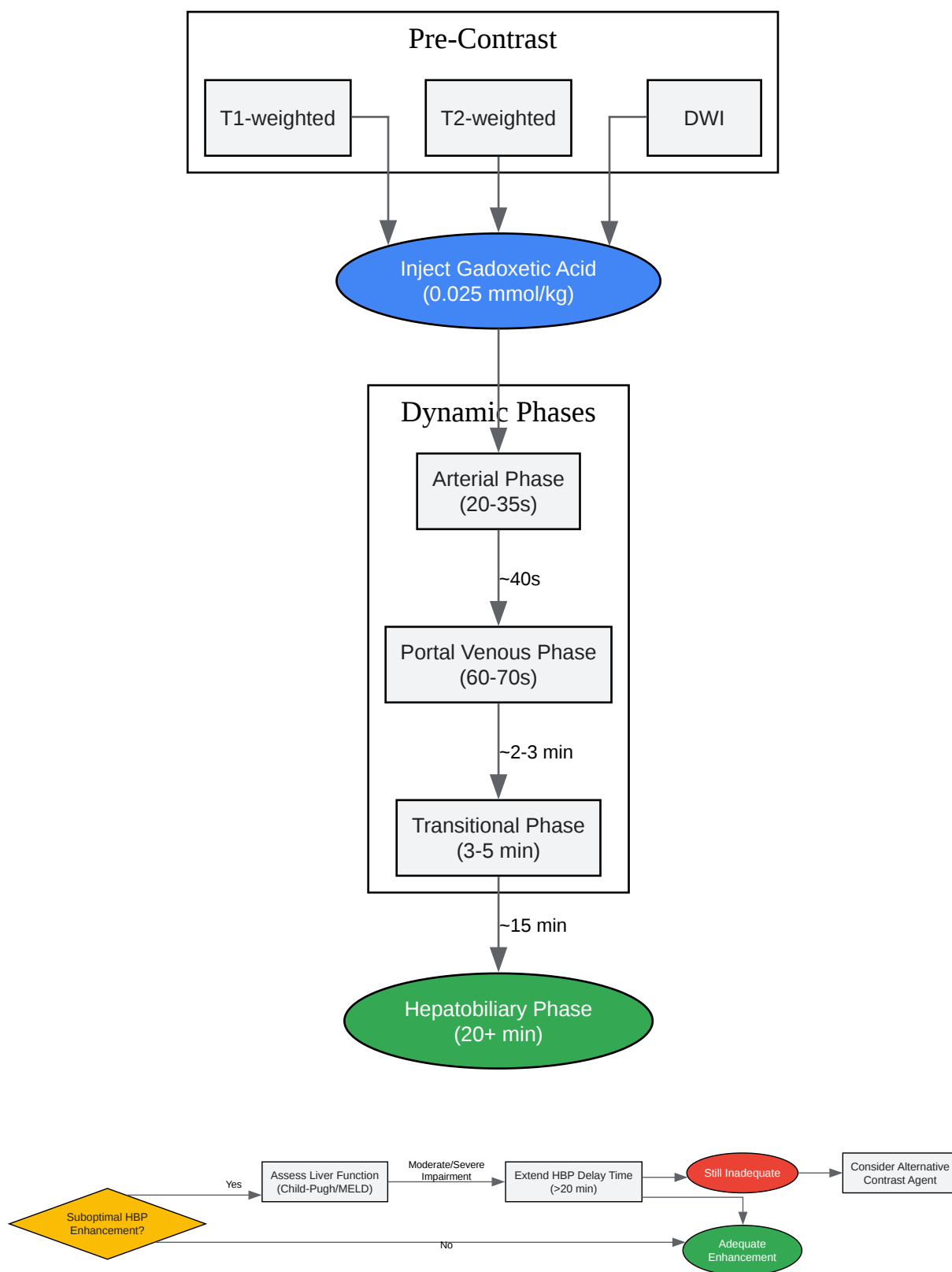
- Baseline Imaging: Acquire pre-contrast T1-weighted (in- and opposed-phase), T2-weighted, and diffusion-weighted imaging (DWI) sequences.
- Contrast Administration:
 - Administer a standard dose of 0.025 mmol/kg of **gadoxetic acid**.
 - Use a power injector at a rate of 1-2 mL/s, followed by a 20 mL saline flush.
- Dynamic Phase Imaging: Perform multiphasic T1-weighted gradient-echo imaging with fat suppression during the late hepatic arterial (approximately 20-35 seconds post-injection), portal venous (60-70 seconds), and transitional (3-5 minutes) phases.
- Hepatobiliary Phase Imaging: Acquire T1-weighted images with fat suppression at 20 minutes post-injection. For patients with known or suspected severe cirrhosis, consider additional delayed imaging at 30 or 40 minutes.
- Data Analysis:
 - Draw regions of interest (ROIs) on the liver parenchyma and spleen on pre-contrast and HBP images.
 - Calculate the relative liver enhancement (RLE) using the formula: $RLE = (SI_{liver_post} / SI_{liver_pre}) - 1$, where SI is the signal intensity.
 - Calculate the liver-to-spleen contrast ratio: $Contrast\ Ratio = (SI_{liver_post} / SI_{spleen_post})$.
 - Correlate these quantitative imaging biomarkers with clinical liver function scores (Child-Pugh, MELD).

Mandatory Visualization



[Click to download full resolution via product page](#)

Caption: Cellular uptake and excretion pathway of **gadoxetic acid** in a hepatocyte.



[Click to download full resolution via product page](#)

Need Custom Synthesis?

BenchChem offers custom synthesis for rare earth carbides and specific isotopic labeling.

Email: info@benchchem.com or [Request Quote Online](#).

References

- 1. Magnetic resonance imaging of the cirrhotic liver in the era of gadoxetic acid - PMC [pmc.ncbi.nlm.nih.gov]
- 2. Optimization of hepatobiliary phase imaging in gadoxetic acid-enhanced magnetic resonance imaging: a narrative review - Wang - Quantitative Imaging in Medicine and Surgery [qims.amegroups.org]
- 3. Quantification of liver function using gadoxetic acid-enhanced MRI - PMC [pmc.ncbi.nlm.nih.gov]
- 4. pdfs.semanticscholar.org [pdfs.semanticscholar.org]
- 5. ajronline.org [ajronline.org]
- 6. Hepatobiliary phase in cirrhotic patients with different Model for End-stage Liver Disease score: comparison of the performance of gadoxetic acid to gadobenate dimeglumine - PubMed [pubmed.ncbi.nlm.nih.gov]
- 7. Comparison of two different injection rates of gadoxetic acid for arterial phase MRI of the liver - PubMed [pubmed.ncbi.nlm.nih.gov]
- 8. Hepatocellular carcinoma 20 mm or smaller in cirrhosis patients: early magnetic resonance enhancement by gadoxetic acid compared with gadopentetate dimeglumine - PubMed [pubmed.ncbi.nlm.nih.gov]
- To cite this document: BenchChem. [Technical Support Center: Optimizing Gadoxetic Acid Dose for Cirrhotic Patients]. BenchChem, [2025]. [Online PDF]. Available at: [https://www.benchchem.com/product/b1262754#optimizing-gadoxetic-acid-dose-for-cirrhotic-patients]

Disclaimer & Data Validity:

The information provided in this document is for Research Use Only (RUO) and is strictly not intended for diagnostic or therapeutic procedures. While BenchChem strives to provide

accurate protocols, we make no warranties, express or implied, regarding the fitness of this product for every specific experimental setup.

Technical Support: The protocols provided are for reference purposes. Unsure if this reagent suits your experiment? [[Contact our Ph.D. Support Team for a compatibility check](#)]

Need Industrial/Bulk Grade? [Request Custom Synthesis Quote](#)

BenchChem

Our mission is to be the trusted global source of essential and advanced chemicals, empowering scientists and researchers to drive progress in science and industry.

Contact

Address: 3281 E Guasti Rd
Ontario, CA 91761, United States
Phone: (601) 213-4426
Email: info@benchchem.com