

Technical Support Center: Optimizing EHIDA Scan Interpretation in Jaundiced Patients

Author: BenchChem Technical Support Team. **Date:** December 2025

Compound of Interest

Compound Name: Ehida

Cat. No.: B1195364

[Get Quote](#)

This guide provides troubleshooting assistance and frequently asked questions (FAQs) for researchers, scientists, and drug development professionals utilizing Ethylenediaminediacetic acid (**EHIDA**) scans, also known as hepatobiliary scintigraphy or HIDA scans, in the context of hyperbilirubinemia.

Frequently Asked Questions (FAQs) & Troubleshooting

Q1: Why do elevated bilirubin levels complicate **EHIDA** scan interpretation?

Elevated serum bilirubin competes with Technetium-99m (Tc-99m) labeled iminodiacetic acid (IDA) derivatives, such as mebrofenin, for uptake and excretion by hepatocytes.^[1] This competition can lead to several confounding factors:

- **Reduced Hepatic Uptake:** The radiotracer may be less efficiently extracted from the blood by the liver cells.^[2]
- **Delayed Hepatobiliary Transit:** The movement of the tracer from the liver into the bile ducts is slowed.^{[3][4]}
- **Increased Renal Excretion:** A higher percentage of the radiotracer is cleared by the kidneys and excreted in the urine, reducing the amount available for biliary imaging.^{[3][4]}

- Diminished Image Quality: The combination of these factors can result in poor quality images, making interpretation difficult.[3]

Q2: How can I differentiate between high-grade biliary obstruction and severe hepatocellular dysfunction in a jaundiced patient?

This is a primary diagnostic challenge. Both conditions can result in delayed or absent visualization of the tracer in the bowel. Key differentiating features include:

- Hepatocellular Dysfunction: In severe liver disease, the initial uptake of the radiotracer by the liver is significantly impaired.[2][5] The liver appears faint on early images, and blood pool activity may remain high.[6]
- Biliary Obstruction: In cases of obstruction, the liver's ability to take up the tracer is often preserved.[7] Early images will show good, prompt hepatic uptake, but subsequent images will show a failure of the tracer to move into the small intestine, even on delayed views up to 24 hours.[7] Visualization of the tracer in the gallbladder and bowel at 24 hours can effectively rule out a high-grade obstruction.[7][8]

Q3: A scan of a jaundiced patient shows gallbladder non-visualization after 60-90 minutes. Does this confirm acute cholecystitis?

Not necessarily. While persistent non-visualization of the gallbladder is a key indicator of acute cholecystitis, severe hepatocellular disease or high-grade biliary obstruction can also cause this finding.[9] In patients with hyperbilirubinemia, delayed visualization is common.[3] It is critical to obtain delayed images at 3-4 hours, and sometimes up to 24 hours, to allow for the slow transit of the tracer.[10][11] A false-positive result for acute cholecystitis can also occur in patients with:

- Prolonged fasting (over 24 hours) or receiving total parenteral nutrition (TPN).[9][12]
- Severe intercurrent illness or sepsis.[3]
- Chronic cholecystitis.[1]

Q4: What protocol modifications are essential when scanning a patient with significant jaundice (e.g., bilirubin >5-10 mg/dL)?

To optimize results in jaundiced patients, several modifications to the standard **EHIDA** protocol are recommended:

- Radiopharmaceutical Choice: Use Tc-99m mebrofenin, which has superior hepatic excretion compared to other IDA derivatives in the presence of high bilirubin levels.[10][12]
- Dose Adjustment: The administered dose of Tc-99m mebrofenin may be increased. For patients with serum bilirubin greater than 1.5 mg/dL, a dose of 111-370 MBq (3-10 mCi) is suggested, compared to 74-185 MBq (2-5 mCi) for non-jaundiced patients.[3] Some protocols suggest a 1.5 to 2-fold dose increase if bilirubin is above 10 mg/dL.[13]
- Delayed Imaging: This is the most critical modification. Sequential imaging should be extended to 4 hours, with additional static images considered at 6 or 24 hours if the biliary tree or bowel are not visualized.[10][11]

Q5: When is pre-treatment with phenobarbital or sincalide indicated for jaundiced patients?

Pre-treatment is used in specific clinical scenarios to improve the diagnostic accuracy of the scan:

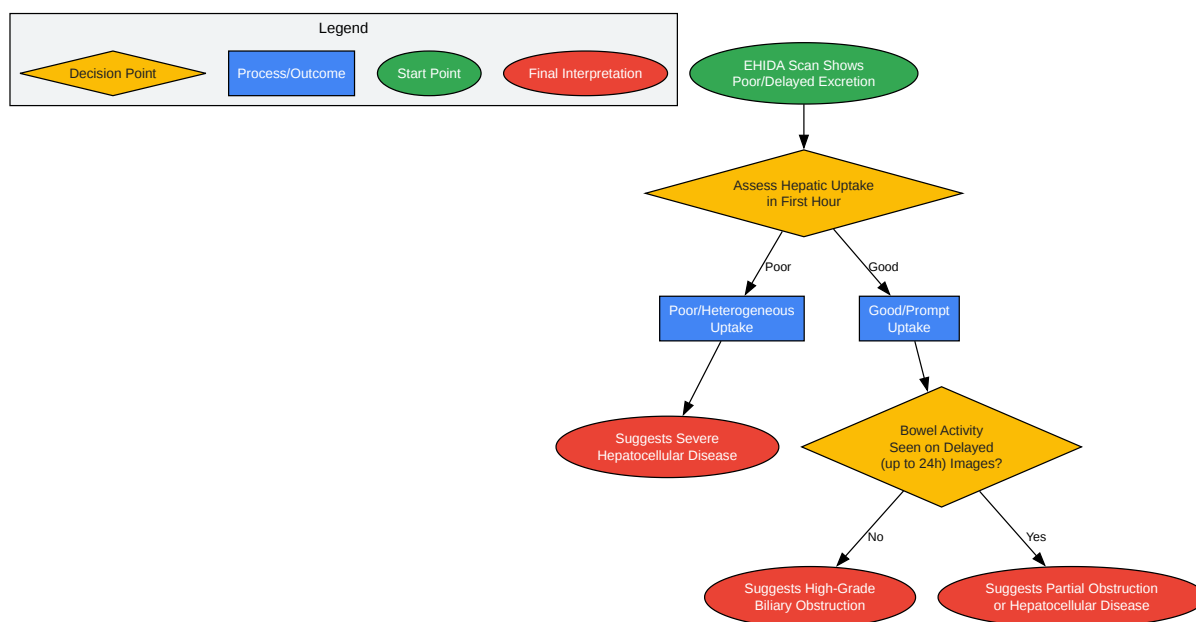
- Phenobarbital: Primarily used in the workup of neonatal jaundice to help differentiate biliary atresia from other causes of cholestasis.[14] Phenobarbital enhances the excretion of the radiotracer into the biliary system.[10][12] The standard dose is 5 mg/kg/day, administered orally in two divided doses for 3 to 5 days prior to the scan.[10][11][15]
- Sincalide (CCK Analog): This is not used because of jaundice itself, but for conditions that can cause false-positive gallbladder non-visualization. It is recommended for patients who have been fasting for more than 24 hours or are on TPN.[9][12] Sincalide stimulates the gallbladder to empty itself of viscous, sludge-like bile that could otherwise prevent the radiotracer from entering.[9][11] It should be administered 15-30 minutes before the radiotracer injection.[12]

Data Presentation

Table 1: Comparison of **EHIDA** Scan Parameters in Non-Jaundiced vs. Jaundiced Patients

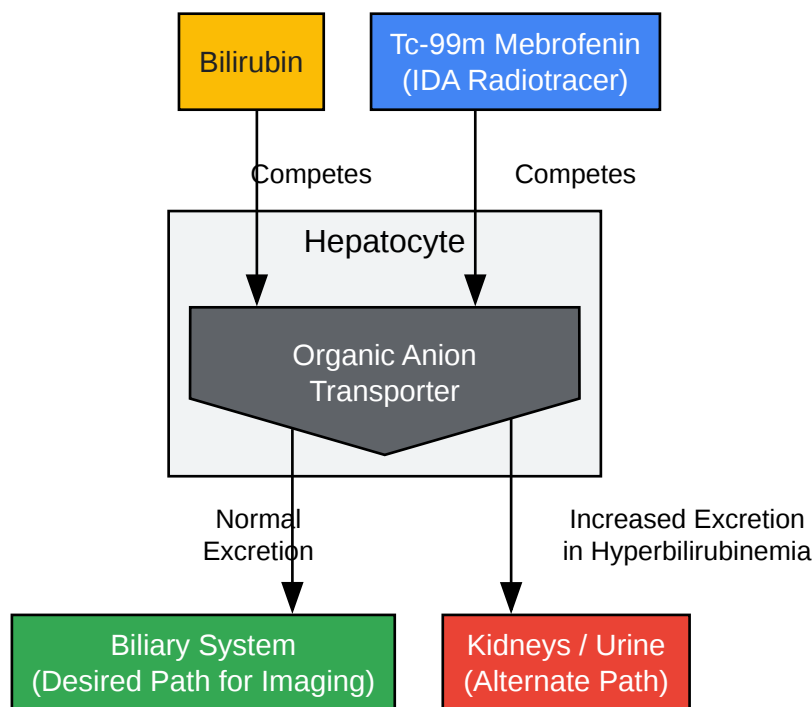
Parameter	Standard (Non-Jaundiced) Patient	Jaundiced Patient (Hyperbilirubinemia)	Citation(s)
Suggested Radiotracer	Tc-99m Mebrofenin or Disofenin	Tc-99m Mebrofenin (preferred)	[10][12]
Typical Adult Dose	74 - 185 MBq (2 - 5 mCi)	111 - 370 MBq (3 - 10 mCi)	[3]
Blood Clearance	~17% of injected dose in blood at 10 min	May be twice as high or more	[3][4]
Liver Visualization	By 5 minutes	Delayed	[3]
Max Liver Uptake	~11 minutes	Delayed	[3][4]
Gallbladder Visualization	10 - 15 minutes	Delayed; may require 4-24 hours	[3][10]
Intestinal Visualization	30 - 60 minutes	Delayed; may require 4-24 hours	[3][10]
Primary Excretion Route	Hepatobiliary	Increased Renal Excretion	[3][4]

Visualized Workflows and Pathways



[Click to download full resolution via product page](#)

Caption: Troubleshooting logic for differentiating hepatocellular disease from biliary obstruction.



[Click to download full resolution via product page](#)

Caption: Competitive mechanism between bilirubin and IDA radiotracer at the hepatocyte.

Experimental Protocols

Protocol: Optimized **EHIDA** Scintigraphy for Adult Jaundiced Patients

This protocol outlines a methodology for performing hepatobiliary scintigraphy in adult patients with hyperbilirubinemia to maximize diagnostic accuracy.

1. Patient Preparation

- Fasting: The patient must fast for a minimum of 2-6 hours prior to the study.[10][12] Fasting for longer than 24 hours should be noted, as it may require pre-treatment.[12]
- Medication Review: Opiate-based medications should be withheld for at least 6 hours before the scan, as they can induce functional obstruction at the Sphincter of Oddi.[11]
- Pre-treatment (if applicable):

- If the patient has been fasting for >24 hours or is on TPN, administer sincalide (0.02 µg/kg) intravenously over 30-60 minutes.[12] Wait at least 30 minutes after sincalide infusion is complete before injecting the radiotracer.[11]

2. Radiopharmaceutical and Dose

- Agent: Technetium-99m (Tc-99m) Mebrofenin.[10][12]
- Dose: Administer 111-370 MBq (3-10 mCi) intravenously.[3] The specific dose should be determined in consultation with a nuclear medicine physician, potentially increasing it for severely jaundiced patients.[13]

3. Imaging Acquisition

- Equipment: A large field-of-view gamma camera equipped with a low-energy, high-resolution collimator.
- Patient Positioning: The patient should be in the supine position with the camera detector placed anteriorly over the abdomen, ensuring the liver and small bowel are within the field of view.[11]
- Dynamic Acquisition:
 - Immediately upon injection, acquire dynamic images for 60 minutes.[11]
 - Framing rate: 60 frames at 1 minute/frame.[11]
- Static and Delayed Imaging:
 - If the gallbladder, common bile duct, and small intestine are not clearly visualized by 60 minutes, obtain additional static images.
 - Obtain a right lateral view to better distinguish the gallbladder from the duodenum.[4]
 - Acquire delayed static images at 2-4 hours post-injection.[10]
 - If intestinal activity is still not present, further delayed imaging at 18-24 hours may be required to rule out high-grade obstruction.[4][10]

4. Data Interpretation

- Hepatic Function: Assess the promptness and homogeneity of liver uptake.
- Biliary Patency: Document the time to visualization of the intrahepatic ducts, common bile duct, gallbladder, and small intestine.
- Key Findings in Jaundice:
 - Normal: Even if delayed, visualization of tracer in the gallbladder and small bowel within 4-24 hours rules out high-grade obstruction and acute cholecystitis.
 - Obstruction: Good hepatic uptake with persistent non-visualization of tracer in the small bowel at 24 hours is indicative of high-grade obstruction.[7]
 - Hepatocellular Disease: Poor initial hepatic uptake with prolonged blood pool activity and delayed transit throughout the system.[2][6]

Need Custom Synthesis?

BenchChem offers custom synthesis for rare earth carbides and specific isotopic labeling.

Email: info@benchchem.com or [Request Quote Online](#).

References

- 1. cdn.mdedge.com [cdn.mdedge.com]
- 2. Challenges in Diagnosing and Managing Acute Cholecystitis in Cirrhosis - PMC [[pmc.ncbi.nlm.nih.gov](https://pubmed.ncbi.nlm.nih.gov/30111111/)]
- 3. [drugs.com](https://www.drugs.com) [[drugs.com](https://www.drugs.com)]
- 4. [nucmedtutorials.com](https://www.nucmedtutorials.com) [[nucmedtutorials.com](https://www.nucmedtutorials.com)]
- 5. HIDA scanning in gall-bladder disease - PubMed [[pubmed.ncbi.nlm.nih.gov](https://pubmed.ncbi.nlm.nih.gov/10111111/)]
- 6. [droracle.ai](https://www.droracle.ai) [[droracle.ai](https://www.droracle.ai)]
- 7. [tech.snmjournals.org](https://www.tech.snmjournals.org) [[tech.snmjournals.org](https://www.tech.snmjournals.org)]
- 8. [mdsearchlight.com](https://www.mdsearchlight.com) [[mdsearchlight.com](https://www.mdsearchlight.com)]

- 9. tech.snmjournals.org [tech.snmjournals.org]
- 10. snmmi.org [snmmi.org]
- 11. Hepatobiliary Iminodiacetic Acid Scan - StatPearls - NCBI Bookshelf [ncbi.nlm.nih.gov]
- 12. tech.snmjournals.org [tech.snmjournals.org]
- 13. radiology.wisc.edu [radiology.wisc.edu]
- 14. jnm.snmjournals.org [jnm.snmjournals.org]
- 15. radiology.unm.edu [radiology.unm.edu]
- To cite this document: BenchChem. [Technical Support Center: Optimizing EHIDA Scan Interpretation in Jaundiced Patients]. BenchChem, [2025]. [Online PDF]. Available at: [<https://www.benchchem.com/product/b1195364#optimizing-ehida-scan-interpretation-in-jaundiced-patients>]

Disclaimer & Data Validity:

The information provided in this document is for Research Use Only (RUO) and is strictly not intended for diagnostic or therapeutic procedures. While BenchChem strives to provide accurate protocols, we make no warranties, express or implied, regarding the fitness of this product for every specific experimental setup.

Technical Support: The protocols provided are for reference purposes. Unsure if this reagent suits your experiment? [[Contact our Ph.D. Support Team for a compatibility check](#)]

Need Industrial/Bulk Grade? [Request Custom Synthesis Quote](#)

BenchChem

Our mission is to be the trusted global source of essential and advanced chemicals, empowering scientists and researchers to drive progress in science and industry.

Contact

Address: 3281 E Guasti Rd
Ontario, CA 91761, United States
Phone: (601) 213-4426
Email: info@benchchem.com