

# Technical Support Center: Optimizing 2D Echocardiography Image Quality

**Author:** BenchChem Technical Support Team. **Date:** December 2025

## Compound of Interest

Compound Name: M-MoDE-A (2)

Cat. No.: B15144752

[Get Quote](#)

This technical support center provides troubleshooting guides and frequently asked questions (FAQs) to assist researchers, scientists, and drug development professionals in optimizing 2D echocardiography (echo) image quality for accurate cardiac chamber quantification.

## Frequently Asked Questions (FAQs)

Q1: What are the most critical initial steps for obtaining high-quality 2D echo images?

A1: The foundational steps for acquiring optimal 2D echo images involve patient positioning, transducer selection, and obtaining standard imaging windows. Proper patient positioning, typically the left lateral decubitus position, brings the heart closer to the chest wall, improving the acoustic window.<sup>[1][2][3][4]</sup> Selecting the appropriate transducer frequency is also crucial; higher frequencies offer better resolution for superficial structures, while lower frequencies are needed for deeper penetration.<sup>[5]</sup> Finally, systematically obtaining the standard parasternal, apical, subcostal, and suprasternal notch views is essential for comprehensive and standardized imaging.

Q2: How do I optimize the basic machine settings for the best image quality?

A2: Optimizing machine settings is a dynamic process of balancing several parameters. Key adjustments include:

- **Gain:** This setting amplifies the returning echo signals. An overly high gain will make the image too bright ("whited out"), obscuring details, while a very low gain will result in a dark

image with poor tissue definition. The goal is to have a well-defined endocardial border with the blood pool appearing dark.

- **Time Gain Compensation (TGC):** TGC allows for the selective amplification of signals at different depths to compensate for the natural attenuation of the ultrasound beam as it travels through tissue. This should be adjusted to create a uniform brightness from the near field to the far field.
- **Depth:** The imaging depth should be set to include the entire cardiac structure of interest while minimizing extraneous space, which can improve the frame rate.
- **Focus:** Adjust the focal zone to the level of the structure of interest, such as the mitral valve leaflets or the left ventricular endocardium, to improve lateral resolution in that specific area.
- **Sector Width:** A narrower sector width can increase the frame rate and improve image quality, so it's beneficial to narrow the sector to the region of interest.

Q3: What is the importance of frame rate, and how can I optimize it?

A3: Frame rate, or temporal resolution, is critical for accurately assessing the motion of cardiac structures. A higher frame rate provides more images per second, leading to a smoother and more detailed depiction of the cardiac cycle. To optimize the frame rate, you can:

- Decrease the imaging depth.
- Narrow the sector width.
- Reduce the number of focal zones.
- Utilize advanced imaging technologies if available, such as those that use divergent transmit beams to cover the same region with fewer transmits. A frame rate of 60-90 Hz is generally recommended for clear endocardial border definition.

Q4: What are common image artifacts, and how can I mitigate them?

A4: Image artifacts can lead to misinterpretation and inaccurate measurements. Common artifacts include:

- **Acoustic Shadowing:** This occurs when the ultrasound beam is blocked by a dense structure like a prosthetic valve or calcification, creating a dark area behind it. To mitigate this, try imaging from different acoustic windows or adjusting the transducer angle.
- **Reverberation:** These appear as multiple, parallel echoes deep to a strong reflector. Reducing the gain and changing the imaging plane can help minimize these artifacts. M-mode can also be used to differentiate reverberations from true structures.
- **Mirror Image:** This artifact displays a structure on the opposite side of a strong, curved reflector. Changing the scanning plane and incident angle can help identify and eliminate this.
- **Near Field Clutter:** This is a bright, hazy area in the near field of the image. It can often be reduced by decreasing the near-field gain or using harmonic imaging.

Q5: When should I consider using an ultrasound contrast agent?

A5: Ultrasound contrast agents are beneficial when endocardial border definition is suboptimal in two or more contiguous segments of the left ventricle. Poor endocardial definition can lead to significant intra- and inter-observer variability in chamber quantification. Contrast agents improve the delineation of the endocardium, leading to more accurate and reproducible measurements of ventricular volumes and ejection fraction.

## Troubleshooting Guides

Issue: Poor Endocardial Border Definition

Potential Cause	Troubleshooting Steps
Suboptimal Patient Positioning	Ensure the patient is in a steep left lateral decubitus position. Use a cutout mattress if available to allow for better apical visualization and avoid foreshortening.
Incorrect Gain/TGC Settings	Adjust overall gain so the blood pool is dark and the myocardium is a medium gray. Fine-tune TGC to create uniform brightness across the image depth.
Inappropriate Transducer Frequency	For deeper structures, switch to a lower frequency transducer. For better resolution of nearer structures, use a higher frequency.
Off-axis Imaging	Ensure you are imaging perpendicular to the long axis of the ventricle for linear measurements. Avoid oblique sections which can lead to overestimation of dimensions.
Lung or Rib Interference	Have the patient hold their breath at end-expiration. Slide the transducer up or down an intercostal space to find a better acoustic window.
Inadequate Image Quality in >2 Segments	Consider using an intravenous ultrasound contrast agent to enhance endocardial border delineation.

Issue: Inaccurate Chamber Measurements

Potential Cause	Troubleshooting Steps
Foreshortening of the Apex	Ensure you are visualizing the true apex of the left ventricle in apical views. The apex should appear rounded, not "cut off." This may require moving the transducer inferiorly and laterally.
Incorrect Timing of Measurements	End-diastole is typically measured at the onset of the QRS complex, and end-systole is the frame just before mitral valve opening.
Inclusion of Papillary Muscles in Tracing	When performing volumetric measurements, the papillary muscles should be excluded from the cavity tracing.
Measurement from M-mode on an Oblique Axis	Prefer 2D-guided linear measurements over M-mode to avoid oblique sections of the ventricle.
Inconsistent Measurement Technique	Adhere to standardized measurement locations as recommended by guidelines (e.g., linear LV measurements just below the mitral valve leaflet tips). All chamber measurements should be made from inner-edge to inner-edge.
Not Averaging Measurements	For patients in sinus rhythm, average measurements over three cardiac cycles. For patients with atrial fibrillation, a minimum of five beats should be averaged.

## Quantitative Data Summary

Table 1: Recommended 2D Echocardiography Machine Settings for Optimal Image Quality

Parameter	Recommendation	Rationale
Frame Rate	60-90 Hz	Ensures clear visualization of endocardial borders and cardiac motion.
Depth	Minimized to include the structure of interest	Increases frame rate and improves resolution.
Sector Width	Narrowed to the region of interest	Increases frame rate and image quality.
Focus	Positioned at the level of the structure of interest	Improves lateral resolution at the desired depth.
Gain	Adjusted for a dark blood pool and clear tissue definition	Prevents "whiting out" or darkening of the image, which can obscure borders.
TGC	Adjusted for uniform brightness across the image	Compensates for signal attenuation with depth.
Harmonic Imaging	Generally recommended	Improves endocardial border definition, though normative values are mostly from fundamental imaging.

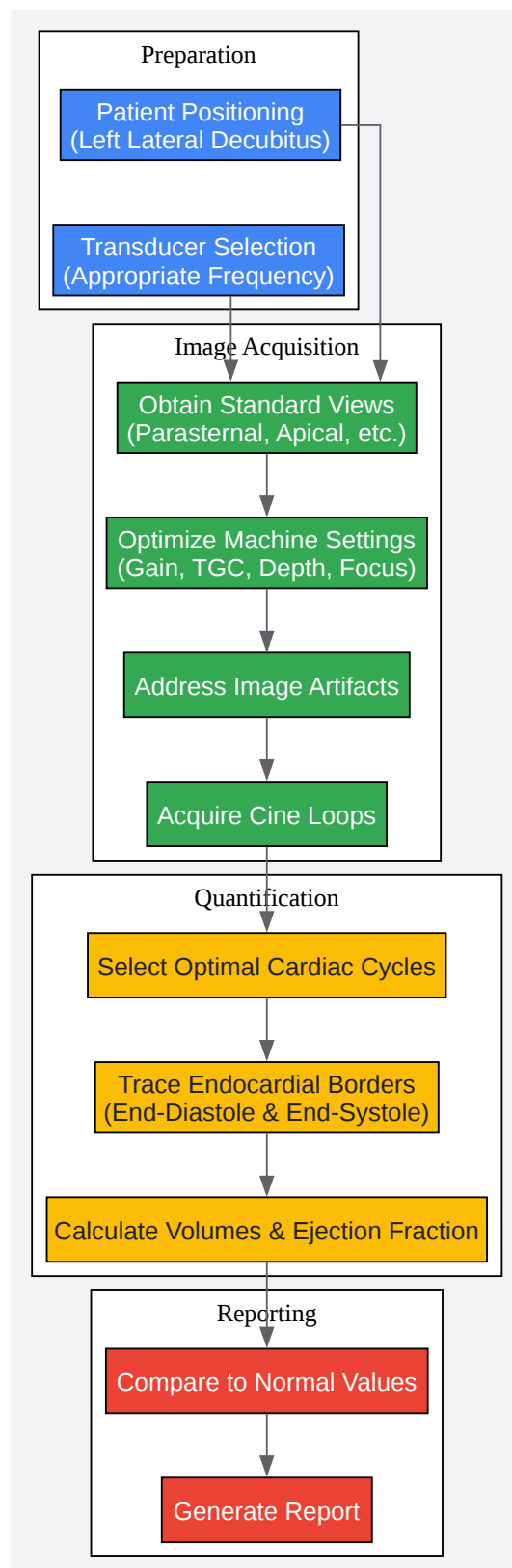
## Experimental Protocols

### Protocol 1: Standardized Acquisition of Apical 4-Chamber View for Left Ventricular Quantification

- **Patient Positioning:** Place the patient in the steep left lateral decubitus position. The patient's left arm should be raised above their head to open up the intercostal spaces.
- **Transducer Placement:** Locate the point of maximal impulse (PMI). Place the transducer at the PMI with the orientation marker directed towards the patient's left side (around the 3 o'clock position).
- **Image Optimization:**

- Adjust the depth to visualize the entire left ventricle from the mitral annulus to the apex.
- Narrow the sector width to focus on the left ventricle, which will increase the frame rate.
- Position the focal zone at the mid-ventricular level.
- Optimize gain and TGC for clear endocardial border definition.
- **Avoiding Foreshortening:** Ensure the left ventricle appears at its longest length and the apex is rounded. If the apex appears flattened, move the transducer one intercostal space lower or more laterally.
- **Image Acquisition:** Acquire a digital cine loop of at least three consecutive cardiac cycles during quiet respiration or end-expiration. For patients in atrial fibrillation, acquire a loop of at least five cycles.

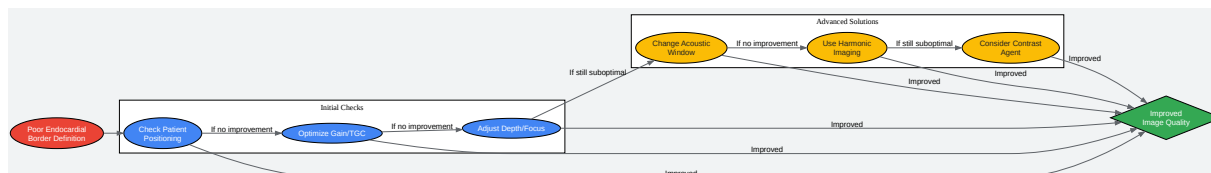
## Visualization Diagrams



[Click to download full resolution via product page](#)

Caption: Workflow for Accurate 2D Echo Chamber Quantification.





[Click to download full resolution via product page](#)

Caption: Troubleshooting Logic for Poor Endocardial Definition.

### Need Custom Synthesis?

BenchChem offers custom synthesis for rare earth carbides and specific isotopic labeling.

Email: [info@benchchem.com](mailto:info@benchchem.com) or [Request Quote Online](#).

## References

- 1. [ecgwaves.com](http://ecgwaves.com) [ecgwaves.com]
- 2. [clinicalpub.com](http://clinicalpub.com) [clinicalpub.com]
- 3. Cardiac Ultrasound (Echocardiography) Made Easy: Step-By-Step Guide - POCUS 101 [pocus101.com]
- 4. [asecho.org](http://asecho.org) [asecho.org]
- 5. [youtube.com](http://youtube.com) [youtube.com]

- To cite this document: BenchChem. [Technical Support Center: Optimizing 2D Echocardiography Image Quality]. BenchChem, [2025]. [Online PDF]. Available at: [https://www.benchchem.com/product/b15144752#optimizing-2d-echo-image-quality-for-accurate-chamber-quantification]

---

### Disclaimer & Data Validity:

The information provided in this document is for Research Use Only (RUO) and is strictly not intended for diagnostic or therapeutic procedures. While BenchChem strives to provide accurate protocols, we make no warranties, express or implied, regarding the fitness of this product for every specific experimental setup.

**Technical Support:** The protocols provided are for reference purposes. Unsure if this reagent suits your experiment? [[Contact our Ph.D. Support Team for a compatibility check](#)]

**Need Industrial/Bulk Grade?** [Request Custom Synthesis Quote](#)

## BenchChem

Our mission is to be the trusted global source of essential and advanced chemicals, empowering scientists and researchers to drive progress in science and industry.

### Contact

Address: 3281 E Guasti Rd  
Ontario, CA 91761, United States  
Phone: (601) 213-4426  
Email: [info@benchchem.com](mailto:info@benchchem.com)