

# Technical Support Center: Navigating the Conversion from DALK to Penetrating Keratoplasty

**Author:** BenchChem Technical Support Team. **Date:** December 2025

## Compound of Interest

Compound Name: dALK-3

Cat. No.: B15575147

[Get Quote](#)

This technical support center provides researchers, scientists, and drug development professionals with troubleshooting guides and frequently asked questions (FAQs) regarding the intraoperative conversion from Deep Anterior Lamellar Keratoplasty (DALK) to Penetrating Keratoplasty (PKP).

## Troubleshooting Guides

### Issue: Failure to Achieve a "Big Bubble"

Question: What are the common reasons for failing to create a big bubble during DALK, and what troubleshooting steps can be taken?

Answer:

Failure to achieve a big bubble, a critical step for separating Descemet's membrane (DM) from the corneal stroma, is a primary reason for intraoperative challenges that may lead to conversion to PKP.

Common Causes:

- **Incorrect Needle Depth:** The needle or cannula may be too superficial, causing air to dissect into the stromal lamellae rather than creating a single large bubble at the level of DM. Conversely, excessively deep placement risks perforating the DM.<sup>[1][2]</sup>

- Inadequate Air Injection Force: Insufficient or hesitant air injection may not provide enough pressure to create the cleavage plane.[1]
- Corneal Opacity: Pre-existing stromal scarring can impede the visualization of the needle tip and the progression of the bubble.[3][4]
- Previous Corneal Hydrops: In cases with a history of hydrops, the DM may have tears that allow air to escape into the anterior chamber.[1]

#### Troubleshooting Steps:

- Re-attempt Injection: If the first attempt fails, withdraw the needle and re-insert it at a different position within the trephined interface. Multiple attempts can be made.[1]
- Adjust Needle Depth: Ensure the needle tip is buried deep in the stroma, parallel to the posterior corneal surface, to facilitate dissection near the DM.[1][2] Some surgeons advocate for creating a small lamellar pocket to guide the cannula.[1]
- Confirm Bubble Presence: If corneal opacity obscures visualization, one can infer the presence of a big bubble by draining aqueous from the anterior chamber; the cornea over a successful bubble will remain firm in a soft eye.[5]
- Manual Dissection: If a big bubble cannot be formed, a layer-by-layer manual dissection can be attempted, though this carries a higher risk of perforation.[3][5]

## Issue: Intraoperative Descemet's Membrane Perforation

Question: How can a Descemet's membrane perforation during DALK be managed to avoid conversion to PKP?

Answer:

Intraoperative perforation of the Descemet's membrane (DM) is the most common reason for converting a DALK procedure to a PKP.[5][6][7] Management depends on the size and location of the tear.

Management Strategies:

- Microperforations:
  - Lower Intraocular Pressure (IOP): Perform a paracentesis to lower the IOP, which can help seal the perforation.[8]
  - Anterior Chamber Air/Gas Injection: Injecting air or gas into the anterior chamber can tamponade the tear and prevent further leakage.[8][9]
  - Viscoelastic Substance: A viscoelastic substance can be used to maintain the anterior chamber and seal the rupture.[8]
  - Careful Dissection: In the presence of a microperforation, dissection of the overlying stromal tissue must proceed with extreme caution to avoid extending the tear.[8] Leaving a small amount of residual stroma over the perforation can also be a protective measure.[8]
- Macroperforations:
  - While traditionally considered an indication for conversion to PKP, some techniques have been developed to manage larger tears.
  - Stromal Patch Suturing: A piece of the previously excised stromal tissue can be sutured to the edge of the trephination site to seal a large perforation, allowing the DALK procedure to be completed.[10]
  - Even with large perforations, some studies report successful completion of DALK with good visual outcomes, although complications like postoperative DM detachment are more common.[11]

## Frequently Asked Questions (FAQs)

What are the primary risk factors for conversion from DALK to PKP?

The primary risk factors for converting an intended DALK to a PKP include:

- Corneal Scarring: The presence of stromal scars significantly increases the risk of conversion.[3][4]

- Surgeon Inexperience: DALK has a steep learning curve, and surgeon inexperience is an independent risk factor for conversion.[3][4]
- Type of "Big Bubble" Achieved: The formation of a "Type 2" bubble (a cleavage plane within the pre-Descemet layer rather than directly above the DM) is strongly associated with a higher conversion rate, particularly if a DM-baring technique is attempted.[3][4][12]
- Need for Manual Dissection: Cases requiring manual layer-by-layer dissection have a much higher risk of perforation and subsequent conversion compared to those where pneumatic dissection is successful.[3][4]

What are the expected clinical outcomes if a conversion to PKP is necessary?

Multiple studies have compared the outcomes of patients who underwent a successful DALK with those whose procedure was converted to PKP. The results suggest that the clinical outcomes are often comparable.

- Visual Acuity: There is generally no statistically significant difference in the final best-corrected visual acuity (BCVA) between patients with a completed DALK and those converted to PKP.[6][7] Both groups typically experience a significant improvement in vision postoperatively.[6][13]
- Astigmatism: Postoperative astigmatism levels are also found to be similar between the two groups.[6][7]
- Graft Clarity: Grafts in converted PKP cases have been shown to remain clear, with outcomes comparable to planned PKP.[6]
- Complications: The rates of postoperative complications are not significantly different between the two groups.[6]

Is there a significant difference in endothelial cell loss between a successful DALK and a DALK converted to PKP?

Yes, this is a key differentiator. A primary advantage of DALK is the preservation of the patient's own endothelium, which avoids endothelial rejection and leads to better long-term endothelial cell survival.[10][14] In a PKP, the donor cornea includes a new endothelial layer, and a gradual

loss of endothelial cells is expected over time.[14][15] A conversion to PKP means the patient loses the endothelial benefits of DALK. One study noted that in cases of DM perforation during DALK that did not require conversion, the mean endothelial cell loss was significantly higher when air had to be left in the anterior chamber to manage the tear.[16]

## Data Presentation

Table 1: Comparison of Clinical Outcomes: Successful DALK vs. Conversion to PKP

Outcome Measure	Successful DALK Group	Converted to PKP Group	Statistical Significance	Source
Postoperative BCVA (logMAR)	0.34 ± 0.32	0.52 ± 0.69	p = 0.980 (Not Significant)	[17]
Postoperative Astigmatism (Diopters)	5.4 ± 1.8	5.8 ± 2.3	p = 0.430 (Not Significant)	[6]
Postoperative Central Corneal Thickness	No significant difference	No significant difference	p = 0.453 (Not Significant)	[6]
Graft Rejection (Endothelial)	Not possible	Occurs in a percentage of cases	Significant	[14][18]
Long-term Endothelial Cell Loss	Significantly lower	Significantly higher	Significant	[14]

Table 2: Risk Factors for Conversion from DALK to PKP

Risk Factor	Odds Ratio (OR)	Statistical Significance	Source
Corneal Scarring	3.52	$p < 0.001$	[3][4]
Manual Dissection Required	42.66	$p < 0.001$	[3]
Type 2 Bubble Formation	90.65	$p < 0.001$	[3]
Surgeon Inexperience	10.86	$p < 0.001$	[3][4]

## Experimental Protocols

### Protocol: Big-Bubble Deep Anterior Lamellar Keratoplasty (DALK) in a Research Setting (e.g., Porcine or Rabbit Model)

This protocol describes the general methodology for performing a big-bubble DALK, which can be adapted for animal models in a research environment to study surgical techniques, wound healing, or novel therapeutic interventions.

#### Materials:

- Animal model (e.g., ex vivo porcine eyes, in vivo rabbit model)
- Surgical microscope
- Vacuum trephine system
- Crescent blade
- 27-gauge or 30-gauge cannula with a bent tip, attached to a 5-10 mL air-filled syringe
- Surgical spears and forceps
- Viscoelastic substance

- Sutures (e.g., 10-0 nylon)
- Donor corneal tissue (if performing a full transplantation model)

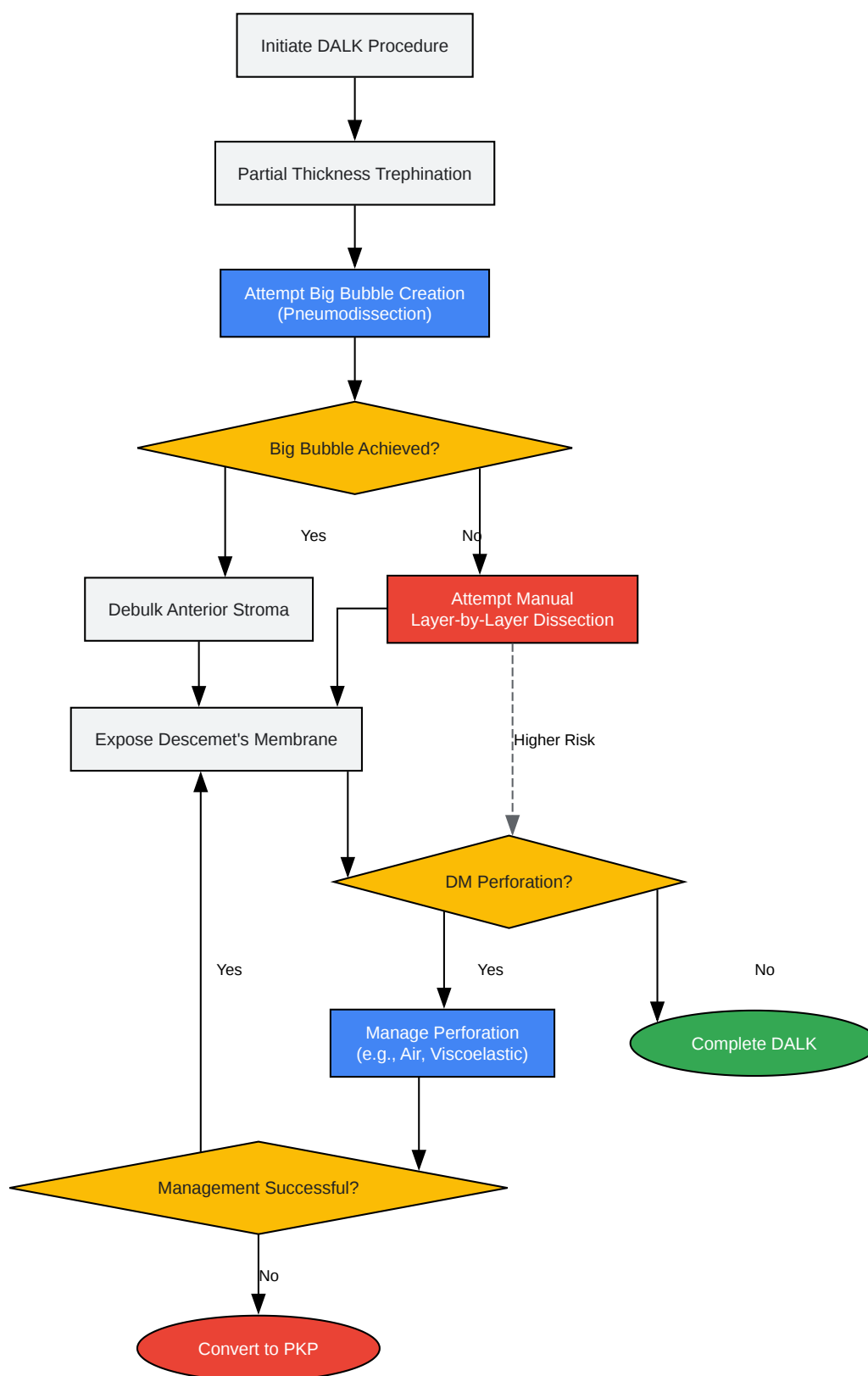
#### Methodology:

- Preparation: Secure the eye in a head holder. If using an in vivo model, ensure appropriate anesthesia and sterile preparation.
- Trephination: Set the vacuum trephine to a depth of approximately 75% of the corneal thickness. Apply the trephine to the central cornea and create a partial-thickness incision.[\[1\]](#)  
[\[19\]](#)
- Pneumodissection (Big-Bubble Creation):
  - Insert the bent 27G or 30G cannula, bevel-down, into the stromal bed at the base of the trephination groove.[\[1\]](#)
  - Advance the cannula 3-4 mm toward the center of the cornea, parallel to the iris plane.[\[1\]](#)
  - Inject air with firm, steady pressure. Observe for the formation of a "big bubble," which appears as a rapidly expanding, well-defined clear ring, indicating the separation of DM from the posterior stroma.[\[1\]](#)[\[5\]](#)
- Anterior Stromal Debulking:
  - Perform a paracentesis to lower the intraocular pressure.[\[1\]](#)
  - Use a crescent blade to perform a lamellar dissection, removing the anterior two-thirds of the stromal cap overlying the big bubble.[\[1\]](#)[\[19\]](#)
- Bubble Puncture and Stromal Removal:
  - Carefully puncture the anterior surface of the big bubble with a sharp blade or needle. A drop of viscoelastic placed on the surface can slow the egress of air and reduce the risk of DM perforation.[\[1\]](#)

- Use scissors and forceps to excise the remaining posterior stromal tissue from the surface of the now-exposed DM.
- Graft Placement (if applicable):
  - Prepare donor corneal tissue by removing its endothelial-DM layer.
  - Place the donor graft onto the recipient bed and secure it with interrupted and/or running sutures.

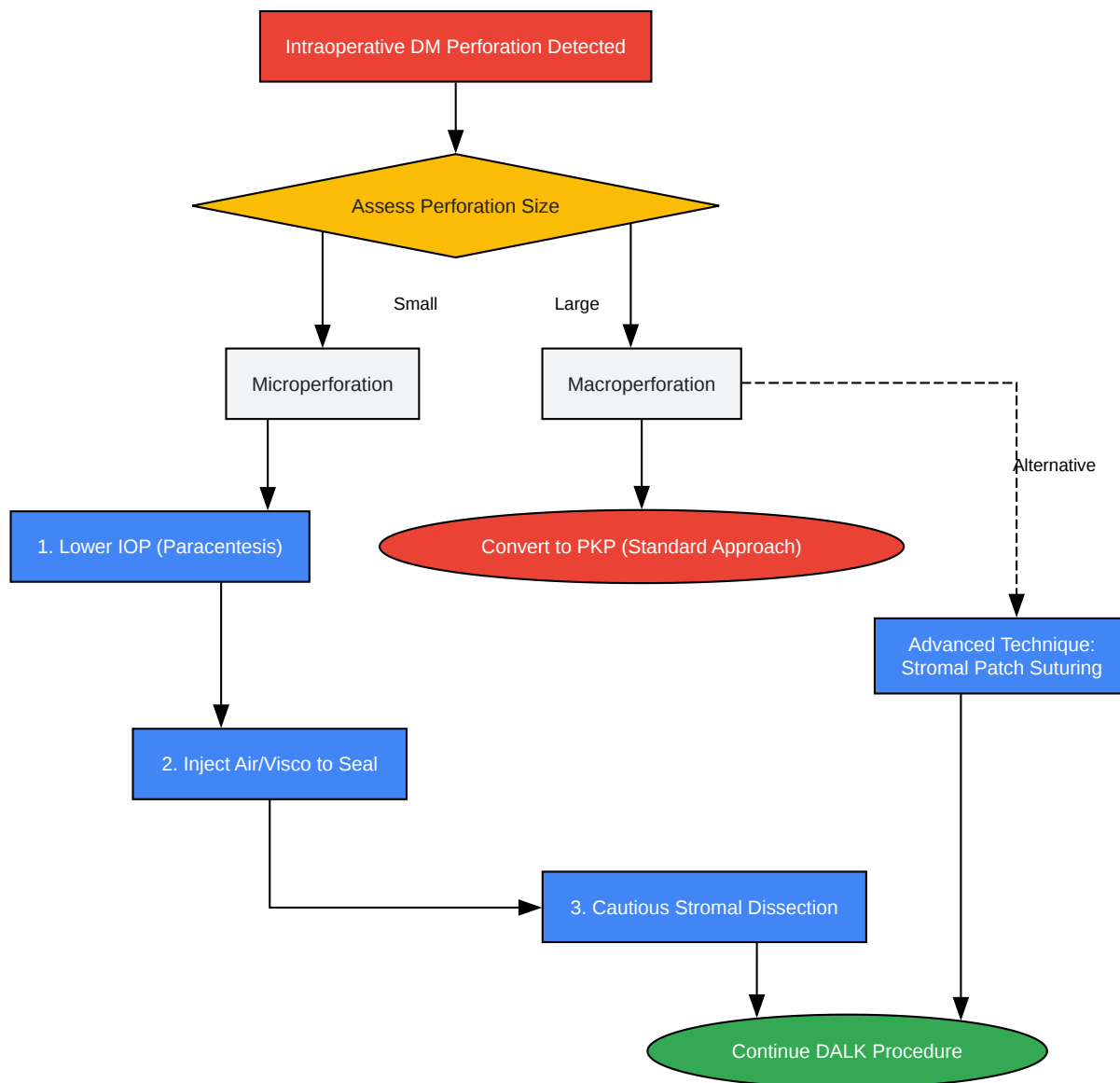## Visualizations





[Click to download full resolution via product page](#)

Caption: Workflow for DALK showing decision points for conversion to PKP.



[Click to download full resolution via product page](#)

Caption: Decision tree for managing Descemet's membrane perforations.

**Need Custom Synthesis?**

BenchChem offers custom synthesis for rare earth carbides and specific isotopic labeling.

Email: [info@benchchem.com](mailto:info@benchchem.com) or [Request Quote Online](#).

## References

- 1. DALK: Performing Big-Bubble Keratoplasty | Corneal Physician [pv-cp-staging.hbrsd.com]
- 2. google.com [google.com]
- 3. Evaluation of the risk factors associated with conversion of intended deep anterior lamellar keratoplasty to penetrating keratoplasty - ProQuest [proquest.com]
- 4. Evaluation of the risk factors associated with conversion of intended deep anterior lamellar keratoplasty to penetrating keratoplasty (2020) | James Myerscough | 26 Citations [scispace.com]
- 5. The Big Bubble Technique | Ento Key [entokey.com]
- 6. Comparison of Outcomes in Patients Who Underwent Deep Anterior Lamellar Keratoplasty and Those Converted to Penetrating Keratoplasty [pubmed.ncbi.nlm.nih.gov]
- 7. Comparison of Outcomes in Patients Who Underwent Deep Anterior Lamellar Keratoplasty and Those Converted to Penetrating Keratoplasty - PMC [pmc.ncbi.nlm.nih.gov]
- 8. Strategic Management of Descemet's Membrane Perforation During DALK in Advanced Keratoconus - PMC [pmc.ncbi.nlm.nih.gov]
- 9. Spontaneous resolution of double anterior chamber with perforation of Descemet's membrane in deep anterior lamellar keratoplasty - PMC [pmc.ncbi.nlm.nih.gov]
- 10. Novel Technique For The Management Of Macroperforation During Deep Anterior Lamellar Keratoplasty - PMC [pmc.ncbi.nlm.nih.gov]
- 11. sid.ir [sid.ir]
- 12. Management of Type 2 Bubble Formed During Big Bubble Deep Anterior Lamellar Keratoplasty - PubMed [pubmed.ncbi.nlm.nih.gov]
- 13. corneagen.com [corneagen.com]
- 14. bjo.bmj.com [bjo.bmj.com]
- 15. Penetrating Keratoplasty versus Deep Anterior Lamellar Keratoplasty for Keratoconus: A Systematic Review and Meta-analysis - PMC [pmc.ncbi.nlm.nih.gov]

- 16. Descemet's membrane perforation during deep anterior lamellar keratoplasty: prognosis - PubMed [pubmed.ncbi.nlm.nih.gov]
- 17. Comparison of Clinical Outcomes of Same-size Grafting between Deep Anterior Lamellar Keratoplasty and Penetrating Keratoplasty for Keratoconus - PMC [pmc.ncbi.nlm.nih.gov]
- 18. nkcf.org [nkcf.org]
- 19. crstodayeurope.com [crstodayeurope.com]
- To cite this document: BenchChem. [Technical Support Center: Navigating the Conversion from DALK to Penetrating Keratoplasty]. BenchChem, [2025]. [Online PDF]. Available at: [https://www.benchchem.com/product/b15575147#conversion-from-dalk-to-penetrating-keratoplasty]

---

### Disclaimer & Data Validity:

The information provided in this document is for Research Use Only (RUO) and is strictly not intended for diagnostic or therapeutic procedures. While BenchChem strives to provide accurate protocols, we make no warranties, express or implied, regarding the fitness of this product for every specific experimental setup.

**Technical Support:** The protocols provided are for reference purposes. Unsure if this reagent suits your experiment? [[Contact our Ph.D. Support Team for a compatibility check](#)]

**Need Industrial/Bulk Grade?** [Request Custom Synthesis Quote](#)

## BenchChem

Our mission is to be the trusted global source of essential and advanced chemicals, empowering scientists and researchers to drive progress in science and industry.

### Contact

Address: 3281 E Guasti Rd  
Ontario, CA 91761, United States  
Phone: (601) 213-4426  
Email: [info@benchchem.com](mailto:info@benchchem.com)