

Technical Support Center: Mitigating Alagebrium-Induced Liver Alterations in Long-Term Studies

Author: BenchChem Technical Support Team. **Date:** December 2025

Compound of Interest

Compound Name: Alagebrium

Cat. No.: B1220623

[Get Quote](#)

This technical support center provides troubleshooting guides and frequently asked questions (FAQs) for researchers, scientists, and drug development professionals utilizing **Alagebrium** (ALT-711) in long-term experimental studies. The information provided is intended to assist in monitoring, interpreting, and mitigating potential liver alterations.

Frequently Asked Questions (FAQs)

Q1: What were the specific liver alterations observed in long-term preclinical studies of Alagebrium?

A 2-year toxicology study in Sprague-Dawley rats indicated the presence of "liver alterations"[1][2]. While the detailed histopathology reports from the original studies are not publicly available, the term "liver alterations" in the context of long-term rodent studies can encompass a range of findings. These may include hepatocellular hypertrophy, fatty change, focal inflammation, and the development of benign or malignant neoplasms[3][4][5][6]. It is crucial to note that Sprague-Dawley rats are known to have a significant incidence of spontaneous age-related neoplastic and nonneoplastic lesions in the liver, which can complicate the interpretation of test article-related findings[1][7][8][9][10].

Q2: Are the observed liver alterations considered adverse effects?

The determination of whether a histological change is adverse, non-adverse, or adaptive is a critical aspect of toxicologic pathology[11][12][13][14]. For instance, hepatocellular hypertrophy without evidence of necrosis, degeneration, or significant increases in liver enzymes may be considered a non-adverse adaptive response to xenobiotic exposure[11][12]. Given that clinical trials with **Alagebrium** were allowed to proceed after further preclinical evaluation, it is possible that the observed alterations were considered within the context of the high background incidence in the rat strain used and were not deemed to pose a significant risk to humans[1]. In human clinical trials, **Alagebrium** has generally demonstrated a favorable safety profile, with some reported gastrointestinal symptoms but no major adverse events related to liver function noted in the reviewed studies[2][8].

Q3: What is the proposed mechanism for **Alagebrium**'s effects on the liver?

Alagebrium is a breaker of advanced glycation end-product (AGE) cross-links[2][7]. AGEs can accumulate in the liver and contribute to pathology by interacting with their receptor (RAGE), which can trigger oxidative stress and inflammatory signaling pathways[15]. By breaking these cross-links, **Alagebrium** may help to reduce the downstream effects of AGE accumulation. The AGE-RAGE signaling axis is implicated in various liver pathologies, including fibrosis and steatosis[15]. Additionally, **Alagebrium** has been shown to have a protective effect against oxidative stress, which is a key factor in many forms of liver injury[11][16].

Troubleshooting Guide

Issue: Elevated Liver Enzymes (ALT, AST, ALP) in Experimental Animals

Possible Cause & Solution:

- Direct Hepatotoxicity: While **Alagebrium** has a good safety profile in humans, high doses or specific experimental conditions could potentially lead to hepatocellular injury.
 - Troubleshooting Step: Review the dosing regimen. If possible, include a dose-ranging study to identify a non-toxic dose. Collect blood samples at multiple time points to assess the onset and duration of enzyme elevation.
- Adaptive Response: Mild elevations in liver enzymes, particularly in the absence of histopathological evidence of necrosis or degeneration, may represent an adaptive response of the liver to the metabolic load of the test compound[11][12].

- Troubleshooting Step: Correlate enzyme levels with histopathology. If hypertrophy is the only finding, and enzyme elevations are minimal, the finding may be non-adverse.
- Spontaneous Lesions: As mentioned, the rat strain used may have a high background rate of liver lesions that can lead to enzyme elevations independent of the treatment.
 - Troubleshooting Step: Ensure a sufficiently large control group to establish a robust baseline for spontaneous pathology and enzyme levels. Consult historical control data for the specific rat strain and age.
- Experimental Procedure Stress: Handling, injection, or gavage procedures can cause stress and transient increases in liver enzymes.
 - Troubleshooting Step: Refine animal handling techniques. Ensure all groups, including controls, are subjected to the same procedures.

Data Presentation

Table 1: Summary of Liver Enzyme Data from a Preclinical Study with **Alagebrium** in Wistar Rats

Parameter	Control Group (HCFD)	Alagebrium-Treated Group (10 mg/kg/day)	Spironolactone-Treated Group (50 mg/kg/day)
ALT (U/L)	102.4 ± 2.11	69.3 ± 1.68	81.5 ± 1.25
γ-GGT (MU/L)	53.7 ± 1.76	39.2 ± 1.125	42.1 ± 1.15

Data adapted from a study on metabolic syndrome in male Wistar rats fed a high-carbohydrate, high-fat diet (HCFD) for 16 weeks. Values are presented as mean ± SE.[\[16\]](#)

Table 2: Common Spontaneous Nonneoplastic Liver Lesions in Sprague-Dawley Rats in 104-Week Studies

Lesion	Incidence in Males (%)	Incidence in Females (%)
Hepatocyte Vacuolation	High	High
Bile Duct Hyperplasia	High	High
Basophilic Foci	High	High

This table provides context on common background liver findings in the rat strain used in the 2-year **Alagebrium** toxicology study. "High" indicates that these are among the most frequently observed spontaneous lesions.[\[1\]](#)

Experimental Protocols

1. Protocol for Long-Term (2-Year) Rodent Toxicity Study: Liver Assessment

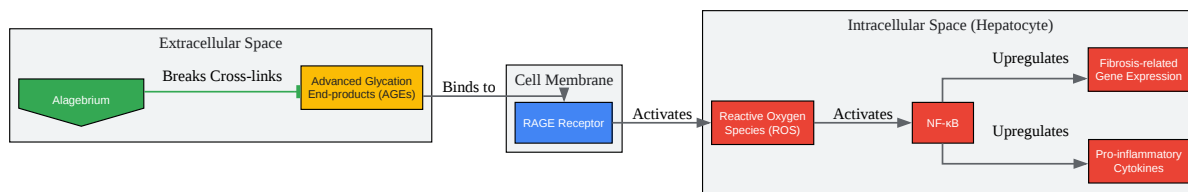
- Animal Model: Sprague-Dawley rats are frequently used for long-term carcinogenicity and chronic toxicity studies[\[1\]](#)[\[7\]](#)[\[8\]](#)[\[9\]](#)[\[10\]](#).
- Dosing: The test article (**Alagebrium**) should be administered daily, typically via oral gavage or in the diet, for a period of 104 weeks[\[17\]](#). At least three dose levels and a concurrent control group receiving the vehicle should be included.
- Clinical Monitoring:
 - Mortality and Morbidity: Observe animals twice daily.
 - Clinical Signs: Conduct detailed examinations weekly.
 - Body Weight and Food Consumption: Record weekly for the first 13 weeks and monthly thereafter.
- Clinical Pathology:
 - Hematology and Clinical Chemistry: Collect blood samples at 3, 6, 12, 18, and 24 months. Key liver-related parameters to measure include Alanine Aminotransferase (ALT), Aspartate Aminotransferase (AST), Alkaline Phosphatase (ALP), Gamma-Glutamyl Transferase (GGT), Total Bilirubin, and Albumin[\[17\]](#).

- Pathology:
 - Gross Necropsy: Conduct a full necropsy on all animals. Weigh the liver.
 - Histopathology: Collect liver samples from all lobes and fix in 10% neutral buffered formalin. Process tissues for paraffin embedding, sectioning, and staining with hematoxylin and eosin (H&E). A board-certified veterinary pathologist should examine the slides[6][18].

2. Protocol for Histopathological Evaluation of Liver Tissue

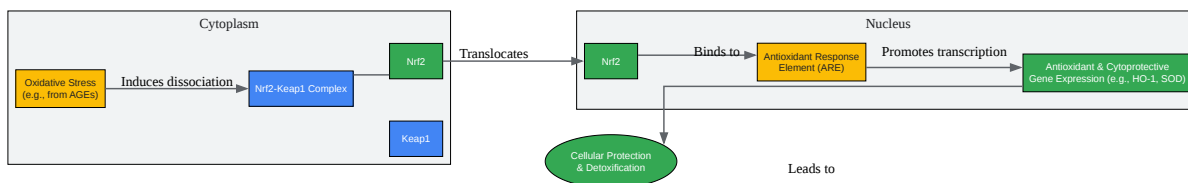
- Tissue Trimming: After fixation, trim the liver lobes to obtain representative sections, including any gross lesions. Standardized trimming procedures should be followed[6].
- Processing: Dehydrate the fixed tissues through a series of graded alcohols, clear in xylene, and infiltrate with paraffin wax[19].
- Embedding and Sectioning: Embed the paraffin-infiltrated tissues in blocks. Cut sections at a thickness of 4-5 micrometers using a microtome.
- Staining: Stain the sections with Hematoxylin and Eosin (H&E) for general morphological assessment[19][20][21].
- Microscopic Examination: A veterinary pathologist should evaluate the slides for a range of potential findings, including:
 - Hepatocellular alterations (hypertrophy, vacuolation, degeneration, necrosis, apoptosis).
 - Inflammatory cell infiltrates.
 - Biliary changes (bile duct hyperplasia).
 - Proliferative lesions (foci of cellular alteration, adenomas, carcinomas).
 - Vascular changes.
- Grading: Semiquantitative grading of lesions (e.g., minimal, mild, moderate, severe) should be consistently applied across all animals and groups to allow for statistical analysis[3].

Mandatory Visualizations



[Click to download full resolution via product page](#)

Caption: AGE-RAGE signaling pathway and the inhibitory action of **Alagebrium**.



[Click to download full resolution via product page](#)

Caption: The Nrf2-mediated antioxidant response pathway in hepatocytes.

Need Custom Synthesis?

BenchChem offers custom synthesis for rare earth carbides and specific isotopic labeling.

Email: info@benchchem.com or [Request Quote Online](#).

References

- 1. Historical Control Background Incidence of Spontaneous Nonneoplastic Lesions of Sprague Dawley Rats in 104-Week Carcinogenicity Studies - PubMed [pubmed.ncbi.nlm.nih.gov]
- 2. Alagebrium and Complications of Diabetes Mellitus - PMC [pmc.ncbi.nlm.nih.gov]
- 3. focusontoxpath.com [focusontoxpath.com]
- 4. focusontoxpath.com [focusontoxpath.com]
- 5. Liver - Inflammation - Nonneoplastic Lesion Atlas [ntp.niehs.nih.gov]
- 6. focusontoxpath.com [focusontoxpath.com]
- 7. Spontaneous neoplastic lesions in aged Sprague-Dawley rats - PubMed [pubmed.ncbi.nlm.nih.gov]
- 8. Historical Control Background Incidence of Spontaneous Neoplastic Lesions of Sprague-Dawley Rats in 104-Week Toxicity Studies - PubMed [pubmed.ncbi.nlm.nih.gov]
- 9. researchgate.net [researchgate.net]
- 10. Natural Occurrence of Neoplastic Lesions in Young Sprague-Dawley Rats - PMC [pmc.ncbi.nlm.nih.gov]
- 11. Is it adverse, non-adverse, adaptive or artifact? - PMC [pmc.ncbi.nlm.nih.gov]
- 12. researchgate.net [researchgate.net]
- 13. focusontoxpath.com [focusontoxpath.com]
- 14. focusontoxpath.com [focusontoxpath.com]
- 15. iasj.rdd.edu.iq [iasj.rdd.edu.iq]
- 16. digitalcommons.aaru.edu.jo [digitalcommons.aaru.edu.jo]
- 17. fda.gov [fda.gov]
- 18. Comparative hepatic toxicity: prechronic/chronic liver toxicity in rodents - PubMed [pubmed.ncbi.nlm.nih.gov]
- 19. Histological alterations in the liver of rats induced by different gold nanoparticle sizes, doses and exposure duration - PMC [pmc.ncbi.nlm.nih.gov]
- 20. researchgate.net [researchgate.net]
- 21. Histological Changes in Kidney and Liver of Rats Due to Gold (III) Compound [Au(en)Cl₂]Cl | PLOS One [journals.plos.org]

- To cite this document: BenchChem. [Technical Support Center: Mitigating Alagebrium-Induced Liver Alterations in Long-Term Studies]. BenchChem, [2025]. [Online PDF]. Available at: [<https://www.benchchem.com/product/b1220623#mitigating-alagebrium-induced-liver-alterations-in-long-term-studies>]

Disclaimer & Data Validity:

The information provided in this document is for Research Use Only (RUO) and is strictly not intended for diagnostic or therapeutic procedures. While BenchChem strives to provide accurate protocols, we make no warranties, express or implied, regarding the fitness of this product for every specific experimental setup.

Technical Support: The protocols provided are for reference purposes. Unsure if this reagent suits your experiment? [[Contact our Ph.D. Support Team for a compatibility check](#)]

Need Industrial/Bulk Grade? [Request Custom Synthesis Quote](#)

BenchChem

Our mission is to be the trusted global source of essential and advanced chemicals, empowering scientists and researchers to drive progress in science and industry.

Contact

Address: 3281 E Guasti Rd
Ontario, CA 91761, United States
Phone: (601) 213-4426
Email: info@benchchem.com