

# Technical Support Center: Minimizing Nerve Injury During Lateral Malleolus Surgery

**Author:** BenchChem Technical Support Team. **Date:** December 2025

## Compound of Interest

Compound Name: SQ 27786

Cat. No.: B1681082

[Get Quote](#)

This technical support center provides researchers, scientists, and drug development professionals with essential information to minimize the risk of iatrogenic nerve injury during surgical procedures involving the lateral malleolus. The following troubleshooting guides, frequently asked questions (FAQs), and experimental protocols are designed to address specific issues encountered in a laboratory or clinical research setting.

## Troubleshooting Guides

This section addresses common problems encountered during lateral malleolus surgery that may lead to nerve injury.

**Problem:** Uncertainty about the location of the superficial peroneal nerve (SPN) during a direct lateral approach.

Potential Cause	Suggested Solution
Anatomical Variation	The SPN has considerable anatomical variability. A "cut straight to bone" approach is not recommended.[1][2]
Action: Perform a careful, layered dissection to identify the nerve.[1] The SPN is often found anteriorly in the proximal part of the incision.[1][3]	
Inadequate Preoperative Assessment	Failure to assess for palpable nerves or consider patient-specific anatomy.
Action: Attempt to identify the SPN preoperatively by palpation with the ankle in maximal plantar flexion and inversion.[4] Be aware that a higher BMI can make identification more difficult.[4]	
Incorrect Incision Placement	Incision is placed too far anteriorly without consideration of the SPN's course.
Action: For a standard lateral approach, make a longitudinal incision along the posterior margin of the fibula.[3] If a more anterior approach is necessary, be prepared to identify and protect the SPN.[1]	

Problem: Postoperative numbness or pain in the distribution of the sural nerve after a posterolateral approach.

Potential Cause	Suggested Solution
Direct Nerve Injury	The sural nerve is at high risk with the posterolateral approach, with some studies reporting injury rates as high as 48%. <a href="#">[5]</a> <a href="#">[6]</a>
Action: During a posterolateral approach, carefully dissect the subcutaneous tissue to identify and protect the sural nerve, which runs posterior to the fibula. <a href="#">[3]</a>	
Suture Entrapment	The nerve was not directly visualized and was inadvertently caught in a suture during closure.
Action: Ensure clear visualization of tissue layers during closure. If a nerve injury is suspected postoperatively, consider diagnostic tools such as ultrasound to rule out entrapment. <a href="#">[7]</a>	
Traction Injury	Excessive retraction of soft tissues during the procedure.
Action: Use careful retraction techniques and be mindful of the tension placed on surrounding soft tissues.	

## Frequently Asked Questions (FAQs)

Q1: What are the primary nerves at risk during a lateral approach to the distal fibula?

A1: The two primary nerves at risk are the superficial peroneal nerve (SPN) and the sural nerve. The SPN is particularly vulnerable in the anterior and proximal aspects of a direct lateral incision, while the sural nerve is at risk with posterolateral approaches.[\[3\]](#)[\[8\]](#)

Q2: How common is a nerve injury after lateral malleolus surgery?

A2: The incidence of nerve injury varies depending on the surgical approach. Symptomatic SPN injury has been reported in up to 21% of patients undergoing open reduction and internal

fixation (ORIF) with a lateral approach.[9] For the sural nerve, the risk is significantly higher with a posterior approach, with one study reporting a 48% incidence of iatrogenic injury.[5][6]

Q3: What are the known anatomical variations of the superficial peroneal nerve I should be aware of?

A3: The SPN has several important variations. In a significant percentage of individuals, the nerve may be located in the anterior compartment of the leg (around 28.3% in one study).[10][11] The branching pattern also varies, with the nerve sometimes dividing before piercing the deep fascia.[10][11] One particularly high-risk variation is the Blair and Botte type B pattern, where a branch of the SPN crosses the distal fibula from posterior to anterior, placing it directly in the surgical field of a standard lateral approach.[12]

Q4: Are there defined "safe zones" for incision placement?

A4: While a definitive universal "safe zone" is difficult to establish due to anatomical variations, some guidelines exist. For a direct lateral approach, an incision along the posterior margin of the fibula is generally considered safer for the SPN.[3] For the sural nerve, it is typically located posterior to the fibula, and care should be taken with any posterior extension of the incision.[3] One study proposed a safe incision site for the lateral approach starting 12 mm posterior to the anterolateral border of the fibula at 10 cm proximal to the lateral malleolar tip and extending distally.

Q5: What are the consequences of iatrogenic nerve injury in this context?

A5: Iatrogenic nerve injury can lead to significant morbidity, including chronic pain, numbness, tingling, and the formation of painful neuromas.[3][13] These symptoms can negatively impact a patient's quality of life and functional outcome after surgery.[12]

## Data Presentation

Table 1: Incidence of Nerve Injury in Lateral Malleolus Surgery by Approach

Nerve	Surgical Approach	Incidence of Injury	Reference
Superficial Peroneal Nerve	Open Reduction and Internal Fixation (Lateral Approach)	21%	[9]
Sural Nerve	Posterior Approach	48%	[5][6]
Sural Nerve	Posterolateral Approach	25% (5 of 20 patients)	[14]
Sural Nerve	"Smile" Approach	8%	[9]

Table 2: Anatomical Variations of the Superficial Peroneal Nerve (Based on a Cadaveric Study)

Anatomical Variation	Prevalence	Reference
Location in the anterior compartment of the leg	28.3%	[10][11]
Branching before piercing between peroneus longus and extensor digitorum longus	8.3%	[10][11]
Branching after piercing the aforementioned muscles but before piercing the deep fascia	11.7%	[10][11]
Presence of an accessory deep peroneal nerve	33.3%	[10]

Table 3: Anatomical Measurements for Nerve Localization (Distances Relative to Bony Landmarks)

Nerve	Landmark	Measurement	Reference
Superficial Peroneal Nerve	Emergence from deep fascia relative to the tip of the lateral malleolus	10 ± 2.82 cm	
Superficial Peroneal Nerve	Termination into branches relative to the tip of the lateral malleolus	4.7 ± 2.08 cm	
Sural Nerve	Proximity to the Achilles tendon	7 cm above the tip of the lateral malleolus	[13]
Sural Nerve	Position relative to the lateral malleolus	~14 mm posterior and ~14 mm inferior	[13]

## Experimental Protocols

### Protocol 1: Cadaveric Dissection for Identification of the Superficial Peroneal Nerve and its Branches

Objective: To systematically identify the course and branching pattern of the superficial peroneal nerve in the distal leg and ankle.

#### Materials:

- Fresh-frozen or embalmed human cadaveric lower limb
- Standard dissection kit (scalpels, forceps, scissors, probes)
- Magnifying loupes (3.5x-5x)
- Digital caliper
- Ruler
- Digital camera

#### Methodology:

- **Incision:** Make a longitudinal skin incision from the head of the fibula to the dorsum of the foot, just anterior to the fibula.
- **Superficial Dissection:** Carefully reflect the skin and subcutaneous tissue, identifying and preserving any visible cutaneous nerves.
- **Fascial Incision:** Incise the deep fascia (crural fascia) along the line of the skin incision.
- **Nerve Identification:** The superficial peroneal nerve is typically found in the lateral compartment, between the peroneus longus and extensor digitorum longus muscles.<sup>[10]</sup> Carefully dissect this plane to isolate the nerve trunk.
- **Tracing the Nerve:** Trace the SPN distally. Note the point where it pierces the deep fascia to become superficial. Measure the distance of this point from the tip of the lateral malleolus using a digital caliper.
- **Branch Identification:** Follow the nerve distally and identify its terminal branches, typically the medial and intermediate dorsal cutaneous nerves. Document the branching pattern and the level at which branching occurs relative to the ankle joint.
- **Documentation:** Photograph all anatomical variations encountered. Record all measurements in a lab notebook.

#### Protocol 2: Ultrasound-Guided Localization of the Superficial Peroneal and Sural Nerves

**Objective:** To non-invasively identify the location of the superficial peroneal and sural nerves prior to a surgical incision.

#### Materials:

- High-frequency linear array ultrasound transducer (10-18 MHz)
- Ultrasound machine
- Sterile ultrasound gel

- Skin marking pen

#### Methodology for Superficial Peroneal Nerve:

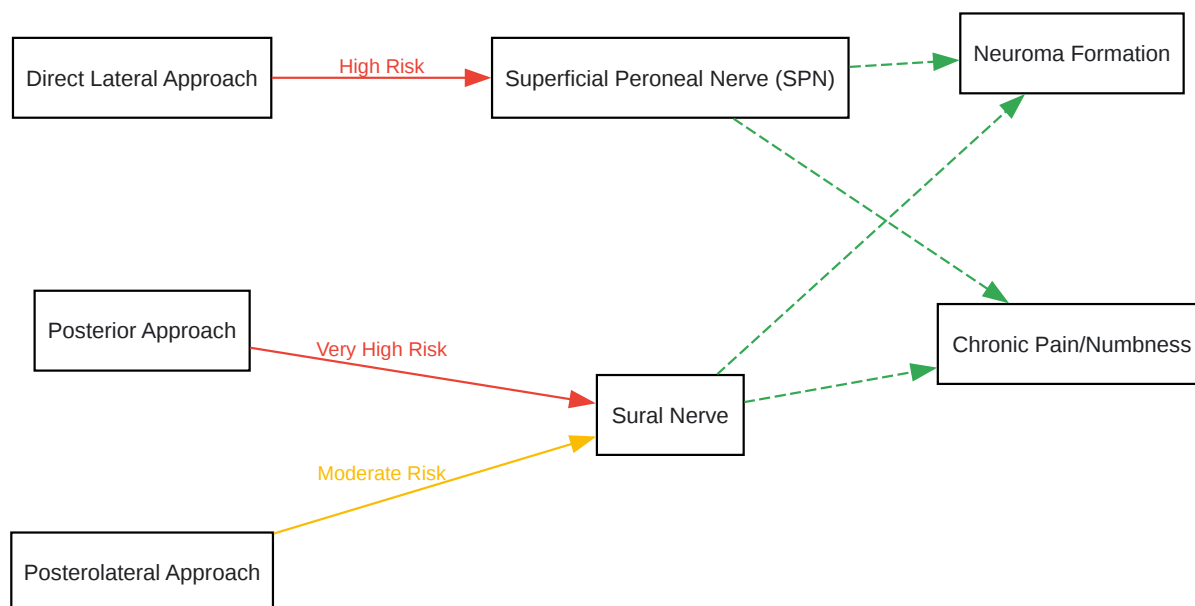
- Patient Positioning: Position the patient supine with the leg in a neutral position.
- Transducer Placement: Place the transducer in a transverse orientation on the anterolateral aspect of the distal third of the leg.
- Anatomical Landmarks: Identify the tibia and fibula, and the anterior and lateral muscular compartments. The SPN is typically located in the fascial plane between the peroneus longus and extensor digitorum longus muscles.
- Nerve Visualization: The SPN will appear as a small, hyperechoic, honeycomb-like structure.
- Tracing the Nerve: Scan proximally and distally to trace the course of the nerve. Note the point where it pierces the deep fascia.
- Skin Marking: Mark the course of the nerve on the skin with a marking pen.

#### Methodology for Sural Nerve:

- Patient Positioning: Position the patient prone or in a lateral decubitus position.
- Transducer Placement: Place the transducer in a transverse orientation posterior to the lateral malleolus.
- Anatomical Landmarks: Identify the Achilles tendon and the fibula. The sural nerve is typically found in the subcutaneous tissue between these two structures, often in proximity to the small saphenous vein.
- Nerve Visualization: The sural nerve will appear as a small, hyperechoic structure. Color Doppler can be used to identify the accompanying vein.
- Tracing the Nerve: Trace the nerve proximally and distally to map its course.
- Skin Marking: Mark the course of the nerve on the skin.

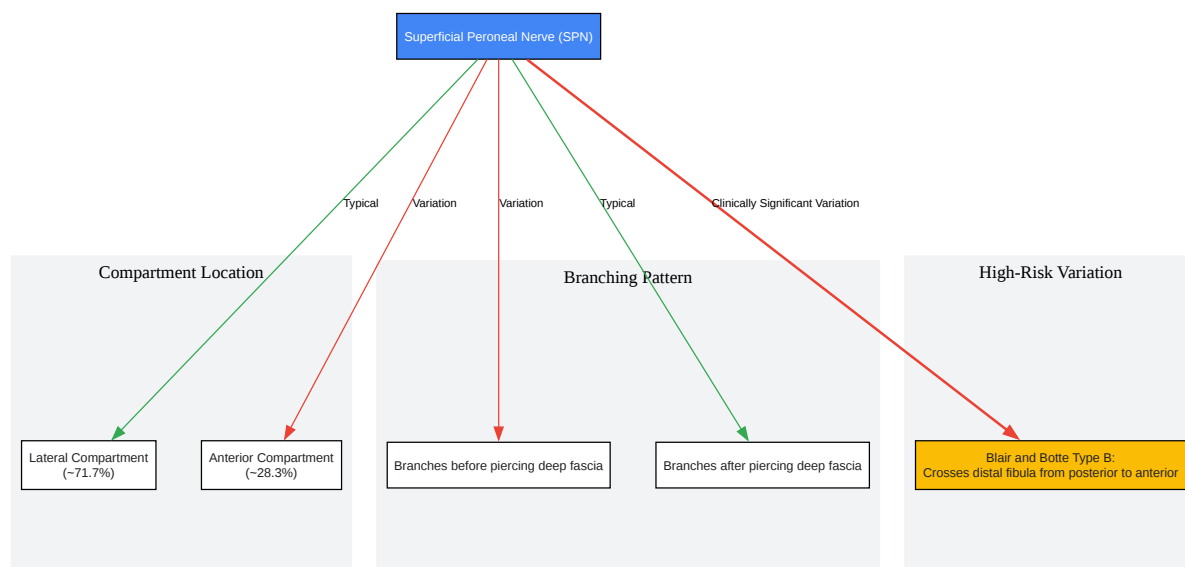


## Mandatory Visualization



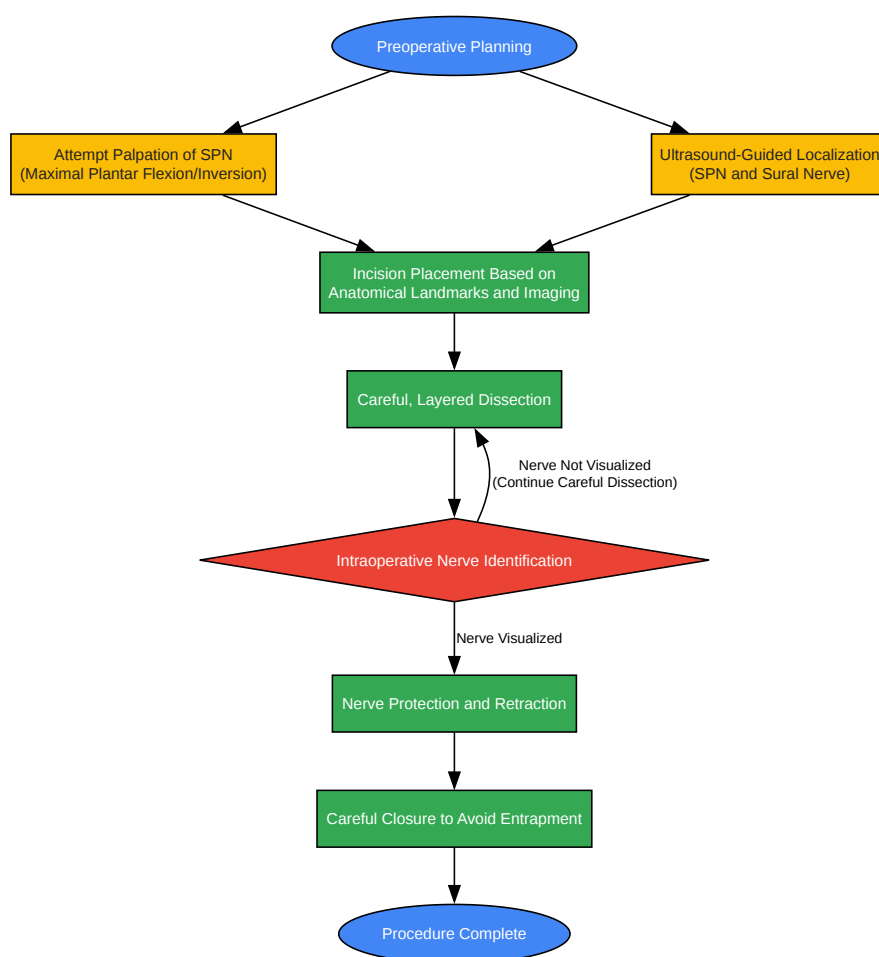
[Click to download full resolution via product page](#)

Caption: Risk of nerve injury associated with different surgical approaches to the lateral malleolus.



[Click to download full resolution via product page](#)

Caption: Common anatomical variations of the superficial peroneal nerve relevant to lateral malleolus surgery.



[Click to download full resolution via product page](#)

### Need Custom Synthesis?

BenchChem offers custom synthesis for rare earth carbides and specific isotopic labeling.

Email: [info@benchchem.com](mailto:info@benchchem.com) or [Request Quote Online](#).

## References

- 1. Lateral approach to the malleoli [surgeryreference.aofoundation.org]
- 2. researchgate.net [researchgate.net]
- 3. Approach to the Lateral Malleolus - Approaches - Orthobullets [orthobullets.com]
- 4. Identification of the superficial peroneal nerve: Anatomical study with surgical implications - PMC [pmc.ncbi.nlm.nih.gov]

- 5. researchgate.net [researchgate.net]
- 6. Frequent Sural Nerve Injury with Posterior Approach for Ankle Fracture Fixation - PubMed [pubmed.ncbi.nlm.nih.gov]
- 7. Nerve damage after ankle surgery: Causes and more [medicalnewstoday.com]
- 8. Ankle Fractures - Trauma - Orthobullets [orthobullets.com]
- 9. upload.orthobullets.com [upload.orthobullets.com]
- 10. files.core.ac.uk [files.core.ac.uk]
- 11. researchgate.net [researchgate.net]
- 12. Risk of injury to the sural nerve during posterolateral approach to the distal tibia: An ultrasound simulation study - PubMed [pubmed.ncbi.nlm.nih.gov]
- 13. podiatrym.com [podiatrym.com]
- 14. Direct fixation of posterior malleolus fractures-posterolateral or posteromedial approach? - PubMed [pubmed.ncbi.nlm.nih.gov]
- To cite this document: BenchChem. [Technical Support Center: Minimizing Nerve Injury During Lateral Malleolus Surgery]. BenchChem, [2025]. [Online PDF]. Available at: [https://www.benchchem.com/product/b1681082#minimizing-nerve-injury-during-lateral-malleolus-surgery]

---

### Disclaimer & Data Validity:

The information provided in this document is for Research Use Only (RUO) and is strictly not intended for diagnostic or therapeutic procedures. While BenchChem strives to provide accurate protocols, we make no warranties, express or implied, regarding the fitness of this product for every specific experimental setup.

**Technical Support:** The protocols provided are for reference purposes. Unsure if this reagent suits your experiment? [[Contact our Ph.D. Support Team for a compatibility check](#)]

**Need Industrial/Bulk Grade?** [Request Custom Synthesis Quote](#)

# BenchChem

Our mission is to be the trusted global source of essential and advanced chemicals, empowering scientists and researchers to drive progress in science and industry.

## Contact

Address: 3281 E Guasti Rd

Ontario, CA 91761, United States

Phone: (601) 213-4426

Email: [info@benchchem.com](mailto:info@benchchem.com)