

Technical Support Center: Managing "Steroid Flare" Reaction in Animal Models

Author: BenchChem Technical Support Team. **Date:** December 2025

Compound of Interest

Compound Name: Aristospan

Cat. No.: B1221926

[Get Quote](#)

This technical support center provides troubleshooting guides and frequently asked questions (FAQs) for researchers, scientists, and drug development professionals encountering "steroid flare" type reactions in animal models following local corticosteroid administration.

Troubleshooting Guides

Issue 1: Unexpected Acute Inflammation Post-Injection

Symptoms:

- Visible erythema (redness) and edema (swelling) at the injection site within 24-48 hours.
- Increased sensitivity to touch or pressure at the injection site.
- In some models, quantifiable changes in limb volume or temperature.

Possible Causes:

- **Crystallization of Corticosteroid:** The corticosteroid formulation may be precipitating at the injection site, leading to a foreign body-type inflammatory response. This is considered a primary cause of clinical steroid flare.^{[1][2]} The physical form of the steroid crystals can influence the degree of the inflammatory response.^{[3][4]}
- **Vehicle-Induced Irritation:** The vehicle used to suspend the corticosteroid may be causing a local inflammatory reaction.

- **Mechanical Trauma from Injection:** The injection procedure itself can cause tissue damage and a subsequent inflammatory response.
- **Contamination:** Bacterial or endotoxin contamination of the injectate or improper aseptic technique can lead to an inflammatory response.

Troubleshooting Steps:

- **Vehicle Control Group:** Always include a control group that receives an injection of the vehicle alone to differentiate between a reaction to the corticosteroid and a reaction to the vehicle.
- **Formulation Analysis:**
 - Ensure the corticosteroid is properly suspended before each injection.
 - Consider the solubility and crystal size of the chosen corticosteroid. Different preparations can elicit varied inflammatory responses.[\[1\]](#)[\[2\]](#)
- **Refine Injection Technique:**
 - Use appropriate needle gauge and injection volume for the animal model and injection site to minimize mechanical trauma.
 - Ensure a consistent and slow rate of injection.
- **Aseptic Technique:** Maintain strict aseptic technique during preparation and administration of the injection to prevent contamination.
- **Quantitative Assessment:**
 - Measure erythema and edema using a scoring system or calipers.
 - Consider advanced imaging techniques (e.g., MRI) to assess soft tissue edema.[\[5\]](#)
 - Perform histological analysis of the injection site to characterize the inflammatory infiltrate.[\[6\]](#)[\[7\]](#)

Issue 2: Prolonged or Severe Local Reaction

Symptoms:

- Inflammation persisting beyond 72 hours.
- Development of sterile abscesses, tissue necrosis, or significant tissue atrophy at the injection site.[1][2]

Possible Causes:

- High Concentration of Corticosteroid: An excessively high dose or concentration of the corticosteroid can lead to local tissue damage.
- Poorly Soluble Corticosteroid Preparation: Depot formulations with low solubility are designed for slow release but may also contribute to a prolonged local reaction.[1][2]
- Underlying Immune Response: The animal model may have a heightened sensitivity to the corticosteroid or its vehicle.

Troubleshooting Steps:

- Dose-Response Study: Conduct a pilot study with varying doses of the corticosteroid to determine the optimal concentration that achieves the desired therapeutic effect with minimal local reaction.
- Evaluate Different Formulations: Test corticosteroids with different solubility profiles. For example, a more soluble preparation like betamethasone sodium phosphate may have a different local reaction profile compared to a less soluble one like triamcinolone hexacetonide.[1][2]
- Histopathological Examination: At the study endpoint, collect tissue from the injection site for histopathological analysis to assess the extent of inflammation, necrosis, and atrophy.[6]
- Systemic vs. Local Administration: If the experimental design allows, compare the effects of local administration with systemic administration of the same corticosteroid to understand the contribution of local tissue effects.[5]

Frequently Asked Questions (FAQs)

Q1: What is a "steroid flare" reaction in the context of animal models?

A1: In clinical practice, a "steroid flare" is a transient increase in pain and inflammation at the injection site that can occur within the first 24-48 hours after a corticosteroid injection. While not a formally defined syndrome in animal models, analogous reactions can be observed as an acute local inflammatory response characterized by erythema, edema, and cellular infiltration, likely due to the crystallization of the steroid.[\[1\]](#)[\[2\]](#)

Q2: How can I differentiate a steroid flare from an infection at the injection site?

A2: A steroid flare-like reaction is typically self-limiting and should begin to resolve within 48-72 hours. An infection, on the other hand, will likely worsen over time and may be accompanied by systemic signs such as fever, lethargy, and weight loss. Aseptic preparation and administration of the injection are crucial to prevent infection. If an infection is suspected, microbiological analysis of the injection site may be necessary.

Q3: What are the expected histological findings of a local reaction to a corticosteroid injection?

A3: Histological examination of a corticosteroid injection site may reveal acellular, granular deposits of the corticosteroid.[\[8\]](#) A mild to moderate inflammatory reaction with histiocytes, fibroblasts, and lymphocytes may be present at the periphery of these deposits.[\[8\]](#) In more severe reactions, signs of necrosis and atrophy of the surrounding tissue may be observed.[\[1\]](#)
[\[2\]](#)

Q4: Can the type of corticosteroid influence the likelihood of a local reaction?

A4: Yes, different corticosteroid preparations have varying solubilities and crystal structures, which can affect the local tissue response.[\[1\]](#)[\[2\]](#)[\[3\]](#)[\[4\]](#) For example, studies in rats have shown that betamethasone preparations with a soluble component may have a quicker but milder effect compared to less soluble preparations like prednisolone tebutate and triamcinolone hexacetonide, which can cause more significant tissue atrophy and necrosis at higher doses.[\[1\]](#)
[\[2\]](#)

Q5: What is the underlying signaling pathway for corticosteroid action and how might it relate to a flare reaction?

A5: Corticosteroids exert their primary anti-inflammatory effects by binding to the glucocorticoid receptor (GR). This complex then translocates to the nucleus to suppress the expression of pro-inflammatory genes, largely by inhibiting transcription factors like NF- κ B. This leads to a reduction in pro-inflammatory cytokines such as TNF- α , IL-1 β , and IL-6. A flare reaction is thought to be a paradoxical, localized inflammatory response to the physical presence of steroid crystals, which can activate innate immune cells before the pharmacological anti-inflammatory effects take hold.

Quantitative Data Summary

Table 1: Hypothetical Incidence and Severity of Local Inflammatory Reactions to Different Corticosteroid Preparations in a Rodent Model

Corticosteroid Preparation	Dose (mg/kg)	Incidence of Visible Edema (%)	Peak Edema Volume (mm ³) (Mean \pm SD)	Duration of Edema (hours) (Mean \pm SD)
Vehicle Control	N/A	10%	5 \pm 2	12 \pm 4
Betamethasone Acetate/Phosphate	1	25%	15 \pm 5	24 \pm 8
Methylprednisolone Acetate	1	40%	25 \pm 8	48 \pm 12
Triamcinolone Acetonide	1	50%	35 \pm 10	72 \pm 16

Table 2: Hypothetical Cytokine Levels at the Injection Site 24 Hours Post-Injection in a Mouse Model

Treatment Group	TNF- α (pg/mL) (Mean \pm SD)	IL-1 β (pg/mL) (Mean \pm SD)	IL-6 (pg/mL) (Mean \pm SD)
Naive (No Injection)	10 \pm 3	5 \pm 2	8 \pm 3
Vehicle Control	50 \pm 15	30 \pm 10	40 \pm 12
Triamcinolone Acetonide	150 \pm 40	100 \pm 30	120 \pm 35

Experimental Protocols

Protocol 1: Induction and Assessment of a "Steroid Flare" Like Reaction in a Rat Air Pouch Model

This protocol is adapted from studies investigating local inflammation in response to crystal-induced inflammation and corticosteroid injections.[\[1\]](#)[\[2\]](#)

Objective: To induce and quantify a local inflammatory reaction analogous to a "steroid flare" following the injection of a corticosteroid suspension.

Materials:

- Male Sprague-Dawley rats (200-250g)
- Corticosteroid suspension (e.g., Triamcinolone Acetonide, 20 mg/mL)
- Sterile saline
- Sterile air
- Anesthesia (e.g., isoflurane)
- Calipers
- Materials for euthanasia and tissue collection

Procedure:

- Air Pouch Formation:
 - Anesthetize the rats.
 - Inject 20 mL of sterile air subcutaneously into the dorsal region to create an air pouch.
 - On day 3, re-inflate the pouch with 10 mL of sterile air to maintain the space.
- Corticosteroid Injection (Day 6):
 - Divide the animals into a treatment group and a vehicle control group.
 - Inject 1 mL of the corticosteroid suspension or sterile saline into the air pouch.
- Assessment of Inflammation:
 - At 6, 24, 48, and 72 hours post-injection, anesthetize the rats.
 - Visually score the injection site for erythema and edema.
 - Measure the dimensions of any visible swelling with calipers.
 - Aspirate the fluid from the air pouch to measure the volume of exudate and for leukocyte counting and cytokine analysis.
- Tissue Collection:
 - At the final time point, euthanize the animals and carefully dissect the air pouch membrane for histological analysis.

Protocol 2: Histopathological Evaluation of Injection Site Reactions

Objective: To characterize the cellular response and tissue morphology at the site of a corticosteroid injection.

Materials:

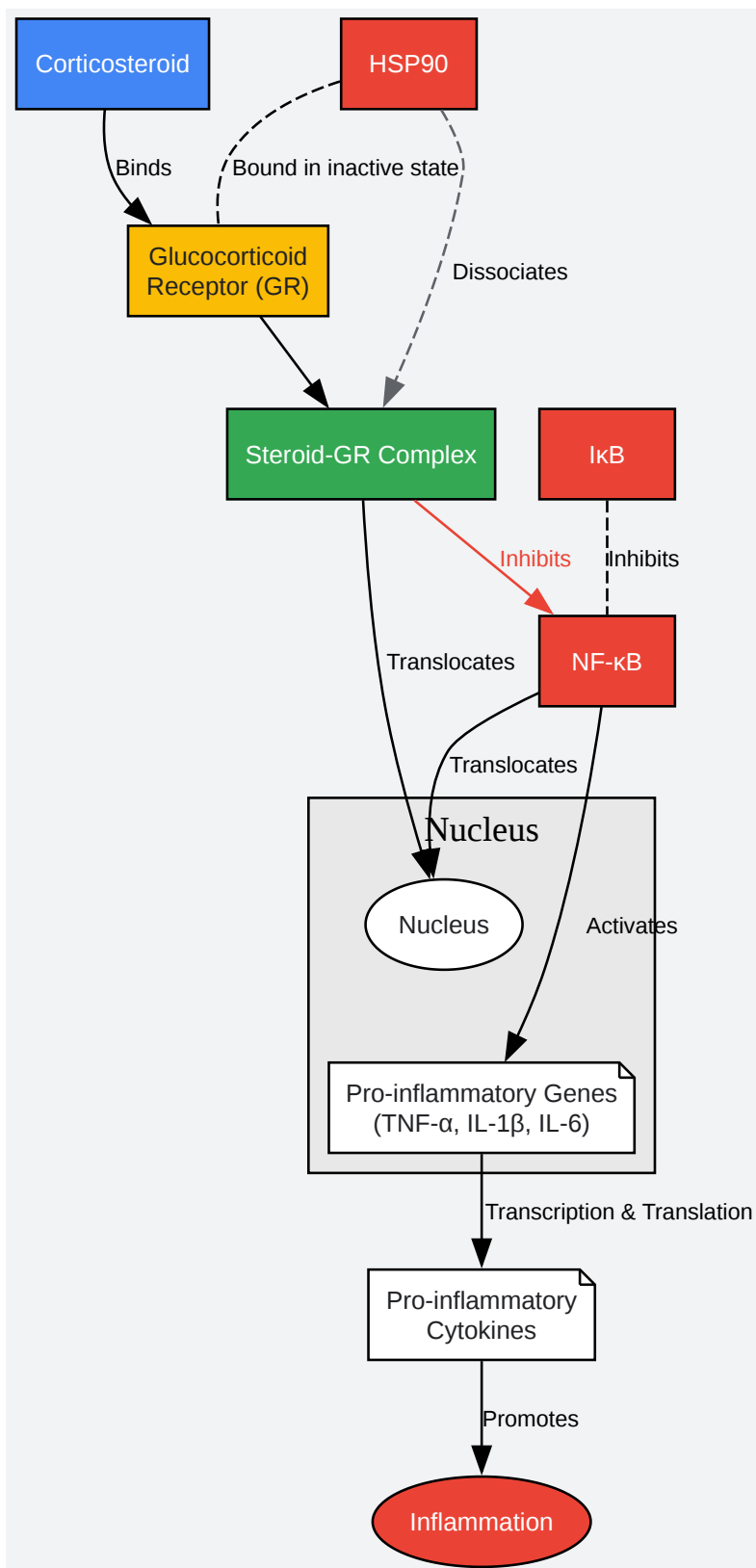
- Animal model with corticosteroid injection (from Protocol 1 or other relevant model)
- Euthanasia solution
- 10% neutral buffered formalin
- Paraffin
- Microtome
- Hematoxylin and eosin (H&E) stains
- Microscope

Procedure:

- Tissue Collection and Fixation:
 - Following euthanasia, excise the skin and underlying muscle tissue at the injection site.
 - Fix the tissue in 10% neutral buffered formalin for at least 24 hours.
- Tissue Processing and Sectioning:
 - Process the fixed tissue through graded alcohols and xylene, and embed in paraffin.
 - Section the paraffin blocks at 5 μ m thickness using a microtome.
- Staining:
 - Mount the sections on glass slides and stain with H&E.
- Microscopic Examination:
 - Examine the stained sections under a light microscope.
 - Evaluate for the presence of corticosteroid deposits, inflammatory cell infiltrates (neutrophils, macrophages, lymphocytes), edema, necrosis, and fibrosis.

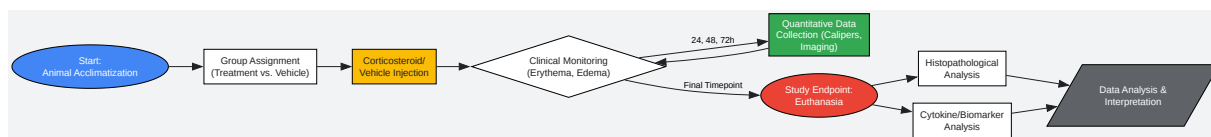
- Use a semi-quantitative scoring system to grade the severity of these findings.

Visualizations



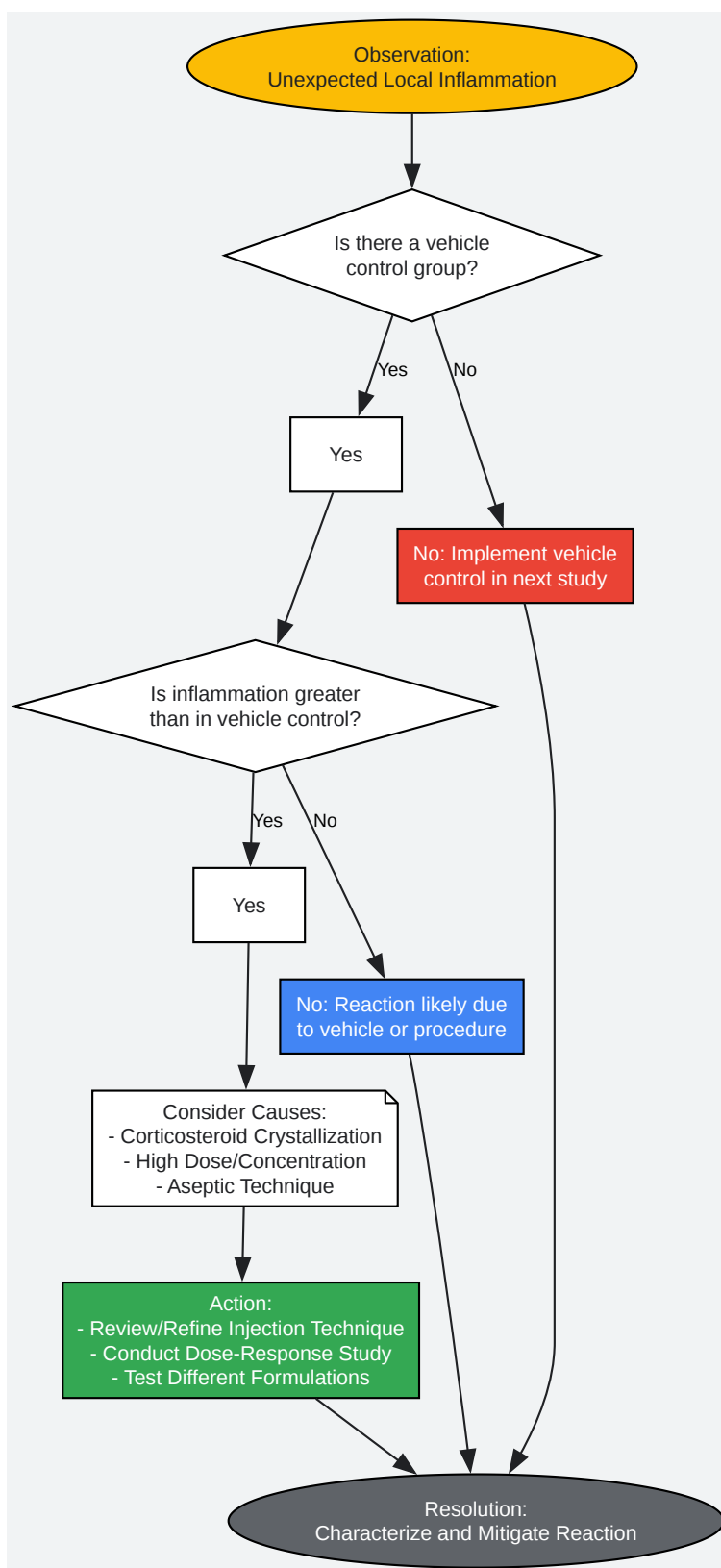
[Click to download full resolution via product page](#)

Caption: Corticosteroid anti-inflammatory signaling pathway.



[Click to download full resolution via product page](#)

Caption: Experimental workflow for assessing local reactions.



[Click to download full resolution via product page](#)

Caption: Troubleshooting logic for unexpected local inflammation.

Need Custom Synthesis?

BenchChem offers custom synthesis for rare earth carbides and specific isotopic labeling.

Email: info@benchchem.com or [Request Quote Online](#).

References

- 1. academic.oup.com [academic.oup.com]
- 2. Intra-articular corticosteroid preparations: different characteristics and their effect during inflammation induced by monosodium urate crystals in the rat subcutaneous air pouch - PubMed [pubmed.ncbi.nlm.nih.gov]
- 3. Effect of Crystal Form on in Vivo Topical Anti-Inflammatory Activity of Corticosteroids - Archives of Pharmacal Research | Korea Science [koreascience.kr]
- 4. Effect of crystal form on in vivo topical anti-inflammatory activity of corticosteroids - PubMed [pubmed.ncbi.nlm.nih.gov]
- 5. The effect of corticosteroid administration on soft-tissue inflammation associated with rhBMP-2 use in a rodent model of inflammation - PubMed [pubmed.ncbi.nlm.nih.gov]
- 6. The Effects of Corticosteroid Injection in the Healthy and Damaged Achilles Tendon Model: Histopathological and Biomechanical Experimental Study in Rats - PubMed [pubmed.ncbi.nlm.nih.gov]
- 7. [Efficacy of local steroid injection on rat skin lesions induced by extravasation of vesicant anticancer drugs] - PubMed [pubmed.ncbi.nlm.nih.gov]
- 8. The histologic appearance of corticosteroid injection sites - PubMed [pubmed.ncbi.nlm.nih.gov]
- To cite this document: BenchChem. [Technical Support Center: Managing "Steroid Flare" Reaction in Animal Models]. BenchChem, [2025]. [Online PDF]. Available at: [https://www.benchchem.com/product/b1221926#managing-steroid-flare-reaction-in-animal-models]

Disclaimer & Data Validity:

The information provided in this document is for Research Use Only (RUO) and is strictly not intended for diagnostic or therapeutic procedures. While BenchChem strives to provide

accurate protocols, we make no warranties, express or implied, regarding the fitness of this product for every specific experimental setup.

Technical Support: The protocols provided are for reference purposes. Unsure if this reagent suits your experiment? [[Contact our Ph.D. Support Team for a compatibility check](#)]

Need Industrial/Bulk Grade? [Request Custom Synthesis Quote](#)

BenchChem

Our mission is to be the trusted global source of essential and advanced chemicals, empowering scientists and researchers to drive progress in science and industry.

Contact

Address: 3281 E Guasti Rd
Ontario, CA 91761, United States
Phone: (601) 213-4426
Email: info@benchchem.com