

Technical Support Center: Managing Sestamibi Washout for Accurate Diagnosis

Author: BenchChem Technical Support Team. **Date:** December 2025

Compound of Interest

Compound Name: *TECHNETIUM SESTAMIBI*

Cat. No.: *B1142544*

[Get Quote](#)

Welcome to our technical support center for researchers, scientists, and drug development professionals. This resource provides troubleshooting guides and frequently asked questions (FAQs) to address common issues encountered during experiments involving Technetium-99m Sestamibi (99mTc-Sestamibi) and its washout rates.

Frequently Asked Questions (FAQs)

Q1: What is Sestamibi washout and why is it important for diagnostic accuracy?

A1: Sestamibi washout refers to the rate at which 99mTc-Sestamibi is cleared from a tissue of interest after its initial uptake. This rate is crucial for diagnostic accuracy as it often differs between healthy and diseased tissues. For instance, in myocardial perfusion imaging, ischemic but viable heart muscle may show a faster washout than healthy tissue.^{[1][2]} In parathyroid imaging, adenomas typically retain Sestamibi longer than the surrounding thyroid tissue, and a differential washout is a key diagnostic indicator.^{[3][4][5][6][7]}

Q2: What are the primary factors that influence Sestamibi washout rates?

A2: Several factors at the cellular and physiological level influence Sestamibi washout. The two primary determinants are mitochondrial membrane potential and the expression of the P-glycoprotein (P-gp) efflux pump.^{[8][9][10][11][12]} Sestamibi is a lipophilic cation that accumulates in mitochondria due to the negative mitochondrial membrane potential.^[13] P-glycoprotein, a product of the multidrug resistance (MDR1) gene, actively transports Sestamibi out of the cell.^{[8][11][14]} Therefore, higher mitochondrial density and lower P-gp expression

lead to slower washout, while impaired mitochondrial function or high P-gp expression results in faster washout.

Q3: My parathyroid scan was negative, but clinical suspicion for an adenoma remains high. What could be the cause?

A3: A false-negative parathyroid scan can occur due to "rapid washout," where the parathyroid adenoma clears the Sestamibi as quickly as the surrounding thyroid tissue.[14][15][16] This can be caused by high levels of P-glycoprotein expression in the adenoma.[8][11] Other factors include small adenoma size, the presence of multiglandular disease, or co-existing thyroid nodules that can obscure the signal.[6][14] In such cases, a dual-tracer subtraction technique or alternative imaging modalities may be beneficial.[17]

Q4: How does myocardial ischemia affect Sestamibi washout rates?

A4: In the context of myocardial perfusion imaging, ischemic but viable myocardium can exhibit an accelerated washout of Sestamibi.[1] This is thought to be due to mitochondrial dysfunction caused by reduced blood flow and oxygen supply, which impairs the ability of the myocardial cells to retain the tracer.[18] Therefore, an increased washout rate in a specific myocardial segment can be an indicator of underlying coronary artery disease.[19]

Troubleshooting Guides

Issue: Unexpectedly Rapid Sestamibi Washout in Parathyroid Imaging

Symptoms:

- Early-phase images show a focus of uptake suggestive of a parathyroid adenoma.
- Delayed-phase images show significant or complete loss of this focal uptake, making it indistinguishable from the thyroid.
- The scan is interpreted as negative or equivocal despite clinical indications of hyperparathyroidism.

Possible Causes:

- High P-glycoprotein (P-gp) Expression: The adenoma may have high levels of the P-gp efflux pump, actively removing Sestamibi from the cells.[8][11]
- Atypical Adenoma Histology: Certain cellular compositions of parathyroid adenomas may have inherently faster washout kinetics.
- Multiglandular Disease: The presence of multiple smaller, hyperplastic glands can lead to less intense and more rapid washout compared to a single large adenoma.[6]

Troubleshooting Steps:

- Review Early-Phase Images: Carefully re-examine the initial images (15-30 minutes post-injection) for any focal uptake that is greater than the surrounding thyroid tissue, even if it disappears on delayed images.[6]
- Consider a Dual-Tracer Subtraction Protocol: If a dual-phase study is inconclusive, a dual-tracer technique using 123I-iodide or 99mTc-pertechnetate to delineate the thyroid can help unmask a parathyroid adenoma with rapid washout.[17]
- Correlate with Other Imaging Modalities: Ultrasound or 4D-CT of the neck can provide anatomical information to correlate with the scintigraphic findings.
- Evaluate for P-gp Modulators: In a research setting, pre-administration of P-gp inhibitors could be explored to enhance Sestamibi retention, though this is not standard clinical practice.[8]

Issue: High Variability in Myocardial Washout Rates Between Experiments

Symptoms:

- Inconsistent and non-reproducible myocardial Sestamibi washout rates in studies with similar experimental conditions.
- Difficulty in establishing a reliable baseline washout rate.

Possible Causes:

- Inconsistent Patient Preparation: Variations in fasting state, caffeine intake, or medication (e.g., beta-blockers) can affect myocardial metabolism and blood flow, influencing Sestamibi kinetics.[\[13\]](#)[\[20\]](#)
- Variable Stress Protocol Application: Inconsistent levels of physical or pharmacological stress will lead to different degrees of myocardial blood flow and Sestamibi uptake and washout.[\[21\]](#)[\[22\]](#)
- Incorrect Image Acquisition Timing: Deviations from the established imaging times post-injection for both rest and stress studies will alter the calculated washout rate.
- Region of Interest (ROI) Placement: Inconsistent placement of ROIs for data analysis can introduce significant variability.

Troubleshooting Steps:

- Standardize Subject Preparation: Ensure all subjects adhere to a strict protocol regarding fasting, avoidance of caffeine and certain medications for a specified period before the study. [\[13\]](#)[\[20\]](#)
- Calibrate Stress Protocols: For exercise stress, ensure subjects reach their target heart rate. [\[13\]](#) For pharmacological stress, use precise dosing and infusion rates.[\[21\]](#)
- Adhere to a Strict Imaging Schedule: Maintain consistent time intervals between tracer injection and image acquisition for all studies.
- Develop a Standardized ROI Analysis Protocol: Use anatomical landmarks and a consistent methodology for drawing ROIs on the myocardial images.

Data Presentation

Table 1: Sestamibi Washout Rates in Myocardial Perfusion Imaging

Condition	Myocardial Segment	Washout Rate (%)	Reference
Coronary Spastic Angina	Spastic Segments	16 ± 2	[1]
Coronary Spastic Angina	Non-Spastic Segments	11 ± 5	[1]
Acute Myocardial Infarction (Post-PCI)	Global (LAD culprit)	61.1 ± 6.6	[2]
Acute Myocardial Infarction (Post-PCI)	Global (RCA culprit)	56.4 ± 4.5	[2]

Table 2: Sestamibi Uptake and Washout in Parathyroid vs. Thyroid Tissue

Tissue Type	Imaging Phase	Standardized Uptake Value (SUVmax)	Washout Rate (h ⁻¹)	Reference
Parathyroid Adenoma	Early	6.43 ± 3.78	0.26 ± 0.16	[23][24]
Thyroid Tissue	Early	4.43 ± 1.93	0.42 ± 0.18	[23][24]
Parathyroid Adenoma	Delayed	3.40 ± 3.09	N/A	[23][24]
Thyroid Tissue	Delayed	1.84 ± 1.05	N/A	[23][24]

Experimental Protocols

Protocol 1: Dual-Phase Parathyroid Scintigraphy

Objective: To localize hyperfunctioning parathyroid tissue based on differential washout of ^{99m}Tc-Sestamibi from parathyroid and thyroid glands.

Methodology:

- Radiopharmaceutical Administration: Administer 740–1,110 MBq (20–30 mCi) of 99mTc-Sestamibi intravenously.[5]
- Early-Phase Imaging: At 15-30 minutes post-injection, acquire planar and/or SPECT/CT images of the neck and mediastinum.[4][5]
- Delayed-Phase Imaging: At 1.5-2.5 hours post-injection, acquire a second set of planar and/or SPECT/CT images of the same regions.[4][5]
- Image Analysis: Compare the early and delayed images. A focus of persistent or increased uptake on the delayed images relative to the surrounding thyroid tissue is indicative of a parathyroid adenoma.[4]

Protocol 2: Myocardial Perfusion Imaging (One-Day Rest/Stress Protocol)

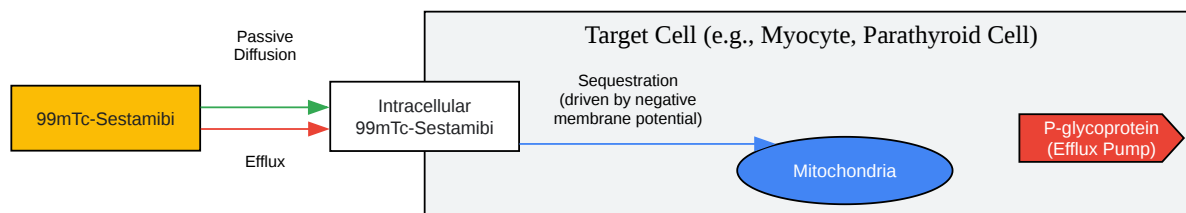
Objective: To assess myocardial perfusion and identify areas of ischemia by comparing Sestamibi uptake and washout at rest and under stress.

Methodology:

- Rest Phase:
 - Administer a low dose (e.g., 10 mCi) of 99mTc-Sestamibi intravenously at rest.[22]
 - After a waiting period of 45-60 minutes to allow for hepatobiliary clearance, acquire gated SPECT images of the heart.[25]
- Stress Phase:
 - Induce cardiac stress, either through exercise (e.g., treadmill testing following the Bruce protocol) or pharmacological agents (e.g., adenosine, dipyridamole).[13][21][25]
 - At peak stress, administer a higher dose (e.g., 30 mCi) of 99mTc-Sestamibi intravenously. [22]
 - After a waiting period of 15-60 minutes, acquire a second set of gated SPECT images.[25]

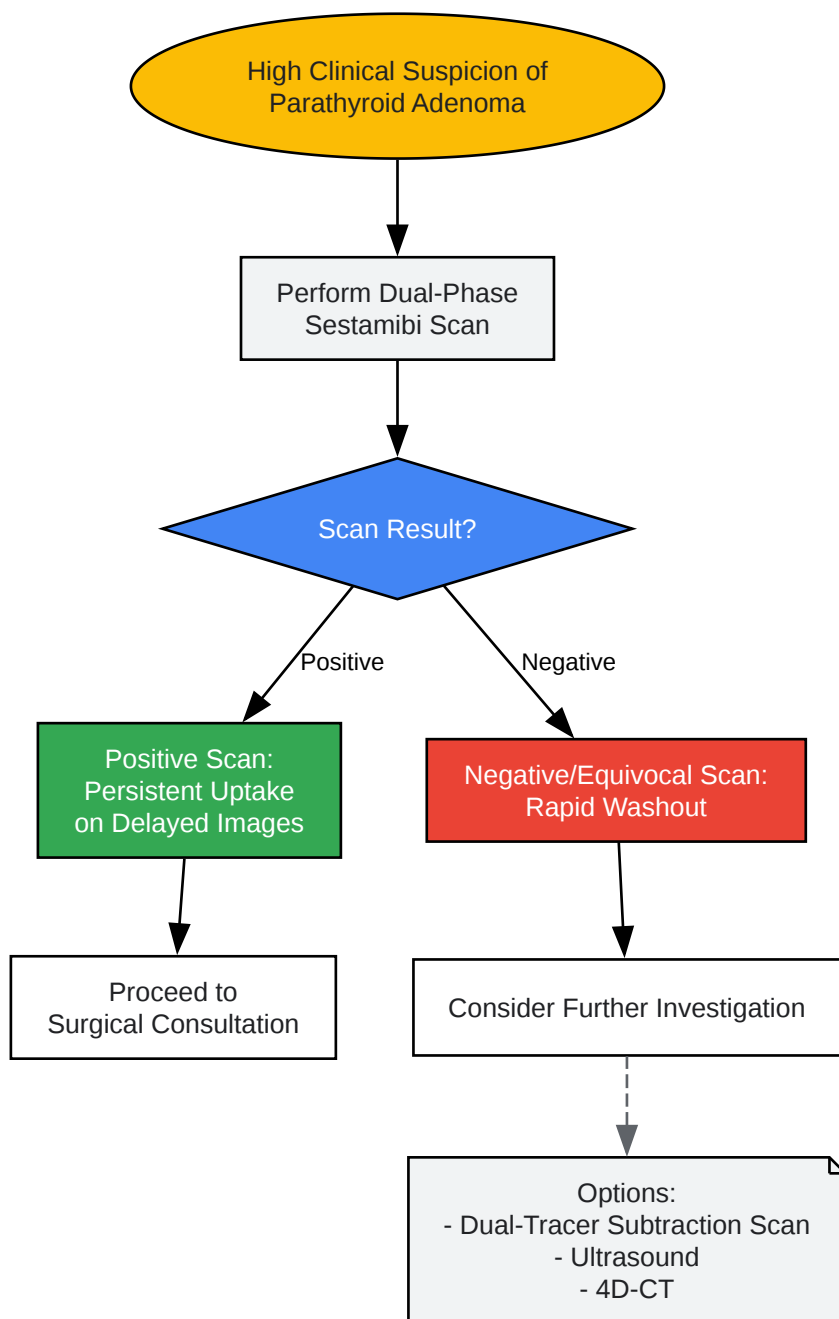
- Washout Rate Calculation:
 - Define regions of interest (ROIs) over the myocardial segments in both the rest and stress images.
 - Correct the image counts for radioactive decay between the two acquisitions.
 - Calculate the washout rate for each segment using the formula: Washout Rate (%) = $\frac{[(\text{Stress Counts} - \text{Rest Counts}) / \text{Stress Counts}] \times 100$

Visualizations



[Click to download full resolution via product page](#)

Caption: Factors influencing Sestamibi uptake and washout at the cellular level.



[Click to download full resolution via product page](#)

Need Custom Synthesis?

BenchChem offers custom synthesis for rare earth carbides and specific isotopic labeling.

Email: info@benchchem.com or [Request Quote Online](#).

References

- 1. Enhanced regional washout of technetium-99m-sestamibi in patients with coronary spastic angina - PubMed [pubmed.ncbi.nlm.nih.gov]
- 2. Significance of 99mTc-Sestamibi myocardial scintigraphy after percutaneous coronary intervention in patients with acute myocardial infarction - PMC [pmc.ncbi.nlm.nih.gov]
- 3. The diagnostic utility of dual phase Tc-99m sestamibi parathyroid imaging - PubMed [pubmed.ncbi.nlm.nih.gov]
- 4. tech.snmjournals.org [tech.snmjournals.org]
- 5. snmmi.org [snmmi.org]
- 6. radiopaedia.org [radiopaedia.org]
- 7. eanm.org [eanm.org]
- 8. P-glycoprotein expression is associated with sestamibi washout in primary hyperparathyroidism - PubMed [pubmed.ncbi.nlm.nih.gov]
- 9. researchgate.net [researchgate.net]
- 10. Technetium-99m-sestamibi parathyroid scintigraphy: effect of P-glycoprotein, histology and tumor size on detectability - PubMed [pubmed.ncbi.nlm.nih.gov]
- 11. researchgate.net [researchgate.net]
- 12. Mechanism of technetium 99m sestamibi parathyroid imaging and the possible role of p-glycoprotein - PubMed [pubmed.ncbi.nlm.nih.gov]
- 13. radiopaedia.org [radiopaedia.org]
- 14. False-negative 99mTc-sestamibi scans: factors and outcomes in primary hyperparathyroidism - PMC [pmc.ncbi.nlm.nih.gov]
- 15. Sestamibi Scan for Parathyroid Disease. Sestamibi parathyroid x-ray scan locates problem parathyroid glands and parathyroid tumors. Sestamibi is the BEST parathyroid x-ray. [parathyroid.com]
- 16. Parathyroid Sestamibi Scan Technical Page: How Parathyroid Sestamibi Scanning is Performed. This is a page for Radiologists and Nuclear Medicine Techs. [parathyroid.com]
- 17. 99mTechnetium Sestamibi-123Iodine Scintigraphy Is More Accurate Than 99mTechnetium Sestamibi Alone before Surgery for Primary Hyperparathyroidism - PMC [pmc.ncbi.nlm.nih.gov]
- 18. brieflands.com [brieflands.com]

- 19. jnm.snmjournals.org [jnm.snmjournals.org]
- 20. Sestamibi Scan - "Mibi" - St Vincent's Heart Health [svhhearthealth.com.au]
- 21. Technetium 99m SESTAMIBI myocardial perfusion imaging: comparison between treadmill, dipyridamole and trans-oesophageal atrial pacing "stress" tests in normal subjects - PubMed [pubmed.ncbi.nlm.nih.gov]
- 22. actx.edu [actx.edu]
- 23. Quantitative analysis of technetium-99m-sestamibi uptake and washout in parathyroid scintigraphy supports dual mechanisms of lesion conspicuity - PubMed [pubmed.ncbi.nlm.nih.gov]
- 24. researchgate.net [researchgate.net]
- 25. tech.snmjournals.org [tech.snmjournals.org]
- To cite this document: BenchChem. [Technical Support Center: Managing Sestamibi Washout for Accurate Diagnosis]. BenchChem, [2025]. [Online PDF]. Available at: [https://www.benchchem.com/product/b1142544#managing-sestamibi-washout-rates-for-accurate-diagnosis]

Disclaimer & Data Validity:

The information provided in this document is for Research Use Only (RUO) and is strictly not intended for diagnostic or therapeutic procedures. While BenchChem strives to provide accurate protocols, we make no warranties, express or implied, regarding the fitness of this product for every specific experimental setup.

Technical Support: The protocols provided are for reference purposes. Unsure if this reagent suits your experiment? [[Contact our Ph.D. Support Team for a compatibility check](#)]

Need Industrial/Bulk Grade? [Request Custom Synthesis Quote](#)

BenchChem

Our mission is to be the trusted global source of essential and advanced chemicals, empowering scientists and researchers to drive progress in science and industry.

Contact

Address: 3281 E Guasti Rd

Ontario, CA 91761, United States

Phone: (601) 213-4426

Email: info@benchchem.com