

Technical Support Center: Managing Complications in Bilateral Sagittal Split Osteotomy (BSSO)

Author: BenchChem Technical Support Team. **Date:** December 2025

Compound of Interest

Compound Name: BSSO

Cat. No.: B1252915

[Get Quote](#)

This technical support center provides troubleshooting guides and frequently asked questions (FAQs) to assist researchers, scientists, and drug development professionals in managing "bad splits" during bilateral sagittal split osteotomy (BSSO) procedures.

Frequently Asked Questions (FAQs)

Q1: What is a "bad split" in the context of **BSSO**?

A "bad split," also referred to as an unfavorable or irregular fracture, is an undesirable fracture pattern of the mandible that occurs during the osteotomy procedure.^{[1][2]} These fractures can deviate from the intended osteotomy lines and may involve various parts of the mandible, including the buccal or lingual plates, the condylar neck, or the coronoid process.^{[3][4]}

Q2: How common are "bad splits" during **BSSO**?

The reported incidence of bad splits varies widely in the literature, ranging from 0.21% to 22.72%.^{[1][5][6]} A systematic review of 33 studies reported a total incidence of 2.3% per sagittal split.^[7] The variability in incidence can be attributed to factors such as surgical technique, patient anatomy, and the presence of third molars.^{[4][8]}

Q3: What are the primary risk factors for a "bad split"?

Several factors are thought to increase the risk of a bad split, although some are still debated in the literature.[8] Potential risk factors include:

- Patient Age: Some studies suggest a weak correlation between increasing age and a higher incidence of bad splits.[3][8]
- Presence of Third Molars: The role of impacted third molars is controversial.[3][8] Some surgeons recommend their removal at least six months prior to **BSSO** to allow for bone healing.[9][10]
- Mandibular Morphology: A thin mandibular ramus or a high lingula position can increase the risk.[3][4]
- Surgical Technique: Inadequate osteotomy design, incomplete cuts, and the use of excessive force during the split are significant contributing factors.[6][9] Different modifications of the **BSSO** technique have been developed to reduce the risk of complications.[1][4]

Q4: What are the potential consequences of a "bad split"?

If not managed properly, a bad split can lead to several intraoperative and postoperative complications, including:

- Mechanical instability of the bone segments[11]
- Delayed bone healing or non-union[1][2]
- Infection and bone sequestration[2][11]
- Temporomandibular joint (TMJ) dysfunction[11]
- Injury to the inferior alveolar nerve[11]
- Postoperative malocclusion[3]

Troubleshooting Guide

This guide addresses specific issues that may be encountered during a **BSSO** procedure.

Issue 1: A fracture occurs in the buccal plate of the proximal segment.

- Why is this happening? This is one of the most common types of bad splits.^[7] It can result from incomplete osteotomy cuts, particularly at the inferior border of the mandible, leading the fracture line to propagate buccally.^[10]
- How to manage it:
 - Assess the Fracture: Determine the size and stability of the fractured buccal plate.
 - Complete the Osteotomy: If the split is incomplete, carefully complete the osteotomy to separate the proximal and distal segments.^[9]
 - Stabilize the Fragment: The fractured buccal plate should be repositioned and stabilized. This is typically achieved using miniplates and/or bicortical or monocortical screws to fix the fragment to the proximal segment.^{[1][3][12]}
 - Proceed with Fixation: Once the bad split is managed, proceed with the planned fixation of the proximal and distal segments.

Issue 2: The fracture extends superiorly towards the condylar neck.

- Why is this happening? A high horizontal osteotomy cut, a high lingula position, or incomplete cuts in the ascending ramus area can predispose to a fracture extending towards the condyle.^[3]
- How to manage it:
 - Immediate Action: If this occurs, the surgeon must decide whether to proceed with the surgery or abort the procedure on that side.^[9]
 - If Proceeding: The primary goal is to stabilize the condylar segment. This may involve:
 - Careful dissection to expose the fracture.^[13]
 - Reduction of the fracture and fixation with miniplates and screws.^[3]

- Maxillomandibular fixation (MMF) may be necessary to ensure stability during healing.

[1]

- Alternative: In some cases, converting to an intraoral vertical ramus osteotomy (IVRO) on the affected side might be an option.[9]

Issue 3: A fracture occurs in the lingual plate of the distal segment.

- Why is this happening? This type of fracture can occur due to improper placement of osteotomes or excessive force during the splitting maneuver.
- How to manage it:
 - Preserve Blood Supply: It is crucial to maintain the soft tissue attachments to the fractured lingual segment to ensure its vascularity.
 - Incorporate into Fixation: The fractured segment should be repositioned and included in the fixation scheme when stabilizing the distal segment.[6] Additional miniplates or screws may be required to secure the fragment.

Data Presentation

Table 1: Incidence of "Bad Splits" in Bilateral Sagittal Split Osteotomy

Study/Review	Number of Patients/Splits	Incidence of Bad Splits
Chrcanovic et al. (Systematic Review)[1]	21 studies (1971-2010)	0.21% to 22.72%
Steenen et al. (Systematic Review)[7]	10,271 patients/19,527 splits	2.3% per split
Falter et al.[4]	2,005 BSSO sites	0.7% (14 sites)
Jiang et al.[4]	484 individuals	4.15% (40 cases)
Friscia et al.[1]	423 cases	1.89% (8 patients)
Kim and Park[1]	234 participants	3.85% (9 cases)
Veras et al.[1]	110 participants	10.91% (12 cases)

Experimental Protocols

Protocol 1: Prevention of Bad Splits using Inferior Border Osteotomy

This protocol describes a modification to the standard **BSSO** to minimize the risk of unfavorable fractures.

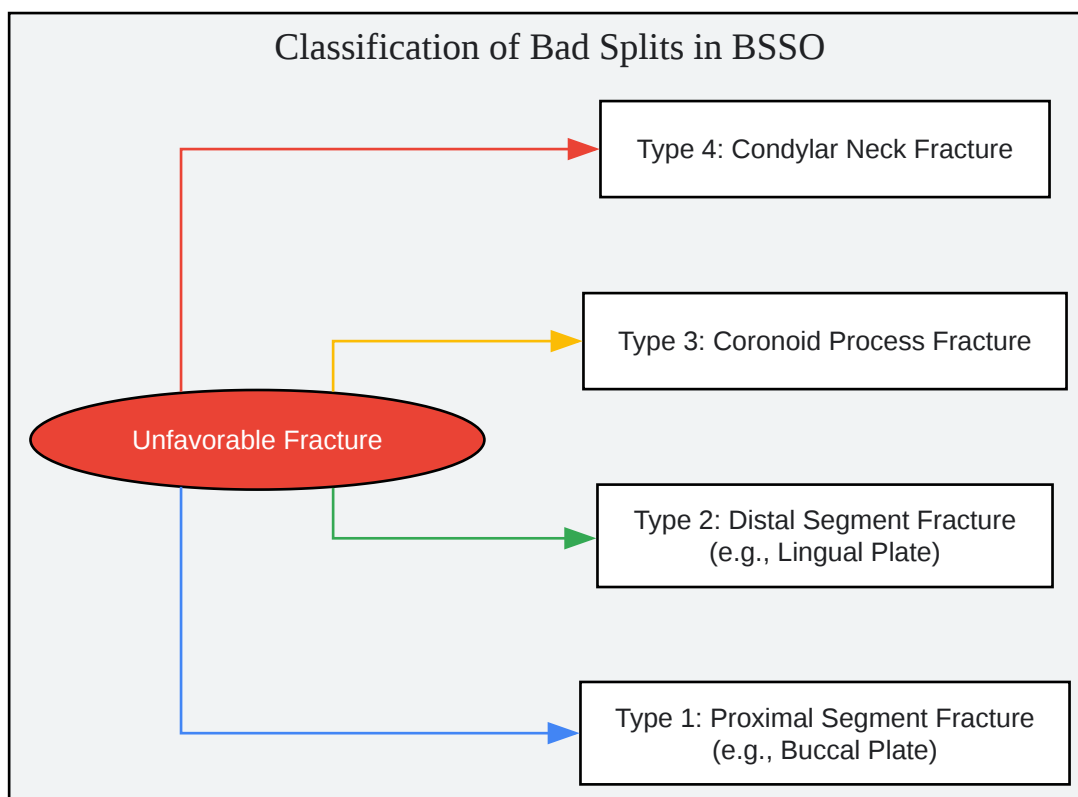
- **Standard Osteotomy Cuts:** Perform the standard medial horizontal, vertical, and sagittal osteotomy cuts of the mandibular ramus.
- **Inferior Border Cut:** After the initial cuts, use a fine burr or piezoelectric instrument to create a fourth osteotomy cut along the inferior border of the mandible, connecting the anterior end of the sagittal cut to the posterior border. This cut should perforate the buccal cortex and extend into the cancellous bone.[\[14\]](#)
- **Splitting:** Use spreaders or osteotomes to apply gentle, controlled force to initiate and complete the split. The inferior border cut helps to guide the fracture along a more predictable path.[\[14\]](#)
- **Protection of the IAN:** Insert a malleable retractor into the bone gap to protect the inferior alveolar nerve during the final separation of the segments.[\[14\]](#)

Protocol 2: Management of an Intraoperative Buccal Plate Fracture

- **Identification:** Immediately upon recognizing the fracture, stop the splitting procedure.
- **Fragment Preservation:** Carefully preserve the fractured buccal plate, maintaining its periosteal attachment if possible to ensure blood supply.
- **Completion of Split:** Gently complete the sagittal split to mobilize the distal, tooth-bearing segment.
- **Fragment Reduction:** Reposition the fractured buccal plate back to its anatomical position against the proximal segment.
- **Fixation:** Secure the fractured fragment to the proximal segment using one or two miniplates with monocortical screws. Alternatively, bicortical screws can be used.[\[3\]](#)[\[12\]](#)

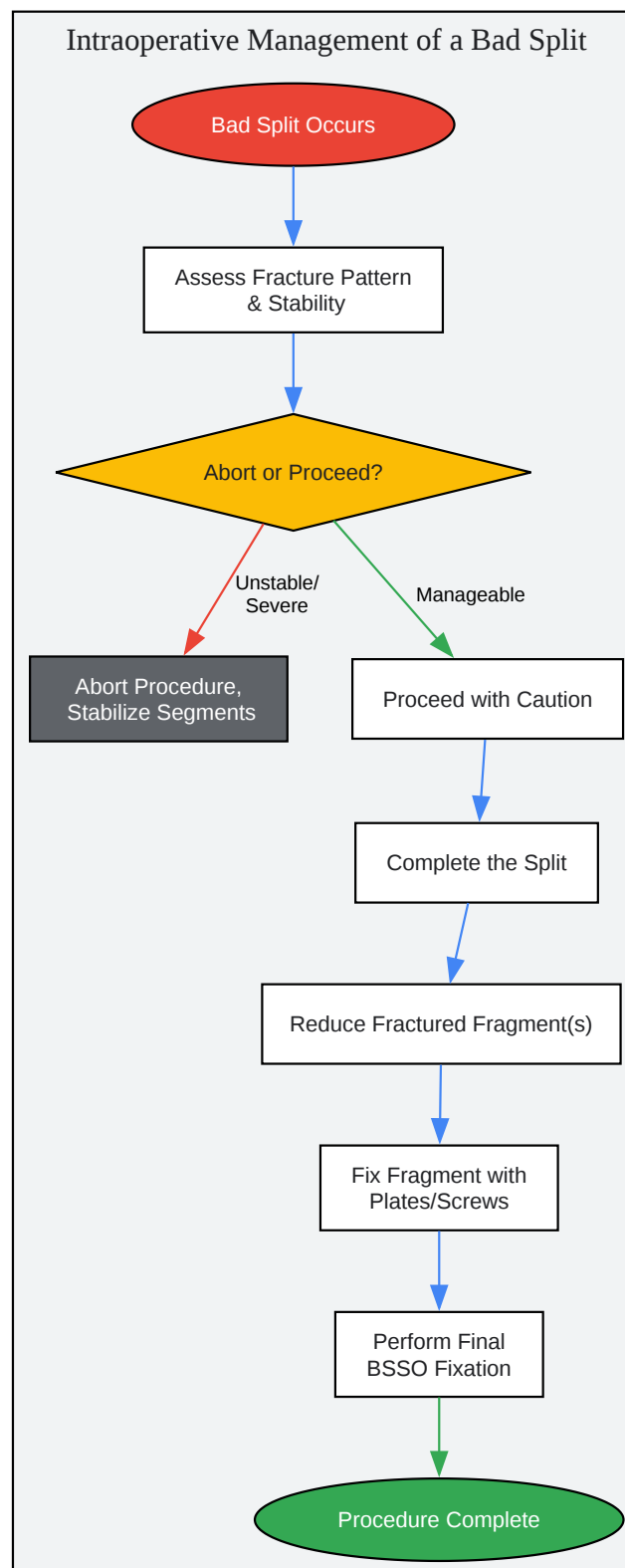
- Final Fixation: Proceed with the planned rigid fixation of the advanced or repositioned mandible.

Mandatory Visualizations



[Click to download full resolution via product page](#)

Caption: Classification of "bad splits" based on anatomical location.



[Click to download full resolution via product page](#)

Caption: Decision-making workflow for managing a "bad split".

Need Custom Synthesis?

BenchChem offers custom synthesis for rare earth carbides and specific isotopic labeling.

Email: info@benchchem.com or [Request Quote Online](#).

References

- 1. Management of A Bad Split Complication: A Systematic Review [opendentistryjournal.com]
- 2. opendentistryjournal.com [opendentistryjournal.com]
- 3. dergipark.org.tr [dergipark.org.tr]
- 4. Unfavorable fractures in bilateral sagittal split osteotomy: a systematic review of classification and management strategies [termedia.pl]
- 5. researchgate.net [researchgate.net]
- 6. Risk factors and prevention of bad splits during sagittal split osteotomy - PubMed [pubmed.ncbi.nlm.nih.gov]
- 7. Bad splits in bilateral sagittal split osteotomy: systematic review of fracture patterns - PubMed [pubmed.ncbi.nlm.nih.gov]
- 8. Bad splits in bilateral sagittal split osteotomy: systematic review and meta-analysis of reported risk factors | Pocket Dentistry [pocketdentistry.com]
- 9. Complications in Orthognathic Surgery | Plastic Surgery Key [plasticsurgerykey.com]
- 10. Bilateral Sagittal Split Osteotomy - PMC [pmc.ncbi.nlm.nih.gov]
- 11. Bad splits in bilateral sagittal split osteotomy: systematic review of fracture patterns | Pocket Dentistry [pocketdentistry.com]
- 12. Management of A Bad Split Complication: A Systematic Review [opendentistryjournal.com]
- 13. Journal Club Bad splits in bilateral sagittal split osteotomy: systematic review of fracture patterns | PPTX [slideshare.net]
- 14. Simple inferior border osteotomy to prevent bad split during bilateral sagittal split osteotomy - PMC [pmc.ncbi.nlm.nih.gov]
- To cite this document: BenchChem. [Technical Support Center: Managing Complications in Bilateral Sagittal Split Osteotomy (BSSO)]. BenchChem, [2025]. [Online PDF]. Available at: [https://www.benchchem.com/product/b1252915#managing-bad-splits-during-bilateral-sagittal-split-osteotomy]

Disclaimer & Data Validity:

The information provided in this document is for Research Use Only (RUO) and is strictly not intended for diagnostic or therapeutic procedures. While BenchChem strives to provide accurate protocols, we make no warranties, express or implied, regarding the fitness of this product for every specific experimental setup.

Technical Support: The protocols provided are for reference purposes. Unsure if this reagent suits your experiment? [[Contact our Ph.D. Support Team for a compatibility check](#)]

Need Industrial/Bulk Grade? [Request Custom Synthesis Quote](#)

BenchChem

Our mission is to be the trusted global source of essential and advanced chemicals, empowering scientists and researchers to drive progress in science and industry.

Contact

Address: 3281 E Guasti Rd
Ontario, CA 91761, United States
Phone: (601) 213-4426
Email: info@benchchem.com